



## Case Report

# Could acute angle closure glaucoma be an indicator of something more ominous?

Neetha I R Kuzhuppilly<sup>1,\*</sup>, Yashaswinee V S<sup>1</sup>, Shailaja Shenoy<sup>1</sup>, Sudha Menon<sup>1</sup>, Piyush Chandak<sup>2</sup>

<sup>1</sup>Dept. of Ophthalmology, Kasturba Medical College, Manipal, Manipal Academy of Higher Education, Manipal, Karnataka, India

<sup>2</sup>Chandak Eye Hospital, Jalgaon, Maharashtra, India



### ARTICLE INFO

#### Article history:

Received 19-04-2020

Accepted 18-05-2020

Available online 30-06-2020

#### Keywords:

Angle closure glaucoma

Choroidal melanoma

Iridotomy

Metastasis

### ABSTRACT

Choroidal melanoma is the most common intraocular tumor in adults, but is rare in Asia. Patients can present with diminished vision, floaters or visual field loss but most often, tumors are detected incidentally on routine examination. We report a case of a 71 year old female who presented to us with decreased vision and pain in the right eye, who was diagnosed with acute angle closure glaucoma and was treated for the same. On further evaluation, she was found to have choroidal melanoma. This highlights the need for complete evaluation of a successfully treated acute angle closure crisis case.

© 2020 Published by Innovative Publication. This is an open access article under the CC BY-NC license (<https://creativecommons.org/licenses/by-nc/4.0/>)

## 1. Introduction

Choroidal melanoma is the predominant primary intraocular malignant tumor and is the second most common site of malignant melanomas in the body.<sup>1,2</sup> Uveal melanoma has an incidence of 5.1 cases per million, with choroidal melanoma representing 90% of all cases.<sup>3</sup>

Choroidal melanomas are usually found incidentally on slit-lamp examination and funduscopy. A quarter of them are asymptomatic and others may present with symptoms of flashes, floaters or diminution of vision.<sup>4</sup> It appears as a sessile, dome-shaped, or mushroom-shaped, pigmented mass, located deep to the sensory retina, often associated with subretinal fluid and exudative retinal detachment. Over time, the tumor grows anteriorly and the chief complaint on presentation can be pain due to glaucoma which may masquerade the underlying condition. With this case report, we would like to highlight the importance of detailed evaluation in cases presenting as acute angle closure glaucoma.

\* Corresponding author.

E-mail address: [cinnineetha@gmail.com](mailto:cinnineetha@gmail.com) (N. I. R. Kuzhuppilly).

## 2. Case Report

A 71-year-old lady presented to us with a history of gradual onset of diminution of vision in the right eye since 1 year and sudden onset pain from 2 days.

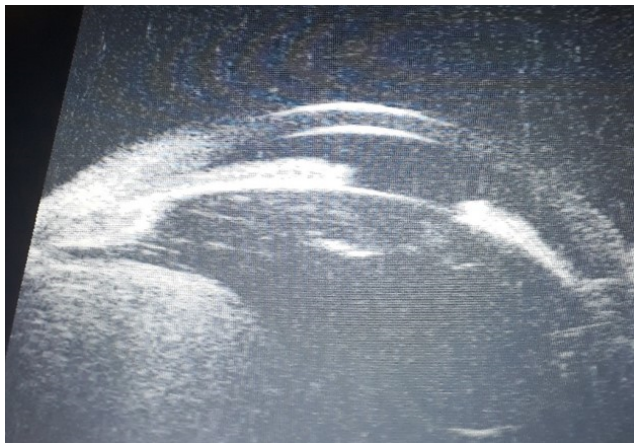On examination, her visual acuity in right eye was perception of light with inaccurate projection of rays and in the left eye was 3/60. Slit lamp evaluation of the right-eye revealed acute angle closure crisis with ciliary congestion, corneal epithelial edema, shallow anterior chamber, 4mm pupil and an intra-ocular pressure (IOP) of 60mmHg. On gonioscopy, 360 degree angle closure was observed. Examination of the left eye showed a shallow anterior chamber, but trabecular meshwork was visible on gonioscopy. The left eye was normal otherwise and IOP was 18mmHg.

Emergency measures in the form of oral glycerol, oral acetazolamide, topical timolol and brimonidine were started and Nd YAG laser iridotomy was done in the right eye following which intraocular pressure reduced and cornea cleared. Blood was noted behind the lens and yellow fundus glow was seen.

Further evaluation revealed dome shaped retro lenticular mass originating supero-temporally and obscuring view of the rest of the posterior segment. On further investigation by UBM and B scan, the presence of retro lenticular mass in the supero-temporal quadrant was confirmed, which caused anterior displacement of the iris lens diaphragm leading to secondary angle closure. (Fig.1 and Fig.2) MRI revealed the mass to be of choroidal origin limited to the posterior segment arising from superotemporal part of choroid suggestive of choroidal melanoma (Fig.3). CT abdomen followed by fine needle aspiration cytology of lesions in the liver confirmed metastatic melanoma.

The patient was lost to follow up for a month as she was pain free, but presented again with severe pain in the right eye. She underwent enucleation of her right eye. Histopathological examination showed spindly cells with eosinophilic cytoplasm and dense dark brown melanin pigments masking the nucleus. Few cells showed round to oval nucleus with prominent nucleoli. The tumor cells were seen infiltrating the underlying sclera with extrascleral infiltration in the superotemporal quadrant near the optic nerve (Fig. 4). Optic nerve showed no tumor infiltration. Sections studied from the vortex veins showed no tumor emboli.

She chose not to undergo any further treatment for the metastasis.

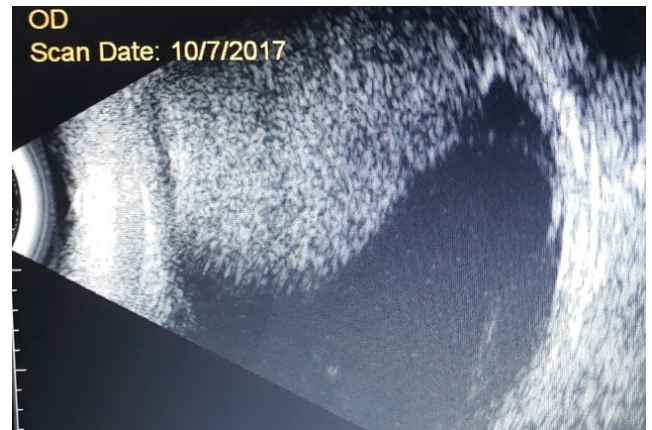


**Fig. 1:** Ultrasound biomicroscopy (UBM) showing a dome-shaped retro-lenticular mass with anterior displacement of the lens and angle closure.

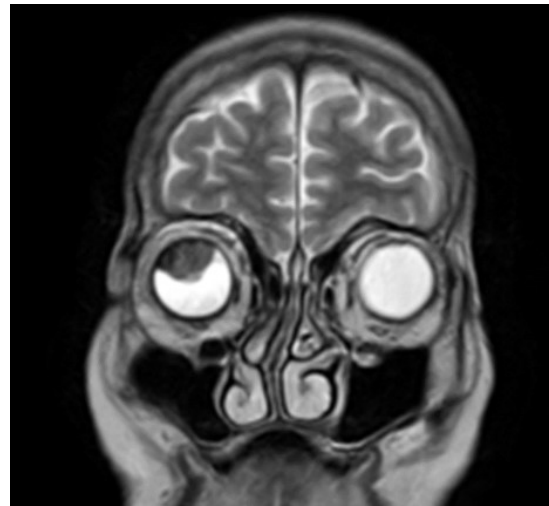### 3. Discussion

The above case is of a 71 year old Indian female who presented with symptoms of acute angle closure crisis and following emergency management was diagnosed to have choroidal melanoma.

Choroidal melanomas are the most common type of primary intraocular tumor in adults, but they are still rare with only 6–8 cases per million population.<sup>1,5</sup> It is

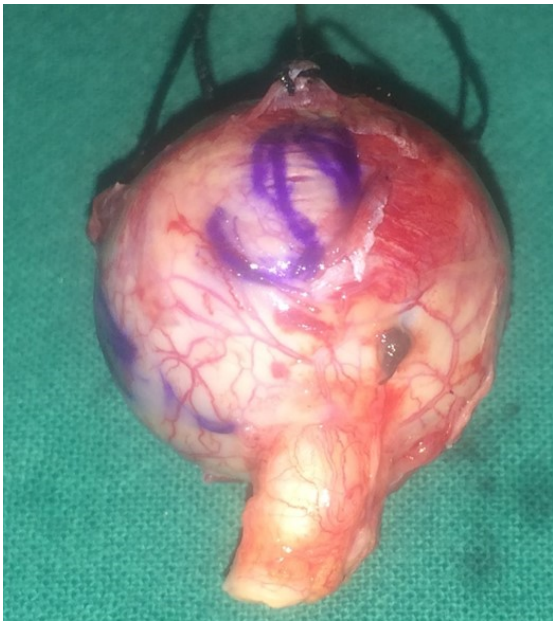


**Fig. 2:** Bscan showing a dome-shaped retro-lenticular superotemporal hyperechoic lesion protruding into the anechoic vitreous, suggestive of choroidal melanoma.



**Fig. 3:** MRI axial view of skull showing well-defined lobulated altered signal intensity intraocular lesion measuring 1.5x1.7x1.3cm, which is predominantly hyperintense on T1 and mixed signal intensity on T2, and showing post contrast heterogeneous enhancement, noted in the superotemporal side of the right eye, limited to the posterior chamber, associated with exudative retinal detachment, hemorrhagic subretinal fluid and vitreous hemorrhage, all features suggestive of choroidal melanoma.

commonly found in Caucasian females in the age group of 50-60 years. In contrast, our patient was a 71 year old Indian lady.<sup>5</sup> Secondary elevation of intraocular pressure (IOP) occurs in 5% of intra ocular tumors and in 2% of choroidal melanomas.<sup>6</sup> Tumors of the posterior segment are more likely to cause glaucoma.<sup>3,6</sup> The secondary glaucoma has been reported to be due to various mechanisms like angle invasion of tumor cells, angle closure by mass effect on the iris, iris neovascularization, hyphema and supra choroidal hemorrhage.<sup>3,7,8</sup>



**Fig. 4:** Enucleated right eye showing extra scleral extension in the superotemporal quadrant.

Our patient had a retro lenticular mass in the superotemporal part which was the cause of secondary angle closure by pupillary block mechanism. This was inferred because the IOP lowered following iridotomy and the patient was symptom free for a month. This pupillary block occurred secondary to the anterior displacement of the iris lens diaphragm. There are reports of inflammation caused by necrotic tumors causing posterior synechiae, which can exacerbate angle closure through a pupillary block mechanism, but our patient did not develop posterior synechiae or seclusio pupillae.<sup>8</sup> The recurrence of pain in a month could have been due to further growth of the tumor and additional mass effect closing the iridocorneal angle or due to tumor infarction.<sup>9</sup>

This presentation of melanoma as acute angle closure crisis with pupillary block is not common. Acute angle closure crisis is an emergency situation and with the other eye also having a shallow anterior chamber, it is very easy to overlook the presence of secondary causes that are potentially life threatening.

Schwartz described a case of pupillary block angle closure crisis who underwent iridotomy and on subsequent fundus evaluation choroidal melanoma was detected.<sup>10</sup> Escalona Benz et al reported two cases, one with secondary glaucoma due to angle invasion by tumor cells, and the other due to angle closure by mass effect, both caused by choroidal melanoma, diagnosed by histology after enucleation.<sup>11</sup> The first case was treated with iridotomy and the melanoma was detected few weeks later when suspicion arose due to continued rise in IOP. The second case was posted for enucleation as

the melanoma was detected on B-scan. Another similar case was reported by Tan where the IOP continued to be high after peripheral iridotomy and ultrasonography revealed choroidal melanoma.<sup>5</sup> In scenarios where the IOP doesn't reduce following iridotomy, Radcliffe cautions us to consider other causes of angle closure.<sup>8</sup>

There are multiple such reports in literature highlighting the need for complete ocular examination following treatment of a case that presents as angle closure crisis. Especially in those cases where the IOP is successfully lowered with iridotomy, a good follow up evaluation including gonioscopy and fundus evaluation is a must.

Choroidal melanoma management includes radiotherapy, local resection or enucleation especially for unresolving cases.<sup>3</sup> Survival depends upon early diagnosis and younger age of the patient, both of which were not so in this case. Unfortunately our patient had liver metastasis at presentation, which is the most common site of metastasis of choroidal melanoma.<sup>1</sup> Metastasis at presentation may be seen in up to 40% of cases and median survival in the presence of metastasis is 2 to 7 months.<sup>12,13</sup> The patient chose not to undergo any further intervention.

#### 4. Conclusion

It is important to assess the posterior segment in the follow up of a case of acute angle closure crisis that has responded well to iridotomy, to avoid missing potentially life threatening secondary causes of angle closure like intra ocular tumors.

#### 5. Source of Funding

None.

#### 6. Conflict of Interest

None.

#### References

1. Khetan V, Pal B, Garge S. Choroidal melanoma: A short review with an Indian perspective. *Oman J Ophthalmol.* 2017;10(3):135–44.
2. Singh P, Singh A, Choroidal, Oman, Ophthalmol. Choroidal melanoma. *Oman J Ophthalmol.* 2012;5(1):3–9.
3. Camp DA, Yadav P, Dalvin LA, Shields CL. Glaucoma secondary to intraocular tumors. *Curr Opin Ophthalmol.* 2019;30(2):71–81.
4. Shields CL, Kels JG, Shields JA. Melanoma of the eye: Revealing hidden secrets, one at a time. *Clin Dermatol.* 2015;33(2):183–96.
5. Tan SZ, Sampat K, Rasool S, Nolan D. Unilateral acute angle closure glaucoma. *BMJ Case Rep.* 2013;.
6. Shields CL, Shields JA, Shields MB, Augsburger JJ. Prevalence and Mechanisms of Secondary Intraocular Pressure Elevation in Eyes with Intraocular Tumors. *Ophthalmol.* 1987;94(7):839–46.
7. Nicoletti AGB, Costa DS, Ghanem RC, Carricondo PC, Santo RM, Matayoshi S, et al. Atypical choroidal melanoma: report of 3 cases. *Clin.* 2006;61(1):79–82.
8. Radcliffe NM, Finger PT. Eye Cancer Related Glaucoma: Current Concepts. *Surv Ophthalmol.* 2009;54(1):47–73.
9. Rishi P, Shields CL, Khan MA, Patrick K, Shields JA. Headache or Eye Pain as the Presenting Feature of Uveal Melanoma. *Ophthalmol.*

- 2013;120(9):1946–7.
10. Schwartz GP, Schwartz LW. Acute angle closure glaucoma secondary to a choroidal melanoma. *CLAO J Internet*. 2002;28(2):77–9.
  11. Escalona-Benz E, Benz MS, Briggs JW, Budenz DL, Parrish RK, Murray TG, et al. Uveal melanoma presenting as acute angle-closure glaucoma: report of two cases. *Am J Ophthalmol*. 2003;136(4):756–8.
  12. Feldman ED, Pingpank JF, Alexander HR. Regional Treatment Options for Patients With Ocular Melanoma Metastatic to the Liver. *Ann Surg Oncol*. 2004;11(3):290–7.
  13. Soni S, Lee DS, DiVito J, Bui AH, DeRaffele G, Radel E, et al. Treatment of Pediatric Ocular Melanoma With High-Dose Interleukin-2 and Thalidomide. *J Pediatr Hematol Oncol*. 2002;24(6):488–91.

### Author biography

**Neetha I R Kuzhuppilly** Assistant Professor

**Yashaswinee V S** Student

**Shailaja Shenoy** Associate Professor

**Sudha Menon** Assistant Professor

**Piyush Chandak** Consultant

**Cite this article:** Kuzhuppilly NIR, Yashaswinee V S , Shenoy S, Menon S, Chandak P. **Could acute angle closure glaucoma be an indicator of something more ominous?.** *IP Int J Ocul Oncol Oculoplasty* 2020;6(2):145-148.