



## Original Research Article

## An analysis of clinical presentations and etiology of optic disc oedema

Isha K. Patel<sup>1,\*</sup>, Trupti M Solu<sup>1</sup>, Yash R. Gandhi<sup>1</sup>, Shivranjani S. Balraj<sup>1</sup><sup>1</sup>Dept. of Ophthalmology, Government Medical College, Surat, Gujarat, India

## ARTICLE INFO

## Article history:

Received 10-03-2020

Accepted 23-03-2020

Available online 24-04-2020

## Keywords:

Optic disc swelling

Papilloedema

Optic neuritis

Dimness of vision

Headache.

## ABSTRACT

**Introduction:** This study was performed to evaluate the various etiologies and clinical presentations in patients of optic disc oedema.

**Materials and Methods :** This study was a cross sectional observational study which was carried out at Government Medical College Surat, a tertiary care center of South Gujarat, during the period from December 2018 to January 2020. A detailed history was taken to determine the presenting symptoms for the disease. Detailed and thorough ocular examination was performed to each and every patient included in the study which comprised of Acuity of vision, Color Vision, reaction of pupil, Examination on slit lamp, Examination of fundus with Indirect Ophthalmoscopy and 78D lens with Fundus photography. Blood investigations, OCT, Visual field testing and MRI was performed when required.

**Results :** 50 consecutive cases of optic disc oedema presented at tertiary care center were included in this study. Amongst them 29 were male and 21 females. Amongst this 50 patients 23 patients had optic neuritis, 10 patients had papilloedema, 4 patients had grade 4 hypertensive retinopathy, 3 patients had anterior ischemic optic neuropathy (AION), 3 patients had neuroretinitis, 2 patients had diabetic papillopathy, 2 patients had central retinal vein occlusion, 2 patients had traumatic optic neuropathy and 1 patient had Vogt Koyanagi Harada syndrome. On evaluation it was found that 46% patients had optic neuritis, 20% patients had papilloedema, 8% patients had grade 4 hypertensive retinopathy, 6% patients had anterior ischemic optic neuropathy (AION), 6% patients had neuroretinitis, 4% patients had diabetic papillopathy, 4% patients had central retinal vein occlusion, 4% patients had traumatic optic neuropathy and 2% patient had Vogt Koyanagi Harada syndrome. Patients presented to us with most common complaint of dimness of vision (62%) followed by headache (36%), eye ache (26%), floaters (4%) and bilateral diplopia (2%).

**Conclusion :** In this study, Optic neuritis was the most common etiology and dimness of vision was the most common presenting symptom in cases of optic disc swelling.

© 2020 Published by Innovative Publication. This is an open access article under the CC BY-NC-ND license (<https://creativecommons.org/licenses/by/4.0/>)

## 1. Introduction

Various etiological factors have been described for optic disc swelling that range from infective to neoplastic. Early diagnosis and treatment are essential to save patient's vision and in some cases patients life too. The literature search showed very few studies in India to determine the causes of optic disc swelling. In this study, we aimed to determine the common causes and clinical presentations of optic disc swelling in South Gujarat, the western part of India. Unilateral optic disc swelling can be encountered in

cases associated with Optic neuritis, Non Arteritic Anterior Ischemic Optic neuropathy, compressive Optic Neuropathy, Retinal vein occlusion and Diabetic papillopathy. Bilateral optic disc swelling is often associated with papilloedema infiltrative optic neuropathy, toxic optic neuropathy and malignant hypertension.<sup>1</sup>

## 2. Materials and Methods

This cross sectional observational study was conducted at the department of Ophthalmology in a Tertiary care center in South Gujarat region of India from December 2018 to January 2020. The study population was comprised of 50

\* Corresponding author.

E-mail address: ishapateldr@gmail.com (I. K. Patel).

consecutive cases of optic disc swelling that were diagnosed at Department of Ophthalmology during the study period irrespective of sex, above 18 years of age. Amongst them 29 were male and 21 were female. Detailed and thorough ocular examination was performed to each and every patient included in the study which comprised of Acuity of vision, Color Vision, reaction of pupil, Examination on slit lamp, Examination of fundus with Indirect Ophthalmoscopy and 78D lens with Fundus photography. Blood investigations, OCT, Visual field testing and MRI was performed when required.

Papilloedema was diagnosed when there is an elevated intra cranial tension along with optic disc edema which was considered diagnostic criteria in our study. Optic neuritis was defined according to the criteria of Optic neuritis treatment trial (ONTT).<sup>2</sup> Patients presented with Anterior Ischemic Optic Neuropathy were enrolled according to the criteria of Ischemic Optic Neuropathy Decompression Trial (IONDT).<sup>3</sup> Diabetic papillopathy patients were enrolled when patients had optic disc swelling without raised Intra-cranial tension or any ocular inflammatory conditions with considerable optic nerve function. For papilloedema associated with other systemic ailments, disease specific diagnostic tests and clinical examinations were used.

### 3. Results

69 eyes of 50 patients of optic disc swelling were examined in this study which included 29 male patients and 21 female patients.

This study included most patients within the age group of 18years to 77 years. Maximum patients were between age group of 28 to 57 years (See Tables 1 and 2). In this study 23 patients with disc oedema had Optic neuritis which was found to be the most common etiology. Other etiologies were papilloedema(n=10), hypertensive retinopathy (n=4), Acute ischaemic optic neuropathy (n=3), Neuroretinitis (n=3), Diabetic Papillopathy (n=2), Traumatic Optic Neuropathy (n=2), CRVO (n=2), Vogt Koyanagi Harada Syndrome(n=1). (Table 3).

Clinical presentations of bilateral optic disc oedema included 19 patients. Etiologies of bilateral optic disc oedema were papilloedema (10 patients) followed by optic neuritis with 4 patients, hypertensive retinopathy with 4 patients and VKH syndrome with 1 patient. From the 10 cases of papilloedema, meningitis was present in 6 patients followed by intracerebral hemorrhage in 2 patients, empty sella syndrome in 1 patient and subarachnoid hemorrhage in 1 patient.

Diminution of vision was the most common clinical presentation followed by headache, floaters, diplopia or double vision and eye ache respectively (Table 4). Headache, which was seen in 18 (36%) patients was the most common presenting symptom in patients of papilloedema. The patients diagnosed as optic neuritis, CRVO, neuroretinitis,

diabetic papillopathy, anterior ischaemic optic neuropathy presented with diminution of vision as a prime clinical feature (n=31, 62%). optic Ocular pain was more common in optic neuritis patients and seen in 13 (26%) patients while 2 (4%) patients of neuroretinitis had complaint of floaters.

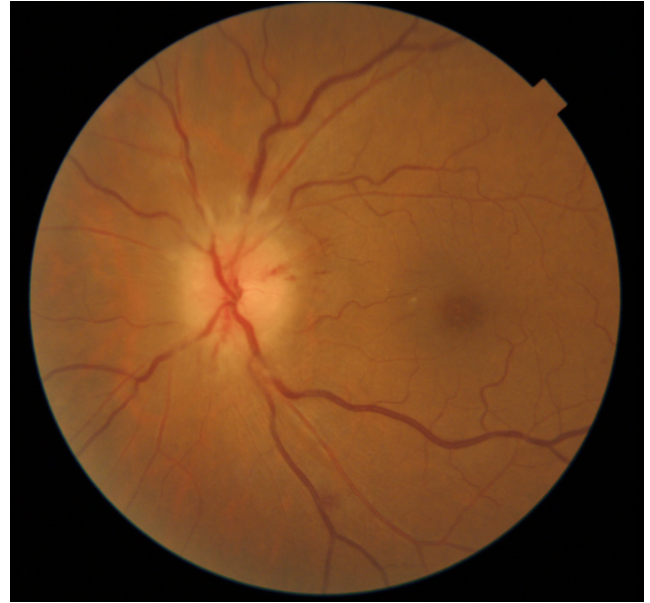


Fig. 1: aion

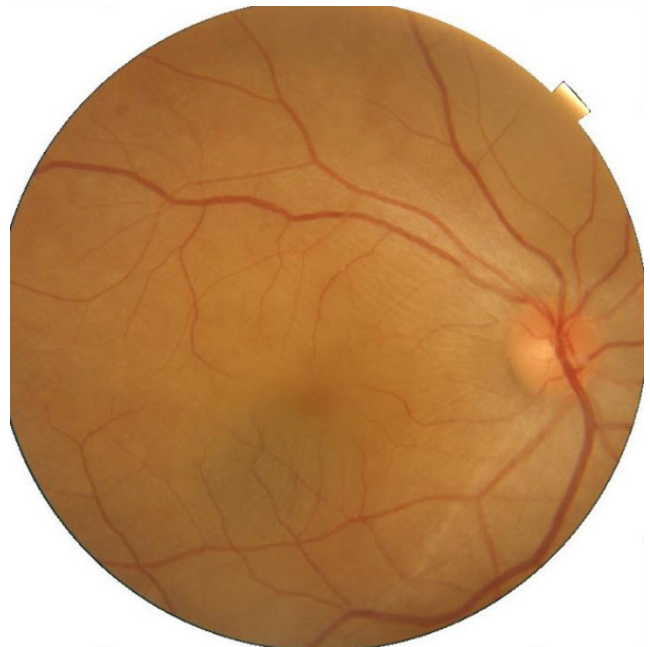

Fig. 2: VKH syndrome

**Table 1:**

Age (Years)	Patients
18-27	7
28-37	13
38-47	10
48-57	12
58-67	6
68-77	2

**Table 2:**

Male	Female
29	21

**Table 3:**

Disease	No. of Patients
Optic Neuritis	23
Papilloedema	10
Grade 4 Hypertensive retinopathy	4
Neuroretinitis	3
Anterior Ischemic Optic Neuropathy	3
Central Retinal Vain Obstruction	2
Diabetic papillopathy	2
Traumatic Optic Neuropathy	2
Vogt Koyanagi Harada Syndrome	1

**Table 4:**

Symptoms	No. of patients
Dimness of vision	31
Headache	18
Eyeache	13
Diplopia	1
Floater	2

#### 4. Discussion

Even though there have been multiple International studies which have been carried out on causes of Optic disc edema, in India there have been very few relevant studies regarding this. We aimed to find the clinical presentations and etiologies of Optic Disc Oedema at tertiary care centre in South Gujarat region of India. Our study has excluded old cases with optic atrophy and paediatric age group patients which becomes the limitation of this study. Strength of this study is that this study is one of the few cross-sectional observational studies performed in India on Etiologies and clinical presentations of Optic disc oedema.

Optic nerve compression and dysfunction resulting from long and tedious list of insults may lead to a partial arrest of axoplasmic transport which ultimately results in Optic disc oedema.<sup>4</sup>

The factors that can cause increase in the intracranial tension may result in optic disc oedema because the sub arachnoid space of brain is connected with sheath of optic nerve. The term papilloedema is exclusively used when

optic disc oedema is associated with raised intra-cranial tension.

In this study, we encountered 3 cases of Non Arteritic Anterior Ischemic optic neuropathy and 3 cases of neuroretinitis. The pathophysiology for optic disc oedema in Non Arteritic Anterior Ischemic optic neuropathy is axonal ischaemia and capillary leakage in optic nerve head<sup>5</sup>(Figure 1).

The term optic disc oedema or swelling is used when etiology of the disc oedema is other than raised intra-cranial tension. Optic neuritis was the commonest cause of optic disc swelling in our study which was followed by papilloedema, hypertensive retinopathy (Grade 4), neuroretinitis, CRVO, papillopathy associated with diabetes and Vogt Koyanagi Harada syndrome respectively. It is stated that occurrence of disc swelling in VKH was significantly correlated with age and disc morphology rather than severity of inflammation.<sup>6</sup> (Figure 2). Severe choroidal inflammation secondary to circulatory disturbances of branches of short post. Ciliary artery and/or centripetal branches from peri papillary choroid along with crowded discs may cause axonal flow stasis and secondary axonal swelling of the optic nerve in patients of VKH.<sup>7</sup>

Dimness of vision was the most common presenting symptom in this study followed by headache, ocular pain, floaters and diplopia.

#### 5. Conclusion

The most common presenting symptom was dimness of vision (62%) and the most common etiology of optic disc oedema was optic neuritis (46%).

#### 6. Source of funding

None.

#### 7. Conflict of interest

None.

#### References

1. Stavern GV. Optic Disc Edema. *Semin Neurol.* 2007;27(3):233–243.
2. Optic Neuritis Study Group. The clinical profile of optic neuritis. Experience of the Optic Neuritis Treatment. *Trial Arch Ophthalmol.* 1991;109:1673–1681.
3. The ischemic optic neuropathy decompression trial (IONDT): Design and Methods. *Control Clin Trials.* 1998;19:276–296.
4. Yanoff M, Duker JS. *Ophthalmology.* vol. 2.; p. 189.
5. Hayreh SS. Ischemic optic neuropathies - where are we now. *Graefes Arch ClinExpOphthalmol.* 2013;251:1873–84.
6. Rajendram R, Evans M, Khurana RN, Tsai JH, Rao NA. Vogt-Koyanagi-Harada disease presenting as optic neuritis. *Int Ophthalmol.* 2007;27(2-3):217–220.
7. Nakao K, Abematsu N, Mizushima Y, Sakamoto T, Mizushima Y, Sakamoto T. Optic disc swelling in Vogt-Koyanagi-Harada disease. *Invest Ophthalmol Vis Sci.* 2013;251:1917–1922.

**Author biography****Isha K. Patel** Assistant Professor**Trupti M Solu** Additional Professor**Yash R. Gandhi** Senior Resident**Shivranjani S. Balraj** 2nd Year Resident

**Cite this article:** Patel IK, Solu TM, Gandhi YR, Balraj SS. An analysis of clinical presentations and etiology of optic disc oedema. *IP Int J Ocul Oncol Oculoplasty* 2020;6(1):29-32.