



## Original Research Article

## Effect of focal laser in extrafoveal central serous retinopathy at a tertiary care institute

Arthi<sup>1</sup>, Rajakumari<sup>2,\*</sup><sup>1</sup>Aravind Eye Hospital, Puducherry, India<sup>2</sup>Dept. of Ophthalmology, Chettinad Hospital and Research Institute, Kelambakkam, Chennai, India

## ARTICLE INFO

## Article history:

Received 23-01-2020

Accepted 14-03-2020

Available online 24-04-2020

## Keywords:

Focal Laser

Central serous retinopathy

Foveal leakage

Visual acuity

## ABSTRACT

**Aim:** To evaluate the efficacy of focal laser in CSR patients with extra foveal leakage in terms of visual acuity and central foveal thickness and comparing it with the control group.

**Material and Methods:** About 60 patients who satisfied the inclusion criteria were selected and randomly assigned to laser group and study group. The patients in the laser group underwent focal laser where in pinpoint leaks were treated with burns of spot size 100-200µm, power of 100-200mW of 0.1ms duration. Patients were reviewed at 4 weeks and 12 weeks post laser.

**Results:** The commonest pattern in fluorescein angiography was the ink Blot pattern, 65% while the remaining 35% of the patients had a smock stack pattern. The difference in visual acuity between the baseline and at four weeks of the laser group was statistically significant by paired 't' test ( $p < 0.05$ ) where as it was not statistically significant in the control group ( $p = 0.136$ ).

**Conclusion:** Focal lasers are effective in cases of central serous chorioretinopathy which persists for a period of more than three months. Focal lasers can be used effectively to shorten the duration of the disease and results in the resolution of the subretinal fluid and improvement in visual acuity significantly by 4 weeks.

© 2020 Published by Innovative Publication. This is an open access article under the CC BY-NC-ND license (<https://creativecommons.org/licenses/by/4.0/>)

## 1. Introduction

Central serous chorioretinopathy (CSR) is an idiopathic disorder characterized by a localized and circumscribed serous detachment of the sensory retina at the macula secondary to leakage from the choriocapillaris through single or multiple hyperpermeable Retinal Pigment Epithelium (RPE) sites. It is usually confined to the central macula.

CSR has a long history of changing names reflective of the previous uncertainty about the etiology of the pathological process. Albrecht von Graefe<sup>1</sup> 1866 first described it as a recurrent central retinitis. Horniker<sup>2</sup> 1922 agreed that the pathology was localized to the Retina but thought these patients had an underlying angioneurosis causing angiospasm and exudation. He used the name Capillarospastic central retinitis.

Gifford and Marquardt<sup>3</sup> shared Horniker's view and coined the term Central angiospastic retinopathy. Bennet<sup>4</sup> also localized the disease to the retina and applied the name central serous retinopathy. Through fluorescein angiography, Maumenee<sup>5</sup> changed the concept of the primary tissue affected by describing the leak occurring at the level of the RPE.

Based on fundus fluorescein angiographic findings, Gass<sup>6</sup> added on to this view and termed the condition idiopathic central serous choroidopathy. Today CSR is the preferred term, since we understand that the neurosensory detachment occurs due to a leak in RPE resulting from the hyperpermeability at the choroid.

## 2. Aim

To evaluate the efficacy of focal laser in CSR patients with extra foveal leakage in terms of visual acuity and central foveal thickness and comparing it with the control group.

\* Corresponding author.

E-mail address: kirubasam01@gmail.com (Rajakumari).

### 3. Materials and Methods

#### 3.1. Study design and study setting

This is prospective study and conducted in Regional Institute of Ophthalmology and Government Ophthalmic Hospital.

#### 3.2. Study participants

60 patients with Central Serous Chorioretinopathy attending Uvea and Retina services in our department were included.

#### 3.3. Inclusion criteria

Patients with CSR in whom (i) Presence of SRF involving the fovea for a period of 3 months or longer in optical coherencetomography (OCT) images, (ii) Patients with CSR induced leakage 500 $\mu$ m away from fovea as demonstrated in FFA. (iii) Patients with a history of CSR in the other eye with an unfavourable outcome.

#### 3.4. Exclusion criteria

1. Patients with serous retinal detachment unrelated to CSR,
2. Eyes with history of previous Photo dynamic therapy or laser photocoagulation,
3. Eyes with Visual acuity 6/12 or better,
4. Patients with ocular infective and inflammatory diseases.

#### 3.5. Procedure

All patients diagnosed who were diagnosed as CSR under went through history taking to assess the presence of risk factors causing CSR. Then patients under go the following investigations such as Visual acuity, Automated refractometry reading and Subjective best corrected Visual acuity, Amslers Grid, Slit lamp examination, Slit lamp biomicroscopy with 90D, Indirect ophthalmoscopy, Fundus fluoresce in angiography, Optical coherencetomography. About 60 patients who satisfied the inclusion criteria were selected and randomly assigned to laser group and study group. The patients in the laser group underwent focal laser where in pinpoint leaks were treated with burns of spot size 100-200 $\mu$ m, power of 100-200mW of 0.1ms duration. The leaks were treated with 3-5confluent burns.

#### 3.6. Follow up

Patients were reviewed at 4 weeks and 12 weeks post laser. Visual acuity was checked. Slit lamp examination and dilated fundus examination with 90D and Indirect ophthalmoscopy was done. Optical coherencetomography was again repeated during the two visits to reassess the centralmacular thickness.

#### 3.7. Data analysis

Data entry and anaylsis was done using Epi\_info software package 3.5.4 version Analysis done was the visual outcome by measuring best corrected Visual acuity. Assessment of Central foveal thickness and resolution of Subretinal fluid by Optical coherencetomography.

### 4. Results

Our study population included patients from 24–59 years with a Mean age of 38.7. Majority of the patients (55%) belonged to the age group of 31–40 years and 25% of patients belonged to the 41–50 years group. Only 11.6% belonged to 21–30 years age group and 8.3% were above the age group of 50 years.

In our study, male subjects outnumbered females with 73.3% being male. Only 26.6% of the study group were females. In this study 83.3% of the patients had unilateral disease and bilateral CSR was present only in 16.6% of the patients. Inpatients with unilateral disease 27 patients had involvement of the right eye and in the remaining 23 patients left eye was involved. At presentation, 66.7% of patients had a BCVA of 6/18 - 6/24, and 26.7% of patients had a BCVA between 6/36 and 6/60.5% of the patients presented with a BCVA of 6/6–6/9.

Presence of mental stress in the recent past due to personal issues was found to be the most significant risk factor with 38.3% of patients confiding to have the history. The next significant risk factor type A personality with 28.3% of patients belonging to this category. Smoking was present in 26.7% of the patients and sleep disturbances in 21.7% of the patients.13.3% of patients included in our study gave history of steroid usage. Alcoholism, diabetes and hypertension were present in 15%, 8.3%and11.7% of the patients respectively. Many patients had a combination of one or more risk factors.

Among patients with a history of steroid usage, 6 patients gave history of using oral steroids. Of these four patients were using steroids over the counter without prescription of a physician and 2 patients were using it along with other medications for connective tissue disorder. One patient had a history of using steroid nasal spray for allergic rhinitis and one patient gave history of prolonged use of topical steroid following cataract surgery.

In our study group, 44% of patients gave history of acentral Scotoma while only16% of patients were able to give a history of metamorphopsia along with complaints of defective vision. Among our 60 study subjects, 17 patients gave a previous episode of CSR among whom 7 patients had an episodised in the same eye wheres as10 patients had an episode in the other eye. Remaining 43 patients had a persistent CSR lasting for more than 3 months.

The commonest pattern in fluoresce in angiography was the ink Blot pattern, 65% while the remaining 35% of the

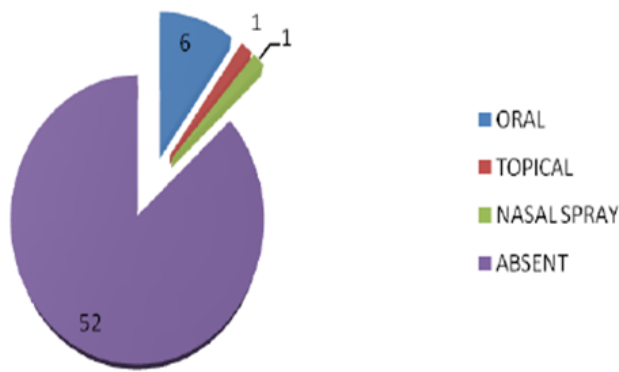


Fig. 1:

patients had a smock stack pattern. The CSR was associated with PED in 25% of the patients. Retinal pigment epithelial changes and defects were seen in 28.3% of the patients. One patient had congenital hypertrophy of the retinal pigment epithelium (bear track appearance) associated with CSR.

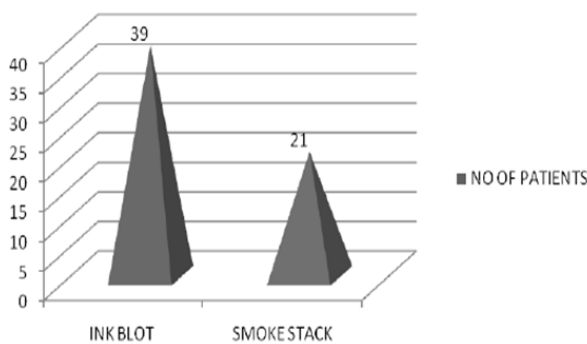


Fig. 2: 2:

In our patients 40% of the patients had leakage in the superonasal quadrant, 25% of patients had leakage in the inferotemporal quadrant. 20% of patients had leak in the superotemporal quadrant and 15% of patients had leak from the inferonasal quadrant. Patients with leakage in the foveal vascular zone were excluded from the study.

The mean central macular thickness of the control group at presentation was  $414.6 \pm 83.5 \mu\text{m}$  and that of the laser group was  $422.3 \pm 92.4 \mu\text{m}$ . Pigment Epithelial Detachment was present in 40% of patients which corresponded with that of fundus fluoresce in angiography. There was no evidence of Choroidal Neovascularisation Membrane in any patients at the time of presentation.

#### 4.1. Analysis of Efficacy of focal laser

In this study, 60 eyes of 60 patients who were diagnosed as CSR by fundus fluoresce in angiography and OCT satisfying aforementioned Criteria included in the study. The patients were assigned into two groups of 30 patients

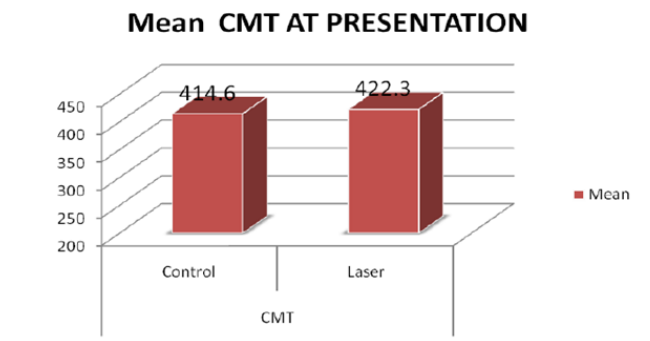


Fig. 3:

each by simple randomisation.

Group 1 was the observational group where the patients were observed over a period of 3 months. This served as the control group for our study. The patients in group 2 were the patients selected to undergo focal laser and served as the study group. These patients underwent focal laser where in pinpoint leaks were treated with burns of spot size 100-200  $\mu\text{m}$ , power of 100-200 mW of 0.1 ms duration. The leaks were treated with 3-5 confluent burns. The visual acuity of the patients was recorded at 4 weeks and 12 weeks post laser. They also

Underwent OCT to look for the central macular thickness and resolution of sub retinal fluid at 4 weeks and 12 weeks.

The mean central macular thickness of the control group at presentation was  $414.6 \pm 83.5 \mu\text{m}$  and that of the laser group was  $422.3 \pm 92.4 \mu\text{m}$ . The mean visual acuity of the control group at presentation was  $0.64 \pm 0.2$  and that of the laser group was  $0.6 \pm 0.15$  at presentation (in logMAR). The control group was age and sex matched to the study group and was comparable to the study group in terms of visual acuity ( $p=0.736$ ) and central macular thickness ( $p=0.188$ ) with no statistical difference between the two groups by independent 't' test at presentation.

The patients of the laser group were evaluated four months after the focal laser to the leakage points and the patients of the control group were evaluated after four months after their first presentation.

The Central macular thickness of the control group at four weeks was  $309.8 \pm 47.7 \mu\text{m}$  and that of the laser group was  $257.9 \pm 63.6 \mu\text{m}$ . There is a 25.3% decrease in the central macular thickness of the control group and 38.3% decrease in the study group. The difference between the 2 groups at 4 weeks in terms of visual acuity was strongly significant ( $p<0.01$ ) and CMT was significant ( $p<0.05$ ). Though the difference between the baseline CMT and CMT at four weeks was significant for both groups ( $p<0.01$ ) by paired T test, the percentage of decrease was more in the laser group when compared to the control group.

The visual acuity of the control group at four weeks had a mean  $0.43 \pm 0.2$  and the control group was  $0.2 \pm 0.1$ .

**Table 1:** Baseline parameters:

Baseline	Group	N	Mean	Std. Deviation	Std. Error Mean	P value
CMT	Control	30	414.6000	83.46736	15.23899	0.736
	Laser	30	422.3000	92.36179	16.86288	
Vision	Control	30	.6400	.17734	.03238	0.188
	Laser	30	.5833	.15105	.0275	

**Table 2:** Parameters at 4 weeks

4 weeks	Group	N	Mean	Std. Deviation	Std. Error Mean	P value
CMT	Control	30	309.8333	47.71473	8.71148	0.001
	Laser	30	257.9667	63.61061	11.61365	
Vision	Control	30	.4333	.21227	.0387	0.000
	Laser	30	.15757	.2000	.02877	

The difference in visual acuity between the baseline and at four weeks of the laser group was statistically significant by paired 't' test ( $p < 0.05$ ) whereas it was not statistically significant in the control group ( $p = 0.136$ ).

The mean central macular thickness of the study group was  $260.6 \pm 38 \mu\text{m}$  and that of the laser group was  $215.1 \pm 22 \mu\text{m}$ . The difference in the central macular thickness between the two groups was statistically significant ( $p < 0.01$ ). There was a 37.3% decrease in central macular thickness at 12 weeks from the baseline in the control group. This was statistically significant ( $p < 0.01$ ) by paired 't' test. The decrease in CMT of the laser group at 12 weeks was a 49% which was statistically significant ( $p < 0.01$ ).

The mean visual acuity of the control group was  $0.21 \pm 0.2$  in log MAR whereas that of the study group was  $0.1 \pm 0.2$ . The difference in visual acuity between both the groups was statistically significant ( $p < 0.05$ ). The improvement in visual acuity of both the laser group and the control group was statistically significant by paired 't' test ( $p < 0.01$ ).

Since the difference between the laser groups and control groups in terms of visual acuity and Central Macular Thickness is significant by paired 't' test, the effect size analysis is done to assess the usefulness of the intervention.

As depicted in the table the effect between baseline and the 12 months for CMT is 0.76 for the control group however the effect for the study group is 0.84. Similarly the  $r = 0.78$  for the control group whereas it is 0.88 for the laser group. This shows that the focal laser has a significant effect in the reduction of the central macular thickness and improvement in visual acuity when compared with the control group.

## 5. Discussion

This study was conducted in the Uvea and Retina services of Regional Institute of Ophthalmology, Government Ophthalmic Hospital where in 70 eyes of 60 patients diagnosed as CSR were included in the study.

The mean age in our study was found to be 38.7 years. The study conducted by Spaide et al and Tittl et al found

the mean age to be 51 years in individuals with Central serous Chorioretinopathy.<sup>7,8</sup> The mean age in our study is lesser than these previous studies. This may be because of the increasing incidence of stress and other risk factors like hypertension and smoking in younger individuals.

The male to female ratio in our study was found to be 2.75:1 with a Male preponderance. The previous studies conducted also show a male preponderance up to a ratio of 6:1. The increased incidence in male may be due to the increased prevalence of risk factors among males. Only 16.6% of the patients had bilateral CSR in our study group. Among the 10, 4 patients (40%) of patients have history of systemic steroid usage.

Recent history of mental stress was found to be the commonest risk factor with 38.3% of the patients having the history. The next highest risk factor was type A personality with 28.3% of the patients having this risk factor. Smoking was found in 26.7% of the patients compared to alcoholism which was found in 15% of the patients. 11.7% of the patients had hypertension and 8.5% of the patient had diabetes. History of steroid usage was found in 13.3% of the patients. This correlates to many risk factors cited by Haimovici et al.<sup>9</sup> there were no pregnant females in our study.

Among the 60 patients, only 13.3% of the patients had history of steroid usage. But in patients with bilateral CSR 50% of patients gave history of systemic steroid usage. Among them one patient who was on topical steroid had unilateral CSR. Therefore systemic steroid usage is a significant risk factor for bilateral CSR and in patients with bilateral condition this history should be asked for and patients should be asked to stop steroid and be put on other steroid sparing agents as per the requirements of the disease condition. About 73% of the patients complained of a central scotoma on presentation while 27% of the patients were able to appreciate metamorphopsia along with complaints of defective vision.

In this study population, 28.3% of patients had previous history of CSR suggesting recurrence. About 7 patients had an episode in the same eye whereas 10 patients had an

**Table 3:** Parameters at 12 weeks:

4 weeks	Group	N	Mean	Std. Deviation	Std. Error Mean	P value
CMT 12weeks	Control	30	260.5667	38.07043	6.95068	0.000
	Laser	30	215.1000	22.08190	4.03159	
Vision 12weeks	Control	30	.2167	.17436	.03183	0.001
	Laser	30	.0833	.11472	.02095	

**Table 4:**

GROUP	CMT		BCVA	
	COHEND	r	COHEND	r
Control Group	2.37	0.76	2.52	0.78
Laser Group	3.08	0.84	3.80	0.88

episode in the other eye. This corresponds to the Wilmer Retinal Vascular Centres study of CSR which documented a recurrence rate between 30%- 33%. The ink blot pattern was present in 65% of our patient with the smock stack pattern being present in only 35% of the patients. 25% patients had an associated pigment epithelial detachment with retinal pigment epithelial changes being present in 28.3% of the patients. The leaks were found to be more common in the superonasal quadrant in our study, with 40% of patients having leakage at this site. Patients with foveal leakage were excluded from our study.

The study conducted by Shahin M M showed 35% of patients had multifocal leaks. The commonest site of leak was the macula in 79% of patients. Extra foveal leakage was seen in 14% of patients and peripapillary leakage was seen in 12% of patients. The ink blot pattern was found in 53% of patient with RPE atrophic changes in 84% of the patients.<sup>10</sup>

The mean central macular thickness of the control group at presentation was  $414.6 \pm 83.5 \mu\text{m}$  and that of the laser group was  $422.3 \pm 92.4 \mu\text{m}$ . Pigment Epithelial Detachment was present in 40% of patients which corresponded with that of fundus fluorescein angiography. There was no evidence of Choroidal Neovascularisation Membrane in any patients at the time of presentation. Two distinct pattern of OCT findings have been documented in previous studies.<sup>11</sup> An optically empty elevated area of variable dimensions can be seen which corresponds to fundus fluorescein angiography. Small bulges can be observe highly characteristic small bulges could be observed protd as protruding from the retinal pigment epithelium corresponding to the leaking spots in fundus fluoresce in angiography. In the other variant, semicircular spaces beneath under the RPE with retinal thinning can be seen.

In our study we documented a significant decrease in the central macular thickness at 4weeks and 12 weeks post laser where the central macular thickness reduced by 38.3% at four weeks and 49% at 12weeks which was statistically significant ( $p < 0.001$ ) when compared with the control group. In the control group the central macular thickness reduced only by 25.3% at 4weeks and 37.3%

at 12 weeks. There was also a significant improvement in the visual acuity at 4weeks and 12weeks in the laser group which was statistically significant when compared with the control group ( $p < 0.01$ ). No side effects of laser was documented in our study subjects during the study period. Therefore this shows that laser treatment reduces the duration of the CSR along with a significant improvement in visual acuity. In a study conducted by Robertson et al, showed that direct laser photocoagulation reduced the central macular thickness and significantly reduced the duration of CSR when compared to patients undergoing sham laser and reduces the recurrences of CSR.<sup>12</sup> While the study conducted by Ficker and colleagues showed that Argon laser does not reduce the recurrences of CSR which may develop due to leakage in sites other than the previously lasered site in the retina.<sup>13</sup>

## 6. Conclusions

Focal lasers are effective in cases of central serous chorioretinopathy which persists for a period of more than three months. Focal lasers can be used effectively to shorten the duration of the disease and results in there solution of the subretinal fluid and improvement in visual acuity significantly by 4weeks. Mental stress, type A personality and sleep disorders are found to be significant risk factors in patients with CSR in our study. Systemic steroid usage is found to be a significant risk factor in patients with bilateral CSR. The most common site of extra foveal leakage in fundus fluoresce in angiography in our study was found to be in the superonasal quadrant (40%). The ink blot pattern was found to be most common pattern in fundus fluoresce in angiography (present in 65% of the patient). CSR was found to be associated with Retinal Pigment Epithelial detachment in 25% of the patients by FFA and OCT.

## 7. Source of funding

None

## 8. Conflicts of interest

None

## References

1. Graefe AV. Ueber central recidivierende Retinitis. *Graefes Arch Clin Exp Ophthalmol.* 1866;12:211–215.
2. Horniker E. Su di una forma recidivante central di origine vasocurrotica (retinite central capillaro spastica). *Ann ottal.* 1927;55:578–600.
3. Gifford SR, Marquardt G. Central angiospastic retinopathy. *Arch Ophthalmol.* 1939;21(2):211–228.
4. Bennett G. Central Serous Retinopathy. *Br J Ophthalmol.* 1955;39(10):605–618.
5. Maumenee AE. Symposium: macular diseases, clinical manifestations. *Trans Am Acad Ophthalmol Otolaryngol.* 1965;69:606–613.
6. Gass J. Pathogenesis of disciform detachment of the neuroepithelium. II. Idiopathic central serous choroidopathy. *Am J Ophthalmol.* 1967;63:587–615.
7. Spaide RF, Campeas L, Haas A, Yannuzzi LA, Fisher YL, et al. Central Serous Chorioretinopathy in Younger and Older Adults. *Ophthalmol.* 1996;103(12):2070–2080.
8. Tittl MK, Spaide RF, Wong D. Systemic and ocular findings in central serous chorioretinopathy. *Am J Ophthalmol.* 1999;128:63–68.
9. Haimovici R, Koh S, Gagnon DR, Lehrfeld T, Wellik S. Central Serous Chorioretinopathy Case- Control Study Group. Risk factors for central serous chorioretinopathy: a case - control study. *Ophthalmol.* 2004;111(2):244–249.
10. Shahin M. Angiographic characteristics of central serous chorioretinopathy in an Egyptian population. *Int J Ophthalmol.* 2013;6(3):342–345.
11. Montero JA, Ruiz-Moreno J. Optical coherence tomography characterization of idiopathic central serous chorioretinopathy. *Br J Ophthalmol.* 2005;89(5):562–564.
12. Robertson DM, Ilstrup D. Direct, Indirect, and Sham Laser Photocoagulation in the Management of Central Serous Chorioretinopathy. *Am J Ophthalmol.* 1983;95(4):457–466.
13. Ficker L, Vafidis G, While A, Leaver P. Long-term follow-up of a prospective trial of argon laser photocoagulation in the treatment of central serous retinopathy. *Br J Ophthalmol.* 1988;72(11):829–834.

## Author biography

Arthi Fellow

Rajakumari Professor

**Cite this article:** Arthi , Rajakumari . **Effect of focal laser in extrafoveal central serous retinopathy at a tertiary care institute.** *IP Int J Ocul Oncol Oculoplasty* 2020;6(1):23-28.