



## Original Research Article

## A study on the prevalence of type 2 diabetes mellitus as an incidental finding in patients with pterygium

Soumya Sharat<sup>1,\*</sup><sup>1</sup>Dept. of Ophthalmology, Minto Ophthalmic Hospital BMCRI, Bengaluru, Karnataka, India

## ARTICLE INFO

## Article history:

Received 23-02-2020

Accepted 28-02-2020

Available online 24-04-2020

## Keywords:

pterygium

diabetes

correlation

## ABSTRACT

**Introduction:** To study the prevalence of type 2 diabetes mellitus as an incidental finding in patients with pterygium.

**Materials and Methods:** A cross-sectional study was conducted in a tertiary care eye hospital among patients with pterygium, who had been posted for pterygium excision surgery. The study was conducted over a period of three months. 25 patients were enrolled under the study. All cases of operable pterygium were taken up for surgery and studied. Only patients with primary pterygium were included in the study. The random blood sugar levels were monitored, and if found deranged, patients were further investigated for fasting blood sugar levels, post-prandial blood sugar levels and glycosylated hemoglobin levels. Previously diagnosed diabetics and patients with other systemic comorbidities were excluded from the study.

**Results:** Out of the 25 patients enrolled under the study, the mean age was 43 years. 15 patients (60%) were males, and rest were females. Of these, 10 patients (40%) had deranged random blood sugar levels (>130 mg/dl), which were further investigated by fasting blood sugar levels, post-prandial blood sugar levels and glycosylated hemoglobin levels. After these investigations, 6 patients (24%) were newly detected type 2 diabetes mellitus patients, and they were referred to physician for further management of the condition.

**Conclusion:** The etiology of pterygium is multifactorial, though, none can explain the development or the recurrence of pterygium. Though the relationship between pterygium and diabetes is not significant, the role of oxidative stress in these patients needs further investigations.

© 2020 Published by Innovative Publication. This is an open access article under the CC BY-NC-ND license (<https://creativecommons.org/licenses/by/4.0/>)

### 1. Introduction

Pterygium is a wing shaped encroachment of the conjunctival tissue on the cornea.<sup>1</sup> It can also be defined as a benign lesion which is characterized by fibrovascular

proliferation of the conjunctiva and the underlying Tenon's capsule.<sup>2</sup> Pterygium is more prevalent in regions with tropical climate. Advanced age, males, working outdoors, especially in rural areas and illiteracy are considered as the risk factors for developing pterygium.<sup>3</sup> The pathogenesis of pterygium is primarily associated with ultraviolet-B (UVB) radiations, though it can be also be multifactorial.<sup>4</sup> UVB radiations induced oxidative stress

plays a critical role in the pathogenesis of pterygium.<sup>5</sup> The hypothesis that is now considered under the etiology of pterygium is that it most likely occurs due to a growth disorder which is characterized by localized ultraviolet stimulated damage to the limbal stem cells, resulting in encroachment of subconjunctival tissue onto the cornea.<sup>6</sup> Pterygial fibroblasts induced destruction of limbal stem cells is yet another reason responsible for corneal invasion.

Type-2 diabetes mellitus (DM) is characterized by elevated blood glucose level with insulin resistance. Metabolic alterations occurs in patients with deranged blood glucose levels which alters the inflammatory response of the body, which in turn results in increased production of free oxygen radicals and impaired neutrophil function. Thus, in the pathogenesis of pterygium and diabetes, oxidative stress

\* Corresponding author.

E-mail address: soumya.sai@rediffmail.com (S. Sharat).

is one of the common factors. In our study, we investigated the prevalence of type 2 diabetes mellitus as an incidental finding in patients with pterygium.

## 2. Materials and Methods

A cross-sectional study was conducted in a tertiary care eye hospital among patients with pterygium, who had been posted for pterygium excision surgery. The study was conducted over a period of three months. 25 patients were enrolled under the study. All cases of pterygium which needed surgical intervention were included and studied. Only those patients with primary pterygium were included in the study. The random blood sugar levels were monitored, and if found deranged, patients were further investigated for fasting blood sugar levels, post-prandial blood sugar levels and glycosylated hemoglobin levels. Previously diagnosed diabetics and patients with other systemic comorbidities were excluded from the study.

The patients underwent a complete ocular evaluation. Visual acuity was recorded using Snellen's visual acuity chart. Pupillary reaction was noted. Thorough evaluation of the patients with slit lamp biomicroscopy and fundus examination with indirect ophthalmoscope with 20 dioptre lens was done. Location and extent of the pterygium, and whether the pterygium was of progressive or non-progressive type were noted. A written informed consent was taken, explaining the complications of the procedure and minimal chances of recurrence after surgical excision, from all patients. All patients enrolled under the study, underwent pterygium excision with conjunctival autograft.

## 3. Results

Out of the 25 patients enrolled under the study, the mean age was found to be 43 years. 15 patients (60%) were males, and rest was females. Of these, 10 patients (40%) had deranged random blood sugar levels ( $>130$  mg/dl), which were further investigated by fasting blood sugar levels, post-prandial blood sugar levels and glycosylated hemoglobin levels. After these investigations, 6 patients (24%) were newly detected type 2 diabetes mellitus patients, and they were referred to physician for further management of the condition.

## 4. Discussion

Pterygium is an abnormal proliferation and encroachment of the conjunctival tissue onto the cornea. Pathologically, there are degenerative and hyperplastic changes in this hypervascularised tissue along with proliferative and inflammatory features. Pterygium is usually considered to be a benign lesion, but at times it can also display malignant characteristics such as excessive proliferation, corneal invasion with or without vascularization especially in certain cases of recurrent pterygium. Elevated blood

## Sex Incidence

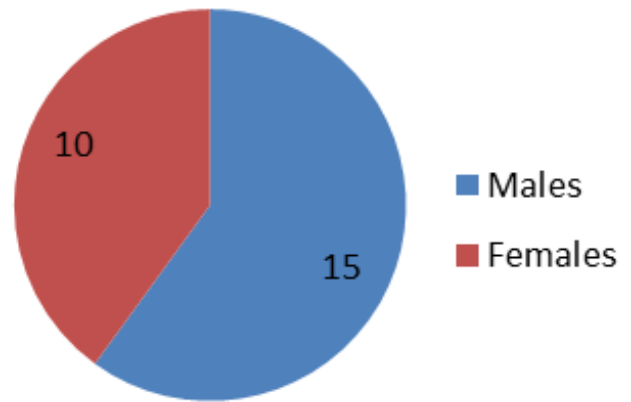


Fig. 1: Sex incident

## Prevalence of type 2 Diabetes Mellitus in patients with pterygium

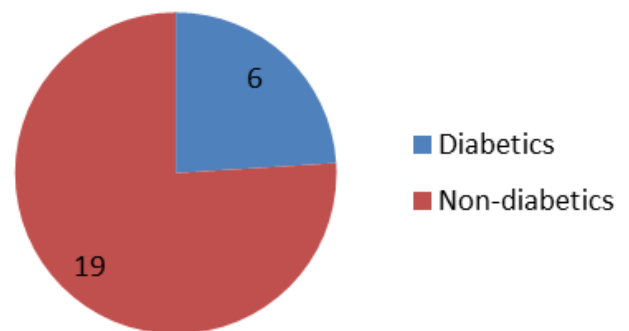


Fig. 2: Prevalence of type 2 Diabetes Mellitus in patients with pterygium

glucose levels in patients with Type 2 diabetes mellitus can alter the production of inflammatory mediators and oxygen free radicals. This can lead to decreased or altered immune response, delayed wound healing, and sometimes proliferation of neoplastic cells. Studies in literature have shown the correlation between diabetes and certain types of neoplasms.<sup>7</sup>

In our study, pterygium was more common among males. This correlates well with the study done by Riordan-Eva et al, in which were males and rest were females.<sup>8</sup> This can be attributed to the prevalence of pterygium in the dry, arid, sunny parts of the world, and more common in males who especially work outdoors in agricultural fields, labourers, etc.

In our study, the mean age at presentation was 43 years. This correlates well with a study by Philip Chen et al., in which ages of patients ranged from 23-79 years and the

mean age in that study was 45.6 years.<sup>9</sup>

There was no significant correlation between diabetes and development of pterygium in our study. This correlates well with the study by Eryigit Eroglu et al., in which both the prevalence of diabetes and pterygium were higher among females, though there was no significant relationship between diabetes and pterygium.<sup>10</sup>

## 5. Conclusion

Various metabolic events occurring in the body can have an impact on the eye. Though the etiology of pterygium is multifactorial, development or the recurrence of pterygium cannot be clearly explained by any of the factors. Though the relationship between pterygium and diabetes is not significant, the role of oxidative stress in these patients needs further evaluation. Also studies at molecular level need to be initiated to understand the correlation between them.

## 6. Source of funding

None.

## 7. Conflict of interest

None.

## References

1. Jack J, Kanski B, Bowling. Clinical ophthalmology a systematic approach. Elsevier; 2011.
2. Coster D. Pterygium—an ophthalmic enigma. *Br J Ophthalmol.* 1995;79(4):304–305.
3. Nemesure B, Wu SY, Hennis A, Leske MC. Barbados Eye Studies Group. Nine-year incidence and risk factors for pterygium in the Barbados eye studies. *Ophthalmol.* 2008;115:2153–2158.
4. Bradley JC, Yang W, Bradley RH, Reid TW, Schwab IR. The science of pterygia. *Br J Ophthalmol.* 2010;94(7):815–820.
5. Perra MT, Maxia C, Corbu A, Minerba L, Demurtas P, et al. Oxidative stress in pterygium: relationship between p53 and 8-hydroxydeoxyguanosine. *Mol Vis.* 2006;12:1136–1142.
6. Dushku N, Reid TW. Immunohistochemical evidence that human pterygia originate from an invasion of vimentin-expressing altered limbal epithelial basal cells. *Curr Eye Res.* 1994;13(7):473–481.
7. Onitilo AA, Engel JM, Glurich I, Stankowski RV, Williams GM, et al. Diabetes and cancer I: risk, survival, and implications for screening. *Cancer Causes Control.* 2012;23(6):967–981.
8. Riordan-Eva P, Kielhorn I, Ficker LA, Steele ADM, Kirkness CM. Conjunctival autografting in the surgical management of pterygium. *Eye.* 1993;7(5):634–638.
9. Philip C, Ariyasu RG, Kaza V. A Randomized Trial Comparing Mitomycin C and Conjunctival Autograft After Excision of Primary Pterygium. *Am J Ophthalmol.* 1995;120:151–160.
10. Eroglu E, Eroglu L, O. Prevalence of Diabetes Mellitus in Patients with Pterygium. *EJMI.* 2018;2:80–82.

## Author biography

Soumya Sharat Assistant Professor

**Cite this article:** Sharat S. A study on the prevalence of type 2 diabetes mellitus as an incidental finding in patients with pterygium. *IP Int J Ocul Oncol Oculoplasty* 2020;6(1):17-19.