



Original Research Article

Analysis of ocular trauma due to firecracker injury in oculoplasty clinic at a tertiary care hospital of North India

Himani Gupta¹, Priyanka Gupta^{1,*}, Rupali Tyagi¹, Manisha Gupta¹

¹Dept. of Ophthalmology, Shri Guru Ram Rai Institute of Medical and Health Sciences, Dehradun, Uttarakhand, India



ARTICLE INFO

Article history:

Received 17-12-2019

Accepted 21-12-2019

Available online 26-12-2019

Keywords:

Ocular trauma

Firecracker injury

Medicolegal

ABSTRACT

Purpose: To evaluate the spectrum of ocular injuries, clinical and demographic profile and management patterns following firecracker injury during three days of festive season of 'Deepavali'.

Materials and Methods: A hospital-based, retrospective study of 19 patients, who sustained ocular injuries following firecracker injury during three days of festive season of Deepavali from 28/10/19 to 30/10/19 visiting emergency department of SMIH, Dehradun. All the patients were attended in collaboration with on call ophthalmologists and plastic surgery burn unit team. Vision assessment was done using Snellen's chart. Slit lamp examination including anterior segment evaluation and fundus examination was done in cases possible. USG B-scan and X-Ray orbit were done in cases required. Patients with severe injuries were advised admission and managed either conservatively or surgically. Surgical intervention included corneo-scleral tear repair and evisceration. Rest of the patients were treated on outpatient basis.

Results: The firecrackers causing ocular injuries include Bomb in 37% cases, Flowerpot in 31.5%, Rocket in 21% and Sparkles in 10.5% cases. The spectrum of ocular involvement included periocular burns in 100% cases, corneal abrasion in 74%, corneal perforation and hyphema in 16%, lid and conjunctival laceration and globe rupture in 11%, and iridodialysis and vitreous hemorrhage in 5% cases. The devastating visual outcomes were seen in 10% cases. 89.5% cases underwent medico-legal consultation.

Conclusion: Firecracker injury leads to physical and mental trauma to the patients. Adult supervision is very crucial while igniting firecrackers. Appropriate triage management and coordinated treatment was critical to ensure best possible patient outcome. Enforcement of legislations, health education and public awareness are essential in preventing this hazard to ocular health in country.

© 2019 Published by Innovative Publication. This is an open access article under the CC BY-NC-ND license (<https://creativecommons.org/licenses/by/4.0/>)

1. Introduction

India is a country of festivals and ceremonies, and fireworks are an inseparable means of this celebration. But unfortunately, accidents due to firecracker lead to severe and dangerous injuries and irreparable damage to vision. Ocular injuries constitute 20% of firework injuries.^{1,2} It includes trivial epithelial defects to sight losing globe rupture. In India, firecracker injuries are common during the festival of 'Deepavali'. In vision 2020, special emphasis is given on avoidable blindness especially in children, so attempt is to be made to prevent such injuries and blindness.³

We conducted a study to assess firecracker injuries seen within three days of festive season of Deepavali to highlight the importance of Firecracker as a cause of ocular injuries in India, its clinical spectrum and management patterns. We have taken into account medico-legal aspects which have not been taken into consideration in any other paper as far to the best of our knowledge.

2. Materials and Methods

This study is a hospital-based, retrospective study. 19 patients sustaining ocular injuries with fire cracker visiting emergency department of SMIH, Patel Nagar, Dehradun during three consecutive days i.e. one day before, on the day and one day after 'Deepavali' festival from 28/10/2019

* Corresponding author.

E-mail address: priyankagupta8405@gmail.com (P. Gupta).

to 30/10/2019 were analyzed. Patients with closed eye injuries were treated on an outpatient basis, most cases with open eye injury were advised admission. Admitted patients included patients with corneal and scleral tears, traumatic iridodialysis, with hyphema, intraocular foreign body and globe rupture.

All the patients were seen in oculoplasty clinic and underwent complete ocular examination. Visual acuity was tested using Snellen’s chart. Slit lamp and fundus examination was done in all cooperative patients. Ultrasonography B scan and X-Ray orbit were done as and when required to see any retained intraocular foreign bodies in cases of open globe injuries. The spectrum of ocular involvement, details of management, demographic profile, nature, site, type of firecracker inflicting injury, visual acuity at the time of presentation and intervention done were noted.

3. Results

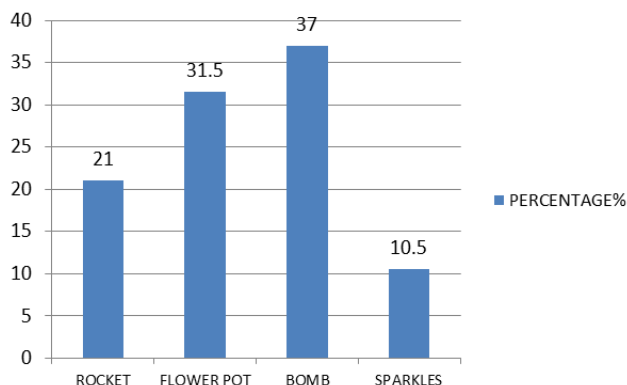


Fig. 1: Types of fireworks causing ocular injuries in percentage(%).

Table 1: Table showing visual acuity at the time of presentation in emergency department

Visual Acuity	No. of eyes (Total 25)	%
>6/12	14	56
6/12-6/60	5	20
6/60-CF	1	4
HM-PL	3	12
NO PL	2	8

Out of total 19 patients seen, 14 were males. The age range of these patients was 4 to 28 years (mean of 13 years). The most common cause of ocular injuries were Bombs(37%) followed by flower pot (cone fountain 31.5%), Rocket(21%) and Sparkles 10.5% (Figure 1).

The age group most commonly affected with fire cracker injury was 11-15 year and least common was 26-30 years(Figure 2). Bottle rockets and Bombs were responsible

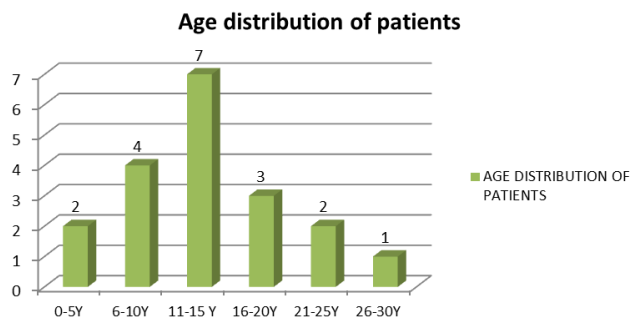


Fig. 2: Age distribution of patients

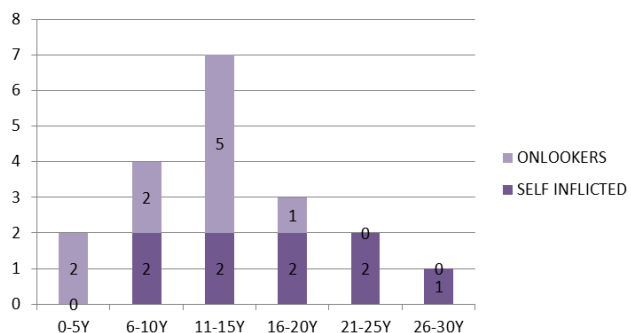


Fig. 3: Showing age wise distribution of ocular injuries self inflicted and onlooker

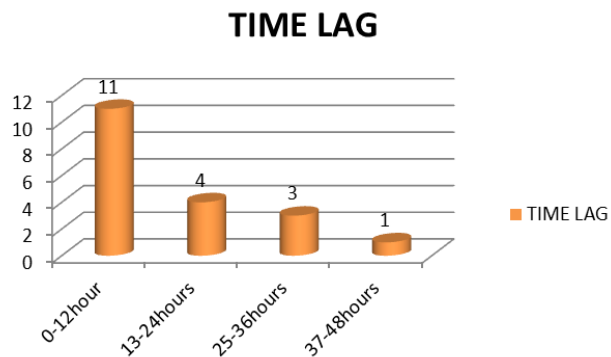


Fig. 4: Showing time taken to seek medical consultation following injury in hours

for the most serious ocular injuries observed in our patients.

According to initial assessment of vision at time of presentation to hospital, two eyes of two patients had no perception of light(PL negative), three patient had vision hand movement to PL positive and one patient had counting finger to 6/60 visual acuity (Table 1). Vision of two children was not recorded as were less than five years and not cooperative at time of initial presentation. The distributions of eye injury were nearly equal among onlookers and actively involved individuals among different age groups (Figure 3).

Playing under supervision

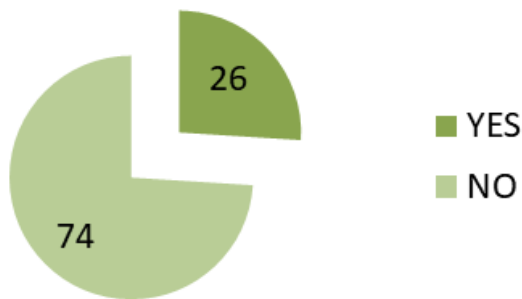


Fig. 5: Showing injuries (%) caused while playing under supervision or not

Cases(%)

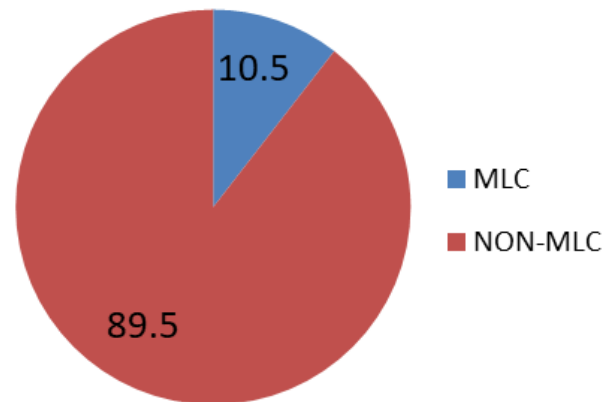


Fig. 8: Showing percentage of medico-legal cases versus non medico-legal cases(%).

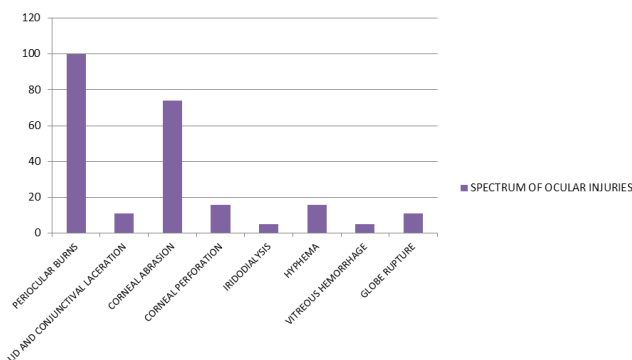


Fig. 6: Showing spectrum of ocular injuries following fire cracker injury in percentage(%).

Management(%)

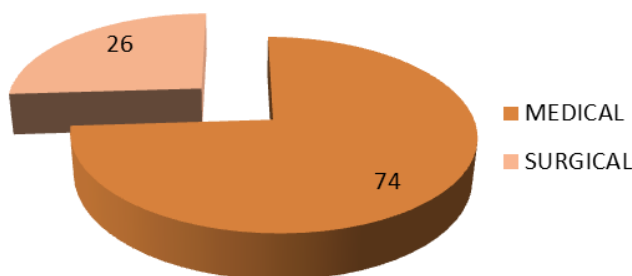


Fig. 7: Showing percentage(%) of patients managed by medical treatment and by surgery

The time taken to seek medical consultation following firecracker injury was variable. Most common being consultation within first 12 hours of injury and least being within 2 days of injury (Figure 4). None of the firecracker victims reported was using any protective eye wear at time of injury. Only 26% patients were indulged in playing within the supervision of parents or guardians (Figure 5).

In 100% patients periocular burns was present, 74% had corneal abrasins, 16% presented with corneal perforation and hyphema, 11% had lid and conjunctival lacerations and globe rupture while 5% had iridodialysis and vitreous hemorrhage(Figure 6).

In all 7 patients were admitted to our hospital with firecracker injury. Three patients underwent surgery for corne-oscleral tear repair and 2 underwent Evisceration. Rest other patients were managed conservatively as per standard protocol for ocular burns and chemical injuries. Injured eyes were irrigated with copious amount of normal saline and particulate matter and soot particles were removed with forceps under topical anaesthesia, pH was monitored before and after ocular irrigation. (Figure 7). Out of total patients, two patients went for medico-legal consultation (Figure 8).

4. Discussion

Fireworks are pyrotechnic devices commonly displayed worldwide during festive occasion such as celebration of national and religions events. As such, firework related injuries are common around the time of these occasions, such as Deepavali.⁴

In three days of emergency, during peak days of Deepavali, 57 patients reported to the emergency with injuries like fractures following road traffic accident, fall

from height, chest pain, severe vomiting, pain in abdomen, etc. Out of which, 26 patients reported following firecracker injury. Firecrackers can cause injury to hands, eyes, head and face. Out of 26, 19 patients sustained ocular injury with firecrackers and these were analyzed in our study. Ophthalmologists are frequently involved in care of these patients because of high rate of ocular injury.⁵ Incidence of ocular injury in this study was 73%.

In spite of strict rules and regulations on use of fireworks, administrative implementation in bringing down incidence of fireworks related injuries is a failure.⁶

In this study, majority of the patients were males. This is consistent with observation from previous studies.^{7–9} This is due to the fact that males are more outrageous and have higher presence in streets.¹⁰

The most common firecracker causing injury in our study were bombs followed by flower pots (Figure 1). It was consistent with other studies.¹¹ Sparkles were found to cause minimal injuries in one of the studies.¹² Most bottle rocket injuries were of serious nature same as reported by other studies.⁸

Although almost all age groups could be equally affected by firecracker injuries but majority of the cases in our study was of age group 11-15 years (Figure 2). Other studies^{13,14} had majority of cases in age group 6-10 years.

Negligent behavior during igniting fireworks are mostly the cause of accidents.⁵ But literature has many examples showing that injuries may be sustained by those who work in vicinity of firework being launched.^{4,15} This is also seen in our study. Severe injuries are naturally encountered for active participants because they are likely to be closer to focus on fireworks (Figure 3).

Time is an important factor in any type of injury and same is true for ocular injury. Any patient reaching within golden period has better prognosis and better best possible outcome based on the type of injury. This golden period is very crucial. In our study, most of the cases were brought to the hospital within 12 hours as most of the private set up were closed during festival days (Figure 4). Our hospital being a tertiary care centre has 24 X 7 emergency services. So, these patients were attended efficiently by our on call unit and showed gradual improvement.

In the studied group, risky behaviors like lack of adult supervision while igniting firecrackers was quite prevalent in all age groups (Figure 5). Children should not be allowed to play with firecrackers be it bomb or sparkles in absence of parents or guardian. They are at risk because of their curious nature and their excitement when in close proximity with fireworks. They also cannot anticipate danger and are unable to keep themselves safe and act decisively at time of sudden accident, so need supervision.

The ocular injuries varied in presentation and severity. More than half of patients in our study had no significant effect on vision at the time of presentation while some

were unfortunate to lose eye (Table 1). There are studies reporting upto one-third of permanent blindness among children who sustained ocular injury due to fireworks. Timely intervention led to significant improvement in visual acuity in those affected by fireworks injury. Factors leading to poor visual outcome in other publications were open globe injury, poor initial visual acuity, intraocular foreign body, retinal detachment and endophthalmitis¹⁶. In our study, globe rupture was assessed with poor visual acuity outcome. 8% had no Perception of light and 4% had finger counting at three metre while in study by John et al.¹⁴ 5.1% had no PL and 11.9% had vision more than finger counting at three metre in one injured eye. Our study demonstrates magnitude of severe ocular morbidity and loss of vision in child due to firecracker injury.

There is a wide spectrum of ocular involvement in firecracker injuries. It ranges from small corneal abrasion to severe globe rupture. The injuries were diverse involving superficial and deep ocular structures as well as periocular tissues. The most common injuries were similar to the other large series.^{16,17} It included periocular burns, corneal abrasions, lid and conjunctival lacerations, corneal perforations, hyphaema, iridodialysis, vitreous hemorrhage and globe rupture (Figure 6). In almost all patients, periocular burns were present, so treatment was done in collaboration with plastic surgery burn unit.

Corneal abrasion, an injury known for its chronic course and long healing time 2-3 week was quite common in our study (74%). While, one of study shows 13.8% presence and is consistent with the study by Venkatesh⁷ while in study by Patel and Mukherjee,⁸ hyphaema and traumatic cataract were more common.

Of the total patients visiting emergency following firecracker injury in our study, 36% required hospitalization which was more in compared to a study where only 5% were hospitalized¹⁸ while in other study 44%¹² required inpatient care.

These patients were managed either conservatively or surgically. In our study, surgical intervention was done in 26% patients (Figure 7). It included corneo-scleral tear repair under general anesthesia in around 16% cases. While in cases of globe rupture, Evisceration was done in general anaesthesia in children.

74% patients were managed conservatively on a regular outpatient basis. They were given ample amount of lubricants and antibiotic eye drops as per requirement of individual patient. For periocular burns, plastic surgery consultation was done and treatment was started as per protocol.

These firecracker injuries lead to complete physical, cosmetic as well as mental trauma to the patients. These patients are very vulnerable and have very low self-esteem. The most dangerous impact is of mental trauma because of disfigurement, burn scars, loss of eye etc leading to suicidal

tendencies. So, counseling by an expert psychologist was also done. And if medico-legal scenario comes into picture, it further worsens the mental state of the patient or his family as well as of accused. It leads to depletion of money, resources and most importantly the valuable time of both the parties (Figure 8).

Ocular injuries from fireworks are common during Deepavali and often visually devastating. Overall, patients in this study had improvement in vision but few injuries resulted in permanent vision loss. We hope the data presented will increase awareness of these injuries and help to influence public policy and promote further regulation of fireworks as well as concomitant selling of appropriate grade-protective eyewear. Appropriate triage management and coordinated treatment by ophthalmologist is critical in case of these patients in order to ensure best possible patient outcome. Strict check on quality of firecrackers and promoting safe use via schools and media will also have positive impact. The enforcement of existing legislations, health education and public awareness are essential preventive measures for curbing this hazard to ocular health in country.

Limitations of this study are that we included only those who sustained firecracker injury during 3 consecutive days around Deepavali. We did not include those who presented later on during other festive seasons. This resulted in underestimation of burden of problem. It was a retrospective study so no records of pre-injury vision was available.

5. Acknowledgements

None

6. Conflict of interest

None

7. Financial interest

None

References

- Academy of pediatrics: Committee on Injury and Poison Prevention. Fireworks-related injuries to children. *Pediatrics*. 2001;108:190–191.
- Witsaman RJ, Comstock RD, Smith GA. Pediatric fireworks-related injuries in the United States:1990-2003. *Pediatrics*. 2006;118:296–303.
- Gilbert C, Foster A. childhood blindness in the context of vision 2020-The right to sight. *Bull World Health Organ*. 2001;79:227–232.
- Arya SK, Malhotra S, Dhir SP, Sood S. Ocular fireworks injuries clinical feature and visual outcomes. *Indian J Ophthalmol*. 2001;49:189–190.
- Kuhn FC, Morris RC, Wiherspoon DC, Mann L, Mester V, et al. Serious fireworks-related eye injuries. *Ophthalmic Epidemiol*. 2000;7:139–148.
- Tandon R, Agrawal K, Narayan RP, Tiwari VK, Prakash V, et al. firecracker injuries during Diwali festival: the epidemiology and impact of legislation in Delhi. *Indian J Plast Surg*. 2012;45:97–101.
- Venkatesh R, Gurav P, Tibrewal S, Agrawal M, Dubey S, et al. Appraising the spectrum of firework trauma and the related laws during Diwali in North India. *Indian J Ophthalmol*. 2017;65:140–143.
- Patel R, Mukherjee B. Crash and burn: Ocular injuries due to fireworks. *Semin Ophthalmol*. 2016;31:243–248.
- Singh DV, Sharma YR, Azad RV. Visual outcome after fireworks injuries. *J Trauma*. 2005;59:109–111.
- Hatamabadi HR, Tabatabaey A, Heidari K, Karim MK. Firecracker injuries during Chahrshanbeh Soori festival in Iran. A case series study. *Arch Trauma Res*. 2013;2:46–49.
- Kumar R, Puttanna M, Sriprakash KS, Rathod BLS, Prabhakaran VC. Firecracker eye injuries during Deepavali festival:A case series. *Indian J Ophthalmol*. 2010;58:157–159.
- Puri V, Mahendru S, Rana R, Deshpande M. Firework injuries: A ten-year study. *J Plast Reconstr Aesthet Surg*. 2008;62:1103–1111.
- Wilson RS. Ocular fireworks injuries and blindness. An analysis of 154 cases and a three-state survey comparing the effectiveness of model law regulation. *Ophthalmol*. 1982;89:291–297.
- John D, Philip SS, Mittal R, John SS, Paul P. Spectrum of ocular firework injuries in children. A 5-year retrospective study during a festive season in Southern India. *Indian J Ophthalmol*. 2015;63:843–846.
- Wisse RP, Bijlsma WR, Stilma JS. Ocular firework trauma: A systematic review on incidence, severity, outcome and prevention. *Br J Ophthalmol*. 2010;94:1586–1591.
- Dhir SP, Shishko MN, Krewi A. Ocular firework injuries in children. *J Pediatr Ophthalmol Strabismus*. 1991;28(6):354–355.
- Raj PS. Fireworks and the eye. *J R Med Soc*. 1989;82(4):242–242.
- Abbott J, Shah P. The epidemiology and etiology of pediatric ocular trauma. *Surv Ophthalmol*. 2013;58:476–485.

Author biography

Himani Gupta Junior Resident

Priyanka Gupta Assistant Professor

Rupali Tyagi Associate Professor

Manisha Gupta Professor and HOD

Cite this article: Gupta H, Gupta P, Tyagi R, Gupta M. Analysis of ocular trauma due to firecracker injury in oculoplasty clinic at a tertiary care hospital of North India. *Int J Ocul Oncol Oculoplasty* 2019;5(4):251-255.