



Original Research Article

To study the clinico-etiological profile and management practices of case series of innervational motility disorders which can be classified under CCDD'S

Reena Gupta^{1,*}, Neebha Anand¹, Seemanchal Goel¹, Chekitaan²

¹Dept. of Ophthalmology, RIO, Post Graduate Institute of Medical Sciences, Rohtak, Haryana, India

²Ishwar Eye Centre, Rohtak, Haryana, India



ARTICLE INFO

Article history:

Received 15-10-2019

Accepted 30-11-2019

Available online 26-12-2019

Keywords:

Misinnervation

Upshoot

Abnormal head posture

Globe retraction

Ocular misalignment

ABSTRACT

Material and Methods: The study was conducted at Pediatric Ophthalmology and strabismus clinic at our tertiary care institute PGIMS, Rohtak. The study was a descriptive pilot study which was conducted between January 2017 to April 2019. All patients who reported to pediatric ophthalmology and strabismus clinic, PGIMS, Rohtak, diagnosed as Congenital fibrosis of EOM, Duane's retraction syndrome, Mobius syndrome, Congenital strabismus with abnormal vertical movements, MEDs and variants of Dysinnervational disorders were included in our study.

Results: In the study a total of 25 cases were taken with 22 cases having a follow up of 6 months, with 71% cases being females and rest being males, 27% cases had bilateral involvement, 32% had left and 41% had right eye involvement. 56% had strabismic amblyopia, 11% had anisometropic and rest had visual axis obscuration. 10 cases from the total were treated with surgery and 4 were managed conservatively, a follow up of >6 months was taken and results were noted.

Discussion: Of the multiple observations made through this study some of the most important ones were that patients with CFEOM have variable angle strabismus mainly Exotropia with hypertropia, Muscle hypoplasia with displaced scleral insertions were seen, two staged surgical correction of remnant muscles resulted in good ocular alignment, AHP was frequently present, there was association of CCDD's with complex strabismus, predominant vertical ocular motility defects helped as a tool for diagnosing variants of CCDD's, cosmetic alignment with correction of face turn helped a long way in restoring self confidence of patients, Congenital MED with innervational pathology was included and Knapp's procedure has proved to be effective in treating strabismus, AHP, ocular elevation.

Conclusion: Classification and unification of congenital disorders of ocular motility continues to evolve and unlock the complexity of mechanism of etiopathogenesis of CCDD, and advanced imaging is opening new doors of managing these cases successfully each day, further research in genetic basis of this disease complex can yield us better results in future.

© 2019 Published by Innovative Publication. This is an open access article under the CC BY-NC-ND license (<https://creativecommons.org/licenses/by/4.0/>)

1. Introduction

Isolated strabismus affects around 1–5% of the population.¹ A subset of isolated strabismus syndromes is characterized by congenital, non-progressive ophthalmoplegia with restricted globe movements in one or more fields of gaze. This group of sporadic and familial strabismus syndromes was initially called as the 'congenital fibrosis

syndromes^{2,3} because the primary pathologic process was assumed to reside in extraocular. Broadly, the concept of the 'congenital fibrosis syndromes' includes CFEOM,⁴ Duane syndrome^{5–9} Möbius syndrome^{10,11} (in which fibrotic extraocular muscles are often found),^{12,13} and certain other sporadic and hereditary disorders of ocular motility.^{14,15} Over the last 40 years, data has accumulated supporting the concept that the origin of Duane syndrome may be neuropathic rather than myopathic.¹⁶ Phillips et al.¹⁷ reported the absence of the 6th cranial nerves bilaterally in

* Corresponding author.

E-mail address: reenaguptasingh@rediffmail.com (R. Gupta).

a girl with convergent strabismus. Four additional autopsy reports of Duane syndrome have documented anatomic absence of the abducens nerve^{18–21} and electromyography revealed paradoxical innervation of the lateral rectus by the oculomotor nerve that probably occurs in the absence of normal innervation by the abducens nerve.^{22,23} Duane syndrome also occurs in the setting of other conditions with anomalous axonal guidance.²⁴

Based on the growing neuropathologic and genetic evidence, the term ‘congenital fibrosis syndrome’ may focus attention on muscle pathology in a set of disorders where absent and/or anomalous innervation of the extraocular muscles is the most likely pathophysiology.

Gutowski et al²⁵ proposed the term of CCDDs. They define these disorders include CFEOM, congenital ptosis, Duane’s syndrome, Duane radial ray syndrome, horizontal gaze palsy with progressive scoliosis (HGPPS), and Möbius syndrome. The CCDDs would also encompass developmental disorders of non-ocular cranial nerves, such as congenital familial facial weakness. They summarised the features of the CCDDs as follows:

1. Congenital, non-progressive abnormalities of cranial musculature that result from developmental abnormalities of one or more cranial nerves with primary or secondary muscle dysinnervation.
2. Primary may result from absence of normal muscle innervation. Secondary may occur from aberrant muscle innervation during development by branches of other nerves.
3. It can be accompanied with secondary muscle pathology and/or other bony and orbital structural abnormalities.
4. Horizontal ocular motility defects are likely to result from abnormalities in the development of the sixth nerve and/or nucleus (Duane’s syndrome and HGPPS).
5. Abnormal development of facial nerve usually results in facial abnormalities, sometimes with associated ocular motor abnormalities (congenital facial weakness and Möbius syndrome).

Thus group of non-progressive neuromuscular disorders leading to complex strabismus syndromes which result from development abnormality of 1 or more cranial nerves with primary or secondary muscle dysinnervation come under CCDD.

Recently, Kolling et al²⁶ indicated congenital Brown’s syndrome is caused by missing fourth cranial nerve in some cases, which put it in the category of congenital dysinnervation.

MEDs have been recognized to be associated with disorders of innervation. (Table 1)

2. Material and Methods

The study was conducted at Pediatric Ophthalmology and Strabismus clinic at Regional Institute of Ophthalmology, PGIMS, Rohtak. The study was a descriptive pilot study conducted from Jan 2017 to April 2019. All patients who reported to paediatric ophthalmology and strabismus clinic, PGIMS, Rohtak, diagnosed as Congenital fibrosis of EOM, Duane’s retraction syndrome, Möbius syndrome, Congenital strabismus with abnormal vertical movements, MEDs and variants of Dysinnervational disorders were included in the study.

Written and informed consent was taken and the study protocol was approved by the institutional ethics committee, complete ophthalmological exam was undertaken with the following investigations.

Best corrected visual acuity, fixation patterns, ocular motility, presence of binocularity and stereoacuity measurement using titmus fly for near and distance randot test for distance, recording of AHP both for distance and near, orthoptic evaluation for near (33cm) and distance (6m) in all nine gazes to look for patterns, measurement and documentation of ocular misalignment – by PBCT or Krimsky test.

MRI examination was done in indicated cases. Hess charting, anterior and posterior segment, diagnosis and management of amblyopia was done in required cases. Surgical intervention was the mainstay of treatment and was customised according to the case. All patients were subjected to pre anaesthetic checkup and children less than 15 years were operated under general anaesthesia. Informed consent was taken.

3. Results

1. Total no. of cases
2. Cases with 6 months follow up - 22
3. Lost follow up - 3

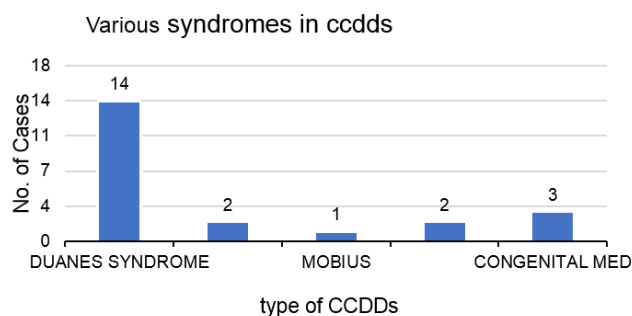


Fig. 1:

Table 1: Showing classification of CCDD

CCDDs primarily affecting	Horizontal ocular motility	Vertical ocular motility	Facial muscles + ocular motility defects
	DRS DS + radial ray (DRRS) Horizontal gaze palsy with progressive scoliosis	CFEOMs (Type 1,2,3) Congenital ptosis	Congenital facial weakness Mobius syndrome

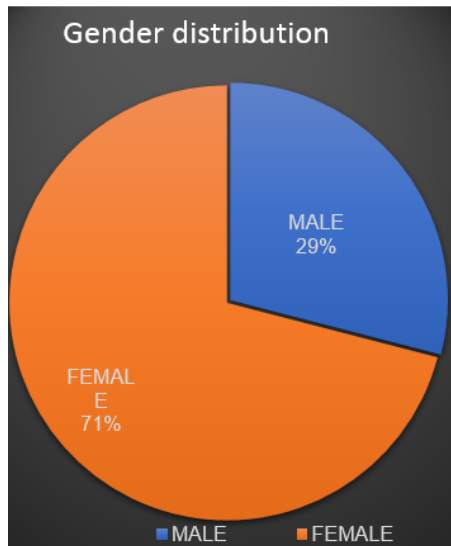


Fig. 2: Sex distribution in total cases

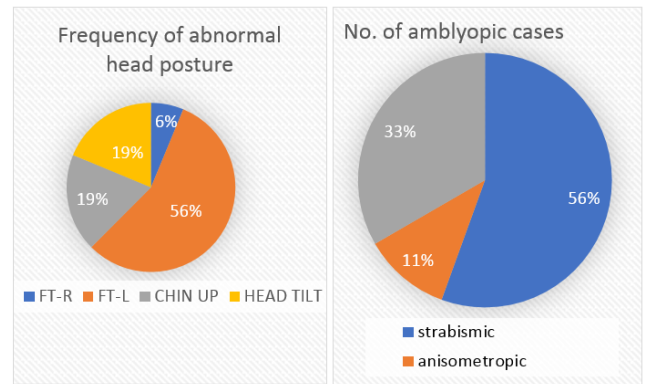


Fig. 4: Frequency of abnormal head posture and distribution of amblyopia.

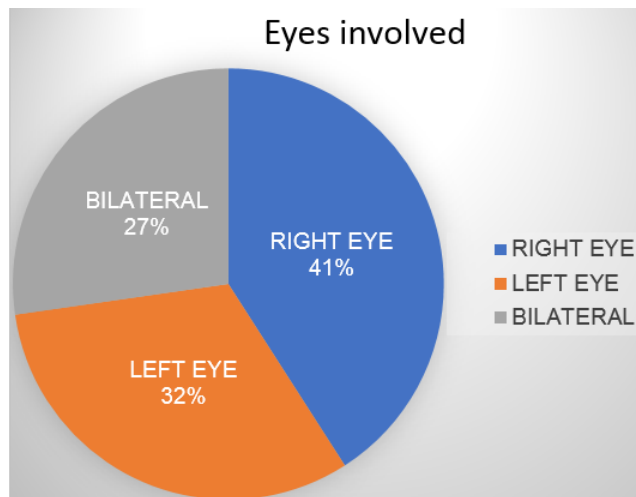


Fig. 3: Distribution of eyes involved in cases

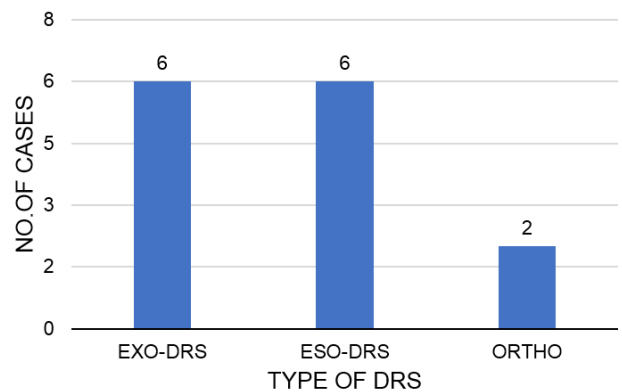


Fig. 5: Distribution of duane retraction syndrome in total cases

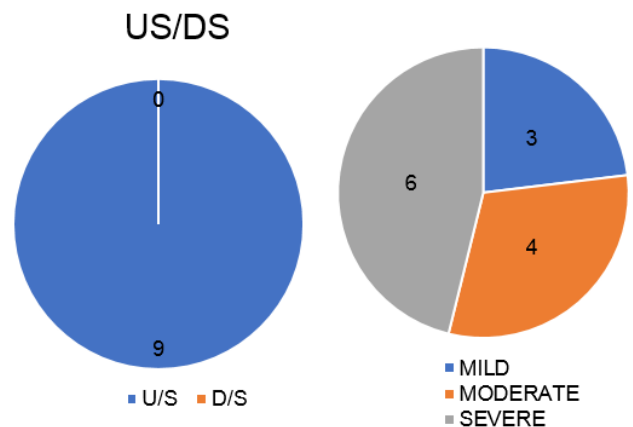


Fig. 6: Distribution of upshoot/downshoot and globe retraction

3.1. Surgery done for CFEOM case- in a two staged procedure

1. B/L LR Recesson with IR Recesson
2. B/L MR Recesson

3.2. Surgery done in CCDD variant

1. LR+MR Recesson

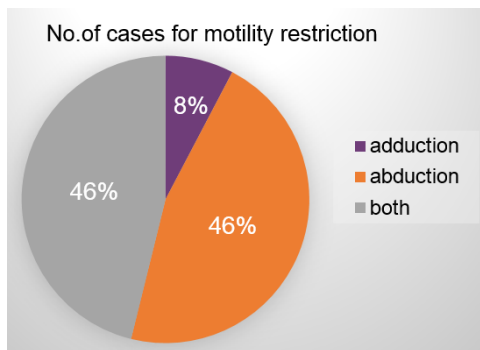


Fig. 7: Distribution of cases with motility restriction

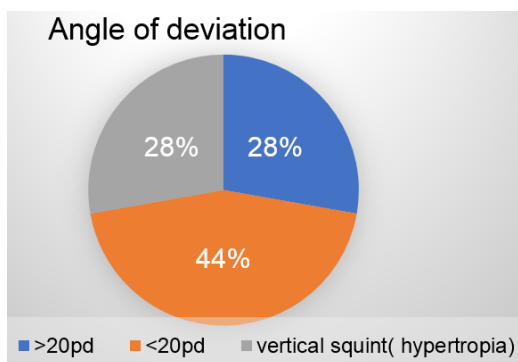


Fig. 8: Distribution of deviation severity measured in angle of deviation

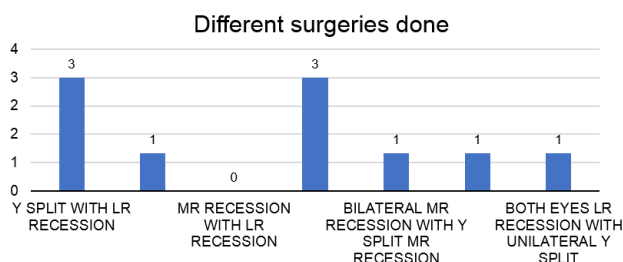


Fig. 9: Distribution of type of surgery done in patients

2. LR Recession with MR resection

Mobius Syndrome

1. MR+SR Recession

Improvement noted in face turn, ocular movements and cosmetic alignment

Angle of deviation was reduced but was still there.

4. Discussion

In the past studies it was found that Duane retraction syndrome is the most common type of CCDD with female preponderance and higher incidence of unilateral cases with

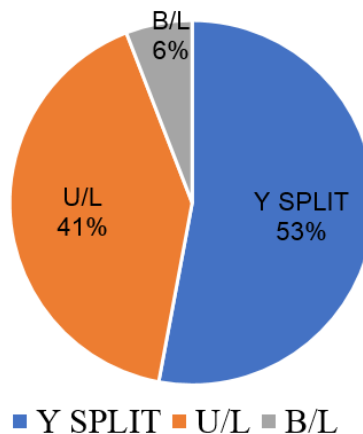


Fig. 10: Frequency of Y-Split surgery done in total cases

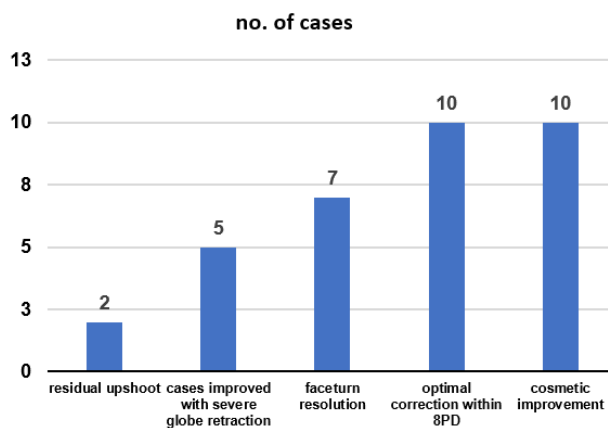


Fig. 11: Final post operative improvements in cases

left eye dominantly affected. Type-1 is most common (abduction limitation) with 50% of cases having AHP (Face turn) and amblyopia on presentation.²⁷

The cases had Clinical presentation as upshoots, globe retraction, motility restriction (abduction > adduction) and strabismus (both horizontal and vertical) with small angle of deviation in primary position. Surgery was mainstay of treatment and Y split proved to be effective in treating upshoots where 2 had residual upshoots (20%).

The results unique to our study were that, normally the incidence was 4-5% per 60% of cases with variable incidence of adduction limitation (more in combination). Equal frequency of eso and exo DRS was found with Severe Globe retraction more commonly seen. Both horizontal recti recession was needed to treat co-contraction, effectively in 50% of cases.²⁸

We achieved 70% success in correcting face turn, 71.4% success in achieving optimal correction of strabismus but significant improvement wasn't seen in ocular movements.

Patients with CFEOM have variable angle strabismus mainly Exotropia with hypertropia with presence of bilateral ptosis. Muscle hypoplasia with displaced scleral insertions were seen and two staged surgical correction of remnant muscles resulted in good ocular alignment. Congenital defect in innervation of muscles, secondary anatomical changes-tightness of muscles, the frequent presence of AHP, association with complex strabismus and predominantly vertical ocular motility defects helped as a tool for diagnosing variants of CCDD's.

Variable limitation of adduction with horizontal gaze involvement, presence of lid lag and case based tailored approach helped a long way in treating patients with CCDD. Cosmetic alignment with correction of face turn helped a long way in restoring self confidence of patients with knapp's procedure proving to be effective in treating strabismus, AHP and ocular elevation.^{29,30}

5. Conclusion

Classification and unification of congenital disorders of ocular motility continues to evolve and unlock the complexity of mechanism of etiopathogenesis of CCDD. Advance high resolution imaging techniques has opened the door for better planning and management of these cases. Active recruitment and screening of such cases leads to betterment of understanding of pathophysiology and clinical picture of congenital ocular motility disorder but further research in understanding the genetic basis of CCDD's and applying the knowledge to clinical presentation may yield better results.

6. Source of funding

None.

7. Conflict of interest

None.

References

- Engle E. The genetics of strabismus: Duane, Moebius and fibrosis syndromes. In: Traboulsi E, editor. Genetic diseases of the eye: a textbook and atlas. Louis, MO: Mosby ; 1998,. p. 477–512.
- Brown H. Congenital structural muscle anomalies. In: Allen J, editor. Strabismus Ophthalmic Symposium. vol. 1950. St. Louis, MO: Mosby ; 1995,. p. 205–236.
- Engle E. Applications of molecular genetics to the understanding of congenital ocular motility disorders. *Ann N Y Acad Sci.* 2002;956:55–63.
- Harley R, Rodrigues M, Crawford J, J. Congenital fibrosis of the extraocular muscles. *Trans Am Ophthalmol Soc.* 1978;76:197–226.
- Hueck G. Über Angeborenenvererbten Beweglichkeitsdefect der Augen. *Klin Monatsbl Augenheilkd.* 1879;17:253.
- Stilling J, Bergmann J. Untersuchungen über die Entstehung der Kurzsichtigkeit. 1887;13 ; .
- Turk S. Über retraktionsbewegungen der Augen. *Deutsch Med Wochenschr.* 1896;22:199.
- Duane A. Congenital deficiency of abduction, associated with impairment of adduction, retraction movements, contractions of the palpebral fissure and oblique movements of the eye. *Arch Ophthalmol.* 1905;34:133–159.

- Derespinis PA, Caputo AR, Wagner RS, Guo S. Duane's retraction syndrome. *Surv Ophthalmol.* 1993;38:257–288.
- Anonymous. Handbuch der Gesamten Augenheilkunde. Engelmann, Leipzig; 1880;.
- Möbius P. Über Angeborenen Doppelseitige Abducens-Facialis-Lähmung. *München Med Wochenschr.* 1888;35:91–94.
- Towfighi J, Marks K, Palmer E, Vannucci R. Möbius syndrome. Neuropathological observations. *Acta Neuropathol.* 1979;48:11–17.
- Traboulsi E, Maumenee I. Extraocular muscle aplasia in Möbius syndrome. *J Pediatr Ophthalmol Strabismus.* 1986;23:120–122.
- Glaser J, Bachynski B. Congenital motor and sensory anomalies. In: WT, Jaeger E, editors. Duane's clinical ophthalmology. Lippincott, Philadelphia, PA ; 1993; .
- Parks M, Mitchell P. Ophthalmoplegic syndromes and trauma. In: Tasman W, Jaeger E, editors. Duane's clinical ophthalmology. Lippincott, Philadelphia, PA ; 1993; .
- Hoyt W, Nachtigaller H. Anomalies of ocular motor nerves. Neuroanatomic correlates of paradoxical innervation in Duane's syndrome and related congenital ocular motor disorders. *Am J Ophthalmol.* 1965;60:443–448.
- Philips W, Dirion J, Graves G. Congenital bilateral palsy of the abducens. *Arch Ophthalmol.* 1932;10:355–364.
- Matteucci P. I difetti congeniti di abduzione con particolare riguardo alla patogenesi. *Rassegna Italiana d'Ottalmologia.* 1946;15:345–380.
- Hotchkiss M, Miller NR, Clarke AW, Green WR. Bilateral Duane's retraction syndrome: a clinical-pathological case report. *Arch Ophthalmol.* 1980;98:870–874.
- Miller NR, Kiel SM, Green WR, Clarke AW. Unilateral Duane's retraction syndrome. *Arch Ophthalmol.* 1982;100:1468–1472.
- Hickey W, Wagoner M. Bilateral congenital absence of the abducens nerve. *Virchows Arch.* 1983;402:91–98.
- Blodi F. Electromyographic evidence for supranuclear gaze palsies. *Trans Ophthalmol Soc UK.* 1970;90:451–469.
- Huber A. Electrophysiology of the retraction syndromes. *Br J Ophthalmol.* 1974;58:293–300.
- Gutowski N. Duane's syndrome. *Eur J Neurol.* 2000;7:145–149.
- Gutowski N, Chilton J. The congenital cranial dysinnervation disorders. *Arch Disease Childhood.* 2015;100:678–681.
- Assaf AA. Congenital innervation dysgenesis syndrome (CID)/congenital cranial dysinnervation disorders (CCDDs). *Eye (Lond).* 2011;25:1251–1261.
- Gaur N, Sharma P. Management of Duane retraction syndrome: A simplified approach. *IJO.* 2019;67(1):16–22.
- Ozkan SB. Pearls and pitfalls in the management of Duane syndrome. *Taiwan J Ophthalmol.* 2017;7(1):3–11.
- 110th ENMC International Workshop: The congenital cranial dysinnervation disorders (CCDDs). Naarden, The Netherlands 25–27 October, 2002 ; .
- Gutowskil NJ. *Neuromuscular Disorders.* 2003;13:573–578.

Author biography

Reena Gupta Associate Professor

Neebha Anand Professor

Seemanchal Goel Post Graduate

Chekitaan Senior Consultant

Cite this article: Gupta R, Anand N, Goel S, Chekitaan . To study the clinico-etiological profile and management practices of case series of innervational motility disorders which can be classified under CCDD'S. *Int J Ocul Oncol Oculoplasty* 2019;5(4):233-237.