



Original Research Article

Preoperative and postoperative evaluation of corneal astigmatism after pterygium operation using diamond Burr

Krisna Prabha Shastry¹, Nupur Sharma^{2,*}, Dheerendra Singh², Priti Singh², Kavita Kumar²

¹Shekar Eye Hospital, Bengaluru, Karnataka, India

²Dept. of Ophthalmology, Gandhi Medical College, Bhopal, Madhya Pradesh, India



ARTICLE INFO

Article history:

Received 30-11-2019

Accepted 10-12-2019

Available online 26-12-2019

Keywords:

Diamond Burr

Visual acuity

Pterygium

Keratometry

ABSTRACT

Introduction: The study was conducted with the objective to compare the visual acuity and astigmatism before and after pterygium operation using diamond Burr.

Materials and Methods: This study was conducted as prospective follow up study on patients with primary pterygium inducing visually significant astigmatism. Visual acuity, K reading, astigmatism were recorded before surgery and at 1 week, 6 week and 12 week following surgery whereas corneal clarity was assessed post operatively. The pterygium remnant tissue over cornea was polished using a Diamond Burr.

Result: Mean age of patients was 46.88 ± 10.61 years. The study was comprised of 77.1% females. Mean BCVA (LogMAR) preoperatively was 0.26 ± 0.19 whereas that at 12th week was 0.12 ± 0.08 and the improvement was statistically significant. The mean astigmatism also reduced significantly ($p < 0.01$). Also a significant improvement in K average and corneal clarity at various follow up was observed ($p < 0.01$).

Conclusion: Pterygium surgery with diamond burr application for corneal smoothing, significantly improves the visual acuity, corneal keratometry and pterygium induced astigmatism.

© 2019 Published by Innovative Publication. This is an open access article under the CC BY-NC-ND license (<https://creativecommons.org/licenses/by/4.0/>)

1. Introduction

Pterygium is derived from a Greek word “pterygion” meaning wing. It is a wing-shaped, fibrovascular overgrowth arising from subconjunctival tissue extending across the limbus onto the cornea. Pterygium is described as a degenerative condition of the subconjunctival tissue which proliferates as vascularized granulation tissue to invade cornea, also it destroys superficial layers of stroma and Bowman’s membrane.^{1,2} Worldwide prevalence of pterygium varies from 1-25 percent based on the population which is being studied.³ The epidemiological studies around the world have shown that the prevalence rates range from 0.3% to 37.46%.⁴

Various etiologies have been proposed in the pathogenesis of pterygium. These include ultraviolet radiation,⁵ limbal stem cells,⁶ chronic keratitis theory,⁷ chronic

conjunctival theory.⁷ Pterygium may be symptomless or may present with foreign body sensation, redness, dryness and irritation. The pterygium affects vision due to its growth across pupillary axis or may indirectly cause visual problems due to induced corneal astigmatism (mostly with the rule).⁸ Although previous studies have established that pterygium surgery decreases pterygium-induced astigmatism, corneal distortion may not be completely normalized in eyes with advanced pterygium.^{9,10}

A pterygium surgery that is not performed effectively can cause a remnant pterygium tissue on the cornea, which will lead to corneal scarring, high astigmatism, and reduced visual function. Thus, for smoothing of corneal surface beneath the pterygium head, a Diamond burr is used to polish the corneal bed after pterygium excision is done. Diamond burr is a battery powered, handheld, low torque motorized burr. It has been designed to polish the corneal bed after pterygium excision; it can also be used to remove

* Corresponding author.

E-mail address: nupur17sham@gmail.com (N. Sharma).

foreign bodies from cornea or sclera of the patients and, it has been successfully used in treating spontaneous corneal epithelial defects in combination with a bandage contact lens.¹¹ Corneal polishing significantly decreases the corneal astigmatism and corneal aberrations which would result in visual improvement.¹¹ Smoothing of the corneal surface after primary pterygium excision is a cost-effective, time saving technique to treat anterior corneal scars and high corneal astigmatism related to pterygium.¹²

2. Objective

To evaluate the improvement in visual acuity and astigmatism following pterygium operation using Diamond Burr.

3. Materials and Methods

3.1. Study area

The study was conducted at tertiary eye care, Coimbatore.

3.2. Study design

The study was designed as a prospective follow up study

3.3. Duration of study

One year from 1st January 2016 to 31st December 2016

3.4. Study population

The study was conducted on patients presenting with primary pterygium causing visually significant astigmatism and belonging to age range of more than 18 years.

3.5. Sample size

35 eyes of 35 patients attending the Eye OPD and fulfilling the inclusion and exclusion criteria.

3.6. Sampling technique

Systematic random sampling.

3.7. Inclusion criteria

Our study included patients with more than 18 years of age presenting with primary pterygium (nasal or temporal) causing visually significant astigmatism, recurrent irritation, or due to cosmetic reasons and pterygium encroaching upon the cornea leaving ≥ 2 mm of clear uninvolved zone from the visual axis.

3.8. Exclusion criteria

All the patients presenting with ocular infections, history of ocular trauma, unfit for surgery due to bleeding abnormalities or anti-coagulant therapy, patients with

double headed or recurrent pterygium and patient with corneal opacity, degeneration, dystrophy, lens changes or any posterior segment pathology affecting the vision were excluded.

3.9. Methodology

After obtaining ethical clearance from Institute and written informed consent for surgery from all the patients, a detailed information regarding socio-demographic data, history of presenting illness and ocular complaints were obtained and entered in questionnaire. Also, uncorrected and best corrected visual acuity for distance (converted into LogMAR) along with anterior chamber examination with Slit Lamp Biomicroscopy was done for the diagnosis of pterygium and characteristics such as grade, type and site were recorded.

The grading of pterygium was done according to Tan et al classification as:

1. T1 (atrophic)- episcleral vessels under the body of the pterygium not obscured and clearly distinguishable;
2. T2 (intermediate)- episcleral vessels under the body of the pterygium obscured partly and indistinguishable.
3. T3 (fleshy)-episcleral vessels totally obscured.

Along with this, cornea was assessed using Automated Keratometry (Topcon ARK). This was followed by surgical excision of pterygium under all aseptic precautions. The pterygium remnant tissue over cornea was polished using a Diamond Burr (ALGERBRUSH II). After excising the graft, the conjunctival-limbal graft was slid onto the cornea. A blob of Viscoelastic (Appavisc PFS Hydroxypropyl Methylcellulose) was put over the cornea at the end of the surgery. Two drops of antibiotic drops was instilled in the conjunctival cul-de sac and the eye was firmly patched. Patients were followed-up for a minimum period of 12 weeks (1st week, 6th week and after 12 weeks).

3.10. Statistical analysis

The data was compiled using Ms Excel and analysed using SPSS 2.0. Student t test was used to compare improvement in visual acuity and keratometry reading. p value of <0.05 was considered significant whereas p value less than 0.01 was considered highly significant.

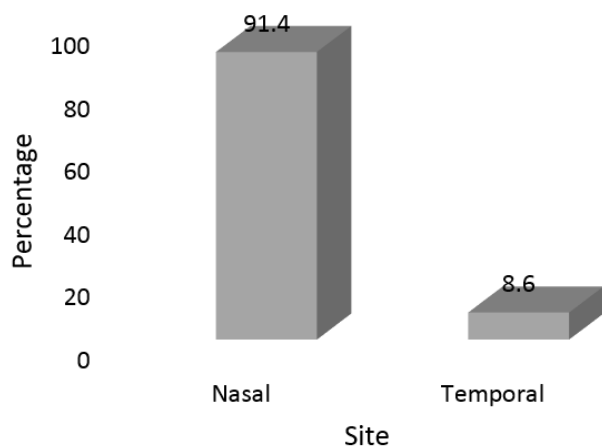
4. Result

The study was conducted on a total of 35 patients with primary pterygium.

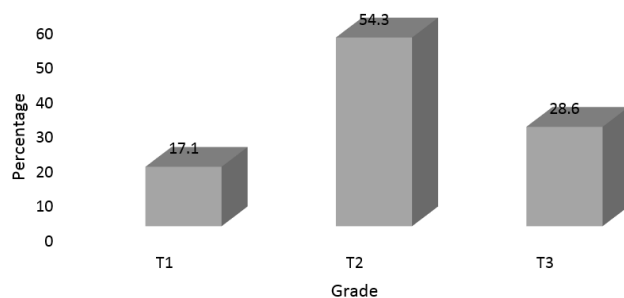
Mean age of 35 patients presenting with primary pterygium was 46.88 ± 10.61 years. About 37.4% patients belonged to 51 to 60 years of age group followed by 31.4% patients in the age range of 41 to 50 years. The study was comprised of 77.1% females whereas only 22.95 patients were males.

Table 1: Distribution according to demographic variables

Demographic variables (n=35)		Frequency	Percentage
Age group (years)	≤30	2	5.7
	31-40	5	14.3
	41-50	11	31.4
	51-60	13	37.1
	>60	4	11.4
Gender	Male	8	22.9
	Female	27	77.1

**Fig. 1:** Distribution according to site of pterygium

Nasal pterygium was observed in 32 (91.4%) patients whereas pterygium involved temporal side in 3 (8.6%) patients.

**Fig. 2:** Distribution according to grading of pterygium

The grading of pterygium was done according to Tan et al classification. T2 grade was the most common grade observed in 19 (54.3%) patients followed by T3 grade in 10 (28.6%) and T1 grade in 6 (17.1%) patients.

Preoperatively, Mean BCVA (LogMAR) was 0.26 ± 0.19 which gradually improved at 12th week and was documented as 0.12 ± 0.08 . Test of significance (ANOVA) observed statistically significant improvement in mean visual acuity at various follow up as compared to

preoperative visual acuity ($p < 0.01$).

K average improved significantly from 43.89 preoperatively to 45.89 at 12th week follow up post operatively ($p < 0.01$).

The mean astigmatism preoperatively was -2.86 ± 0.61 which significantly reduced through various follow up to -0.84 ± 0.47 at 12th week follow up and the difference was statistically highly significant ($p < 0.01$).

Also we assessed corneal clarity at various follow up post pterygium excision. At 1st week post operatively, corneal clarity of grade 1 and 2 were observed in 12 (34.3%) and 23 (65.7%) eyes. Corneal clarity of grade 1 and 2 were observed in 17 (48.6%) and 18 (51.4%) patients respectively at 6th week whereas corneal clarity grade 1 was observed in 30 (85.7%) and grade 2 was observed in only 5 (14.3%) patients at final follow up. The improvement in corneal clarity was statistically significant ($p < 0.05$).

5. Discussion

The development of a pterygium can lead to significant astigmatism. A pterygium usually causes localized flattening of the cornea.¹³ The magnitude of astigmatism increases with the grade of pterygium. Subsequently, successful pterygium surgery should reduce pterygium induced refractive astigmatism and improve visual acuity.¹⁴

Mean age of patients was 46.88 ± 10.61 years. Maximum occurrence of pterygium was observed in 41 to 60 years of age group and amongst female population. The higher occurrence of pterygium could be explained by the fact that pterygium is associated with cosmetic disfigurement and female thus seek medical attention due to cosmetic reasons. The mean age at presentation was similar to study by Makkar et al i.e. 50.48 years however, they documented higher incidence of pterygium in males as males are more exposed to outdoor activity and hence the occurrence of pterygium is nearly twice as often in men than in women.¹⁵ The findings of present study were contrasting to study by Garg et al in which the authors observed pterygium in younger age of population i.e. 39.69 years as compared to our study.⁸

Majority of patients had pterygium on nasal side in present study (91.4%) whereas only 8.6% patients had pterygium on temporal side. These findings were similar to

Table 2: Comparison of Best corrected visual acuity (LogMAR)at various follow up

Timing	Mean	Standard deviation	ANOVA	P value
Pre operatively	0.26	0.19		
1 st week	0.18	0.15	6.19	0.001
6 th week	0.13	0.11		
12 th week	0.12	0.08		

Table 3: Comparison of keratometry findings

K average	Mean	Standard deviation	ANOVA	P value
Pre operatively	43.89	1.38		
1 st week	44.98	1.44	3.43	0.02
6 th week	45.71	1.46		
12 th week	45.89	1.61		

Table 4: Comparison of astigmatism

Timing	Mean	Standard deviation	ANOVA	P value
Pre operatively	-2.86	0.61		
1 st week	-1.41	0.58	39.71	0.001
6 th week	-0.93	0.51		
12 th week	-0.84	0.47		

findings of study by Rao et al in which the authors reported pterygium on nasal side in 86.8% patients.¹⁶

Visual acuity, keratometry and astigmatism were noted preoperatively, at 1st, 6th and 12th week postoperatively. We documented statistically significant improvement in all the three parameters at final follow up as compared to pre-operative values. Narsamiah et al also reported postoperatively, there was a statistically significant reduction in astigmatism and improvement in UCVA, BCVA, spherical equivalent in all eyes.¹¹ Ozgurhan et al also observed statistically significant reduction in corneal astigmatism and corneal aberrations 6 months after surgery.¹⁷ Pterygium excision lead to a remarkable improvement in pterygium induced astigmatism.¹⁸ Adiguzel et al also documented similar finding i.e. they observed statistically significant improvement in mean BCVA postoperatively (p=0,000). Regular astigmatism, asymmetry and higher order irregularity components of fourier analysis were significantly decreased and corneal spherical power was increased at both central 3mm and 6 mm zone.¹⁹

Also we assessed corneal clarity at various follow up post pterygium excision. The improvement in corneal clarity was statistically significant (p<0.05). Ozgurhan et al also observed a clear cornea in all cases.¹⁷ Corneal bed clarity depends on presence of remnant pterygium tissue after the excision of the pterygium.

6. Conclusion

Pterygium surgery with diamond burr application for corneal smoothing, significantly improves the visual acuity, corneal keratometry and pterygium induced astigmatism.

7. Source of funding

None.

8. Conflict of interest

None.

References

1. Sihota R, Tondon R, editors. Diseases of conjunctiva. Parson's Diseases of Eye. 19th ed. India: Butterworth-Heinemann ; 2003,. Available from: <http://moscmm.org/pdf/parson%20eye.pdf>.
2. Duke-Elder SS, Cook CA. System of ophthalmology: normal and abnormal development. Kimpton ; 1963,.
3. Sm TD. Pterygium: prevalence, demography and risk factors. *Ophthalmic Epidemiol.* 1999;6(3):219. Available from: <https://www.ncbi.nlm.nih.gov/pubmed/10487976>.
4. Mccarty CA, Fu CL, Taylor HR. Epidemiology of pterygium in Victoria, Australia. *Br J Ophthalmol.* 2000;84:289–292.
5. Moran DJ, Hollows FC. Pterygium and Ultraviolet radiation: a positive correlation. *Br J Ophthalmol.* 1984;68:343–366.
6. Mohamed AE, Mahdy S, Jagdish B. Treatment of primary pterygium: Role of limbal stem cells and conjunctival autograft transplantation. *Indian J Ophthalmol.* 2009;2(1):23–26. Available from: <https://www.ncbi.nlm.nih.gov/pmc/articles/PMC3018101>.
7. Pinkerton OD, Yoshitsugi H, Singmura BE. Immunological basis for the pathogenesis of pterygium. *Am J Ophthalmol.* 1984;98:225–227.
8. Garg P, Sahai A, Shamshad MA, Tyagi L, Singhal Y, Gupta S. A comparative study of preoperative and postoperative changes in corneal astigmatism after pterygium excision by different techniques. *Indian J Ophthalmol.* 2019;67:1036–1039.
9. Yagmur M, Ozcan AA, Sari S, Ersöz TR. Visual acuity and corneal topographic changes related with pterygium surgery. *J Refract Surg.* 2005;21(2):166–170.
10. Cinal A, Yasar T, Demirok A, Topuz H ; 2001,.
11. Narasimhaiah PC, Gupta S, Khokhar S, Vanathi M, Dada T, et al. Corneal polishing after pterygium excision with motorized diamond

- burr: A randomized control trial. *Eye & contact lens*. 2015;41(5):268–272.
12. Ozgurhan EB, Necip K, Yildirim A, Bozkurt E, Demirok A. Diamond burr superficial keratectomy using mitomycin C for corneal scarring and high corneal astigmatism after pterygium excision. *Clin Ophthalmol*. 2013;7:951–954.
 13. Pavilack MA, Halpern BL. Corneal topographic changes induced by pterygia. *J Refract Surg*. 1995;11:92–95.
 14. Mikaniki E, Rasolinejad SA. Simple excision alone versus simple excision plus mitomycin C in the treatment of pterygium. *Ann Saudi Med*. 2007;27:158–160. Available from: <https://www.ncbi.nlm.nih.gov/pubmed/17568165> Pubmed.
 15. Makkar B, Agrawal I, Ahuja A, Shah HK. Comparison of preoperative and postoperative astigmatism following pterygium excision with conventional conjunctival graft and amniotic membrane graft. *Sch J Appl Med Sci*. 2015;3:147782–147782.
 16. Rao SK, Lekha T, Mukesh BN, Sitalakshmi G, Padmanabhan P. Conjunctival-limbal autografts for primary and recurrent pterygia: technique and results. *Indian J Ophthal*. 1998;46(4):203. www.ijo.in article issn=0301-4738;year=1998;volume=46;issue=4;spag.
 17. Ozgurhan EB, Kara N, Yildirim A, Alkin Z, Bozkurt E, Demirok A. Diamond burr superficial keratectomy with mitomycin C for corneal scarring and high corneal astigmatism after pterygium excision. *Clin Ophthalmol*. 2013;7.
 18. Role of pterygium excision in pterygium induced astigmatism. *JK-Pract*. 2005;12(2):91–92.
 19. Adgzel U, Yeilli M, Sari A, Kervanc T, Öz O. Effect of Pterygium surgery on corneal regular and irregular astigmatism: Evaluation with fourier analysis ;. Available from: <http://www.journalagent.com/z4/vi.asp?pdire=tjo&plng=eng&un=TOG-14632>.

Author biography

Krisna Prabha Shastry Consultant

Nupur Sharma Senior Resident

Dheerendra Singh Junior Resident

Priti Singh Assistant Professor

Kavita Kumar Professor and HOD

Cite this article: Shastry KP, Sharma N, Singh D, Singh P, Kumar K. Preoperative and postoperative evaluation of corneal astigmatism after pterygium operation using diamond Burr. *Int J Ocul Oncol Oculoplasty* 2019;5(4):171-175.