

To study the efficacy of air descemetopexy in the management of various types of descemet membrane detachment based on anterior segment – optical coherence tomography & to know the role of other gases Perfluoropropane (14% C3F8) and sulphur hexafluoride (20% SF6) in failed cases of air descemetopexy

Satya Prakash Singh¹, Mayank Srivastava², Basant Kumar Singh³, Swarnima Agrahari⁴, Santosh Kumar^{5*}

¹Professor and Director, ²Professor, ³Medical Officer, ⁴Senior Resident, ⁵Associate Professor, Dept. of Ophthalmology, Regional Institute of Ophthalmology at Govt. M. D. Eye Hospital, Allahabad, Uttar Pradesh, India

Abstract

Purpose: To study the efficacy of air descemetopexy in the management of various types of descemet membrane detachment (DMD).

Materials and Methods: After ethical committee approval, clinical data of 40 patients during the period of December 2017 to December 2018, who developed DMD after cataract surgery were analysed.

Results: Majority of patients (n= 32, 80%) had severe generalized corneal edema, n = 4 had moderated corneal edema & n = 4 had localized mild corneal edema. Only air was sufficient to reattach DMD in majority of the patients (n=36, 90% cases), only 4 patients who had very large dmd failed to attach by air. In these patients repeat descemetopexy by 14% C3F8 gas was done which lead to attachment of descemet membrane with improvement of visual acuity in 3 cases. Complications due to increase intraocular pressure were noted with these gases.

Conclusion: Air descemetopexy is a safe & efficacious option for DMD repair in most of the cases and it is associated with less postop complications.

Keywords: Descemetopexy, Descemet membrane detachment (DMD)

Introduction

Descemet's membrane detachment (DMD) is a common complication after intraocular surgery. It is the basement membrane of corneal endothelium and it helps keep the endothelial monolayer in place to maintain the corneal clarity. When it gets detached, corneal stroma loses its endothelial pump and aqueous enters the predescemetic space along a tear in the Descemet's membrane, such as that created by a corneal incision or trauma to the Descemet membrane during any ocular surgeries. DMD should be suspected when there is localized or diffuse corneal edema or haziness that persists for over two weeks with a decrease in visual acuity. If the cornea is relatively clear, the presence of DMD can be easily detected by slit-lamp biomicroscopy, but in the presence of severe corneal edema its diagnosis on slit lamp becomes difficult and anterior segment optical coherence tomography (AS-OCT) remains the best imaging tool to diagnose DMD in such cases. Several mechanisms have been proposed that leads to Descemet detachment during cataract surgery. The most common cause is inadvertent insertion of instruments between corneal stroma and Descemet's membrane, as first suggested by 'Scheie' in 1964. In 1928, soon after the advent of slit-lamp biomicroscopy, the first systematic description of DMD in the American literature was made by Bernard Samuels. Although there are reports of spontaneous resolution of DMD but with more successful outcomes from simple

pneumodescemetopexy being published, many authors now advocate early treatment, particularly for scrolled, extensive and visually impairing central DMD, to hasten visual rehabilitation and prevent wrinkling, fibrosis and shrinkage of Descemet's membrane that can occur with time and result in poor visual outcome. Considering the significance of DMD discussed earlier and taking into account the lack of any clarity in the existing literature for treatment guidelines i.e. When, How & Which type of DMD should be treated by Air, C3F8 or SF6 and regarding the efficacy of various substances used as tamponade such as 100% air, isoexpansile 14% perfluoropropane (C3F8) and 20% sulfur-hexafluoride (SF6).

We are doing our study to evaluate the effectiveness of air descemetopexy in different types and duration of DMD and why it should be preferred over other gases (14% C3F8, 20% SF6).

Aims and Objectives

1. To study the role of Anterior segment optical coherence tomography in early diagnosis of Descemet membrane detachment.
2. To know the role & failure rate of air descemetopexy.
3. To know the role of other gases perfluoropropane (14% C3F8), sulphur hexafluoride (20% SF6) in failed cases of air descemetopexy.

*Corresponding Author: Santosh Kumar, Dept. of Ophthalmology, Regional Institute of Ophthalmology at govt. M. D. Eye Hospital, Allahabad, Uttar Pradesh, India

Email: drsantosh7373@gmail.com

<http://doi.org/10.18231/ijoo.2019.032>

4. To observe the anatomical and functional outcomes of air descemetopexy in recent and old cases of DMD
5. To know the factors responsible for failed air descemetopexy.

Materials and Methods

The proposed study is conducted at Regional Institute of Ophthalmology (M.D. Eye Hospital, Dr. Katju Road, Nakhas Kona, Prayagraj, India) from December 2017 to November 2018, after taking permission from the ethical committee. A written consent from all the patients was taken.

This study included the post cataract surgery patients having descemet's membrane detachment who were treated by intracameral air descemetopexy and other gases such as 14% C3F8 or 20% SF6 in failed cases of air descemetopexy.

Examinations & Investigations done Pre & post-descemetopexy were After taking the patients demographic data, each of them were examined for Visual Acuity by Snellen's Chart, Slit-Lamp biomicroscopy (to determine the extent & depth of corneal edema), Anterior segment optical coherence tomography (Carl Zeiss Meditech, Dublin, CA, USA) & Intraocular pressure recording (non-contact tonometer (Topcon CT-80)). Post-descemetopexy follow-up visits were done at 6hrs, day 1, 1 week & 4 weeks.

Study design and sample size

This study was a prospective, cross sectional study. Total 30 eyes of 30 patients post cataract surgery were included in the study.

Selection of cases

The inclusion criteria were:

1. The patients with descemet's membrane detachment who underwent cataract surgery.
2. Planar & Non-planar both types of Descemet's membrane detachment.
3. Both recent and old cases of Descemet membrane detachment.

The exclusion criteria were:

1. The cause of descemet membrane detachment other than cataract surgery.
2. Patients with any pre-existing corneal pathology.
3. Patients with any posterior segment pathologies like optic atrophy, cystoid macular edema, retinal hemorrhage, retinal detachment etc.

Data collection

The data which were collected from the medical records of the patient included

1. Patients name, age, sex, address and contact number.
2. The eye operated, type of cataract surgery, date of cataract surgery & place of surgery were noted.
3. Pre-descemetopexy visual acuity, pre and post-descemetopexy intraocular pressure(IOP), location and extent of corneal edema or haziness on slit lamp

biomicroscopy, location & type of DMD whether planar or non planar, with scrolled edges or without scrolled edges and duration between descemetopexy and previous cataract surgery.

4. Other details noted were the type of gas used for anterior chamber injection.
5. Postoperative details at 6 hrs, day 1, 1 week, 4 weeks included improvement in corneal edema /haziness seen on slit lamp, status of DM attachment and best-corrected visual acuity.

Results

Age and sex distribution

Total 30 eyes of 30 patients were included in the study. Patients age were distributed in the range of 60-85 years and the mean age of the patients were 72.5 ± 12.5 years. Out of total 30 patients, 12 were men and 18 were females.

Types of DMD

Out of the total 30 patients, 25 patients had Planar type of DMD and only 5 had Non-planar DMD. Out of these 25 patients with planar type of DMD, 20 were without scrolled margins and 5 were with scrolled margins while all 5 non-planar DMDs were without scrolled margins.

DMD duration

We divided patients into two groups, first group with the duration of DMD ≤ 15 days (time period from the date of cataract surgery till the time of air descemetopexy.) and called it as 'recent' DMDs, second group which included patients with >15 days of DMD were called 'old' DMDs. Out of total 30 patients, 19 were recent DMDs and 11 were old.

Visual acuity

Pre - descemetopexy vision in almost all the patients were poor either FC or HM. Post -descemetopexy BCVA of 22 (73%) of the patients out of 30 showed improvement to upto 6/6-6/18, while 8 (27%) of the patients showed not much improvement in the final visual outcome and their vision remained between 6/24-HM. Fig. 4 shows the graphical representation of BCVA.

Reattachment rate (%) of DMD with Air on AS-OCT

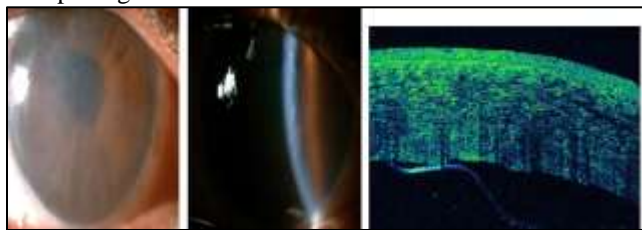
Out of total 30 patients, 26 patients (87%) i.e 25 planar DMDs, scrolled or without scrolled margins & 1 non-planar DMD showed reattachment with air descemetopexy on AS-OCT in first attempt even at 6hrs of followup and only 4 failed to reattach by air. All these 4 failed cases showed reattachment on repeat descemetopexy by using gas 14% C3F8.

On applying Fischer exact test for statistical analysis for reattachment rate of DMD by air on AS-OCT, it was found to be statistically significant i.e $p < 0.05$. No post-operative complications were noted with air but patients in whom C3F8 gas was used, almost of them complained of eyeache,

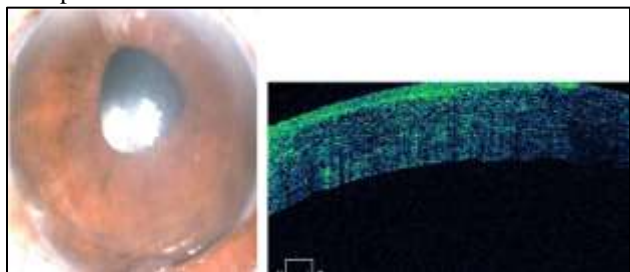
nausea, vomiting due to raised intraocular pressure and were treated with antiglaucoma drugs.

DMD

Pre op images



Post op



Discussion

Descemet's membrane detachment (DMD) is a common complication after intraocular surgery specially after cataract surgery. There is a relative paucity in the literature regarding the guidelines for the management of DMD. Some of the questions that still remain unanswered are, whether an intervention is warranted in all cases of DMD, and if required, what duration is ideal, which is the best agent to treat it with, and whether any other factors influence its final outcome.

We studied the role of AS-OCT in early diagnosis of patients with Descemet's membrane detachment and the role of only 100% air initially in various types of DMD. Other gases such as C3F8 or SF6 were used only if descemet membrane failed to reattach by air in first attempt. We also compared the anatomical & visual prognosis of air descemetopexy in recent versus old cases of DMD. In the present study, the mean age at the time of presentation was 73 years (range, 60–75 years). There were a total of 17 cases between the age group 60, 70 years, 10 between 71-80 years and 3 cases more than 80 years. The two studies in India show a relatively younger age group (Rajat Jain⁵³). It may be explained by the fact that cataract occurs early in India.

Majority of the patients were females which similar studies such as Alexander S33, Abraho da Roacha³⁷ and Rajat Jain⁵³. The occurrence of DMD was found more in the female population suggesting delayed surgical intervention. Females are presented to the hospital in the late stages of cataract, when the vision has deteriorated to a large extent or cataract associated complications have occurred. Follow up was also very difficult in female patients as they are relatively more dependent on family members to take them to the hospital.

In our study, all the patients presenting with corneal haze post cataract surgery were examined over slit lamp before going for AS-OCT. Most of the patients showed descemet's membrane detached on slit lamp which was confirmed further on AS-OCT but in the patients with severe corneal edema involving almost entire cornea DMD can be detected only on AS-OCT. Several studies have also shown the use of OCT such as Bryan J. Winn⁴⁰, Yusen Huang⁵², Rajat^{53,58}, Sonia Kothari⁶². It is useful to document and follow the postsurgical detachment of DMD and also to determine the site, configuration, and extent of the DMD, thus guiding the treatment.

DMD has been classified by Mackool and Holtz as 'Planar' if separation between Descemet membrane and corneal stroma is ≤ 1 mm and 'Non-Planar' if separation is > 1 mm on anterior segment optical coherence tomography (AS-OCT). Types of DMD which we found in our study were mostly Planar. Out of total 30 cases, 25 were planar and only 5 were non-planar. In 25 planar DMDs, 5 were with scrolled edges. and 20 without scrolled edges.

We observed in our study that the location of DMD whether involving the inferior or superior quadrant of the cornea had no effect on the reattachment rate by air descemetopexy. While in one of the study done by Namrata Sharma⁶⁵ et al in which the DMD in superior half of cornea with planar configuration alone were treated by air descemetopexy, and those with scrolled edges were managed by intracameral 14% C3F8 injection. DMDs that were in inferior half of cornea with planar or scrolled edges were managed using 14% C3F8.

In the present study we divided the patients into 2 groups based on duration of DMD. 19 patients who presented within 15 days of cataract surgery, they were classified as 'recent DMD', while those who presented after 15 days of cataract surgery were classified into 'old DMD'. We observed that the duration of DMD had no influence on the anatomical reattachment by air descemetopexy, it was similar either with recent or old DMD, but the final visual outcome was influenced by the duration of DMD. There were 8 patients out of total 30 who did not showed improvement in final visual acuity post descemetopexy and out of these 8 patients, 7 were 'old DMD' cases.

There are several reports of spontaneous DMD reattachment by Minkovitz JB⁸ and Morrison LK⁹ but delayed repair may be complicated by fibrosis, shrinkage, and wrinkling of DM, which may subsequently prevent reattachment as reported by Mackool RJ¹⁴ and Macsai²⁹.

We treated all 30 cases of Descemet's membrane detachment with intracameral injection of air in the first attempt. Air was used in planar and non-planar both types of DMD, whether with scrolled margins or without scrolled margins. We found that out of 30 cases, 26(87%) cases showed successful reattachment by air only within 6 hrs post-descemetopexy, but 4 cases failed to attach by air in first attempt and they were scheduled for repeat descemetopexy by 14% C3F8 gas or 20% SF6 depending on our senior surgeon's choice. Though these gases lead to

reattachment of descemet's membrane in failed cases but we observed complications such as vomiting, severe eyeache and raised intraocular pressure in 3 cases out of 4.

Anterior chamber injection of gas as the primary management strategy has been well described by Makley TA Jr2. It can hasten the absorption of corneal edema and, thus, visual recovery.

BCVA we found that out of the 30 patients 22 (73%) patients had final visual acuity between 6/6-6/18 whereas 8 (27%) patients had final visual acuity between 6/24-FC. The BCVA assessment was done after 1 day, 1 week and 1 month of descemetopexy. 8 patients in whom final BCVA doesn't so improvement, 7 of them were 'old DMD' & only 1 was 'recent DMD'. 5 were Non-planar type & 3 were of Planar type.

The BCVA was found to be better in eyes who had presented with localised corneal edema and in patients with a good follow up.

4 out of 30 patients required repeat intervention in our study, All these 4 patients had Non-Planar extensive DMDs, these failed to reattach primarily by air only as it does not last longer and gets absorbed within 3 days. These large Non-Planar DMD required gases which lasts longer, so repeat descemetopexy by 14% C3F8 gas was done.

Attachment was seen by 14% C3F8 in all these 4 cases, 1 week post repeat descemetopexy.

Conclusion

So, we conclude our study by recommending, the use of only Air for almost every type & duration of DMD for descemetopexy, as the anatomical and visual both outcomes were found significant and isoexpansile gases such as 14% C3F8 or 20% SF6 should be used only when air descemetopexy fails to reattach, such as in cases with extensive non-planar DMDs. Post-descemetopexy complications were also high with them as compared to air, so air is a safe, easy, cheap and effective option for descemetopexy.

Source of Funding

None.

Conflict of Interest

None.

References

- Jaffe NS. Cataract surgery and its complications. In: Jaffe NS, editor. 4th ed. St. Louis: Mosby, 1984:627-36.
- Makley TA Jr, Keates RH. Detachment of Descemet's membrane (an early complication of cataract surgery). *Ophthalmic Surg* 1980;11:189-91.
- Samuels B. Detachment of Descemet's membrane. *Trans Am Ophthalmol Soc* 1928;26:427-37.
- Scheie HG. Stripping of Descemet's membrane in cataract extraction. *Trans Am Ophthalmol Soc* 1964;62:140-52.
- Mulhern M, Barry P, Condon P. A case of Descemet's membrane detachment during phacoemulsification surgery [letter]. *Br J Ophthalmol* 1996;80:185-6.
- Anderson CJ. Gonioscopy in no-stitch cataract incisions. *J Cataract Refract Surg* 1993;19:620-1.
- Monroe WM. Gonioscopy after cataract extraction. *South Med J* 1971;64:1122-4.
- Minkovitz JB, Schrenk LC, Pepose JS. Spontaneous resolution of an extensive detachment of Descemet's membrane following phacoemulsification. *Arch Ophthalmol* 1994;112:551-2.
- Morrison LK, Talley TW, Waltman SR. Spontaneous detachment of Descemet's membrane. Case report and literature review. *Cornea* 1989;8:303-5.
- Bergsma DR Jr, McCaa CS. Extensive detachment of Descemet membrane after holmium laser sclerostomy. *Ophthalmol* 1996;103:678-80.
- Macasai MS. Total detachment of Descemet's membrane after small-incision cataract extraction letter. *Am J Ophthalmol* 1992;114:365-6.
- Al-Mezaine HS. Descemet's membrane detachment after cataract extraction surgery. *Int Ophthalmol* 2010;30:391-6.
- Potter J, Zalatio N. Descemet's membrane detachment after cataract extraction. *Optometry* 2005;76:720-4.
- Mackool RJ, Holtz SJ. Descemet membrane detachment. *Arch Ophthalmol* 1977;95:459-63.
- Iradier MT, Moreono E. Late spontaneous resolution of a massive detachment of Descemet's membrane after phacoemulsification. *JCRS* 2002;28:1071-3.
- Hoover DL, Giangiaco J, Benson RL. Descemet's membrane detachment by sodium hyaluronate. *Arch Ophthalmol* 1985;103:805-8.
- Jacob S, Agarwal A. Relaxing descemetotomy relieves stress forces in taut Descemet's membrane detachment. *Ocular surgery news*. U.S. EDITION October 10, 2010
- Marcon AS, Rapuano CJ, Jones MR, Laibson PR, Cohen, EJ. Descemet's membrane detachment after cataract surgery management and outcome. *Ophthalmol* 2002;109:2325-30.
- Morinelli EN, Najac RD, Speaker MG, Tello C, Liebermann JM, Ritch R et al. Repair of Descemet's membrane detachment with the assistance of intraoperative ultrasound biomicroscopy. *Am J Ophthalmol* 1996;121(6):718-20
- Radhakrishnan S, Goldsmith J, Huang D; et al. Comparison of optical coherence tomography and ultrasound biomicroscopy for detection of narrow anterior chamber angles. *Arch Ophthalmol* 2005;123(8):1053-9.
- V Menezo, Y F Choong, N R Hawksworth. Reattachment of extensive Descemet's membrane detachment following uneventful phacoemulsification surgery. *Eye* 2002;16:786-8.
- Lee DA, Wilson MR, Yoshizumi MO, Hall M. The ocular effects of gases when injected into the anterior chamber of rabbit eyes. *Arch Ophthalmol* 1991;109:571-5.
- P. M. Jacobs, J. M. Twomey, P. K. Leaver. Behaviour of Intraocular References 82 Gases. *Eye* 1988;2:660-3.
- Humayun MS, Yeo JH, Koski WS, Michels RG. The rate of sulphur hexafluoride escape from plastic syringe. *Arch Ophthalmol* 1989;107(6):853-4.
- Pieramici D, Green WR, Stark WJ. Stripping of Descemet's membrane: a clinicopathologic correlation. *Ophthalmic Surg* 1994;25(4):226-31.
- Mark J Walland. Repair of Descemet's membrane detachment after intraocular surgery. *J Cataract Refractive Surg* 1995;S0886-3350(13)80127-7
- M Mulhern, P Barry. A case of Descemet's membrane detachment during phacoemulsification surgery. *Br J Ophthalmol* 1996;80:185-8.
- Muneera A. Mahmood, Klaus D. Teichmann, Karim F. Tomey. Detachment of Descemet's membrane. *J Cataract Refractive Surg* 1998;24(6):827-33.

29. Macsai MS, Gainer KM, Chisolm L. Repair of Descemet's membrane detachment with perfluoropropane(C3F8). *Cornea* 1998;17(2):129-34.
30. C Y W Khng, L W Voon, K T Yeo. Causes and Management of References 83 Descemet's Membrane Detachment Associated with Cataract Surgery—Not Always a Benign Problem. *Ann Acad Med Singapore* 2001;30:532-5.
31. D. Pahor and B. Gracner. Surgical Repair of Descemet's Membrane Detachment. *Coll. Antropol.* 25 Suppl. (2001) 13–16
32. V Menezo. Reattachment of extensive Descemet's membrane detachment following uneventful phacoemulsification surgery. *Eye* 2002;16:786–8.
33. Alexandre S. Marcon, Christopher J. Rapuano, Matthew R. Jones. Descemet's Membrane Detachment after Cataract Surgery: Management and Outcome. *Ophthalmol* 2002;109:2325–30.
34. Ravinet, E, Tritten, J, J, Roy S. Descemet Membrane Detachment After Nonpenetrating Filtering Surgery. *J Glaucoma* 2002;11(3):244-52.
35. Ming-Cheng Tai, Feng-Shuen Yieh, Ping-I Chou. Repair of Near Total Descemet's Membrane Detachment with Intracameral Injection of 20% Sulfur Hexafluoride Gas. *J Med Sci* 2002;22(5): 231-234
36. In Sik Kim, Jung Chul Shin, Chan Yeong Im. Three Cases of Descemet's Membrane Detachment after Cataract Surgery. *Yonsei Med J* 2005;46(5):719-23.
37. Abrahao da Rocha Lucena, David da Rocha Lucena, Emília Lucena Macedo. C3F8 use in Descemet detachment after cataract surgery. *Arq Bras Oftalmol* 2006;69(3):339-43.
38. Ali A, Ahmed T, Ahmed T. Corneal problems during and after phacoemulsification by beginner phacoemulsification surgeon. *Pak J Med Sci* 2007;23(3):401-4.
39. Briesen S, Roberts H. Repair of Descemet's Membrane Detachment with air. *East Afr J Ophthalmol* 2007.
40. Bryan J. Winn, Shan C. Lin, Michael R. Hee. Repair of Descemet Membrane Detachments With the Assistance of Anterior Segment Optical Coherence Tomography. *Arch Ophthalmol* 2008;126(5):730-2.
41. Sevillano C, Viso E. Descemet's membrane detachment as a complication of cataract surgery. *Arch Soc Esp Oftalmol* 2008;83:549-52.
42. Saemah Nuzhat Zafar, Ayesha Khan. Detachment of Descemet's Membrane Following Stromal Hydration in Phacoemulsification Surgery. *J Col Physicians Surg Pak* 2008;18(3):179-80.
43. Imran Jivraj, Wai-Ching Lam, Varun Chaudhary. Repair of Prolonged Descemet's Membrane Detachments with Intracameral Injection of References 85 Long-Acting Gases. *UTMJ* 2009;86(2).
44. Akin T, Ayata A, Aykan U, Bilge AH. Intracameral Perfluoropropane (C3F8) Gas in the Repair of Extensive Descemet's Membrane Detachment During Phacoemulsification Surgery. *Ophthalmic Surgery, Lasers & Imaging: the Official Journal of the International Society for Imaging in the Eye* 2010:13.
45. Mannan, Rashim, Pruthi, Archana. Descemet Membrane Detachment During Foldable Intraocular Lens Implantation. *Eye Contact Lens: Sci Clin Pract* 2011;37(2):106-8.
46. Landry H, Aminian A, Hoffart L. Corneal Endothelial Toxicity of Air and SF6. *Invest Ophthalmol Vis Sci* 2011;52:2279–86
47. Ghaffariyeh A, Honarpisheh N, Chamacham T. Supra-Descemet's Fluid Drainage with Simultaneous Air Injection: An Alternative Treatment for Descemet's Membrane Detachment. *Middle East Afr J Ophthalmol* 2011;18(2):189–91.
48. Perez-Roca F, Legaza SS, Lopez JFR. Treatment of Descemet's membrane detachment after cataract surgery with 20% SF6. *J Emmetropia* 2011;2:49-50.
49. Sunita Chaurasia, Muralidhar Ramappa, Prashant Garg. Outcomes of air descemetopexy for Descemet membrane detachment after cataract References 86 surgery. *J Cataract Refractive Surg* 2012;38(7):1134–9.
50. Aravind Haripriya, David F. Chang, Mascarenhas Reena. Complication rates of phacoemulsification and manual small-incision cataract surgery at Aravind Eye Hospital. *J Cataract Refract Surg* 2012;38:1360–69
51. Kumar MA, Vaithianathan V. Descemet's membrane detachment managed with perfluro-n-octane liquid. *Indian J Ophthalmol* 2012;60:71-2.
52. Yusen Huang, Jie Lan, Xinjie Zang. Optical coherence tomography guided intracameral air injection for treatment of extensive Descemet's membrane detachment. *Br J Ophthalmol* 2012;0:1–2.
53. Rajat Jain, Somasheila I. Murthy, Sayan Basu. Anatomic and Visual Outcomes of Descemetopexy in Post-Cataract Surgery Descemet's Membrane Detachment. *Ophthalmol* 2013;120:1366–72.
54. Ti, Seng-Ei, Chee, Soon-Phaik, Tan, Donald T. H. Descemet Membrane Detachment After Phacoemulsification Surgery: Risk Factors and Success of Air Bubble Tamponade. *Cornea* 2013;32(4):454–9.
55. Xixia Ding, Pingjun Chang, Giacomo Savini. Clear Corneal Incision Architecture Imaging after Torsional Phacoemulsification of Hard Nuclear Cataract through a 2.2 mm and a 3.0 mm Large Tunnel. *J Clin Exp Ophthalmol* 2013;4:3.
56. Gujar P, Bhasin P, Bhasin P. Bilateral Descemet's membrane detachment after uneventful phacoemulsification in a case of diabetes mellitus. *Indian J Ophthalmol* 2013;61:28-9.
57. Asif GH, Kadri WM. Descemet's Membrane Detachment Repair with Sodium Hyaluronate after Phacoemulsification. *Pak J Ophthalmol* 2013;29(2).
58. Jain R and Mohan N. Outcomes of Repeat Descemetopexy in Post-Cataract Surgery Descemet Membrane Detachment. *Am J Ophthalmol* 2014;157:571–5.
59. Malhotra R, Garg P, Singh L. Comparison of small incision cataract surgery with conventional extra capsular cataract surgery: an evaluation from resource poor setting in India. *Int J Clin Trials* 2014;1(1):10-3.
60. Veerendra V.Godbole, Swapnagandha S. Halikar. Air Descemetopexy as a Treatment of Iatrogenic Descemet's Membrane Detachment. *IJSR* 2014;3(7).
61. Ximenes KF, Silva JV. The role of Descemet's membrane in the pathogeny of corneal edema following anterior segment surgery. *Rev Bras Oftalmol* 2014;73(5):262-8.
62. Kothari S, Kothari K, Parikh RS. Role of anterior segment optical coherence tomogram in Descemet's membrane detachment. *Indian J Ophthalmol* 2011;59:303-5.
63. Gagatay HH, Ekinci M, Koban Y. Evaluation of Descemet's Membrane Detachment Using Anterior Segment Optical Coherence Tomography. *Turk J Ophthalmol* 2014;44:407-9.
64. Su-Ho Lim. Clinical Applications of Anterior Segment Optical Coherence Tomography. *J Ophthalmol* 2015. Article ID 605729
65. Sharma N, Gupta S, Maharana P. Anterior Segment Optical Coherence Tomography–Guided Management Algorithm for Descemet Membrane Detachment After Intraocular Surgery. *Cornea* 2015;34:1170-4.
66. Garg J, Mathur U, Acharya MC, Chauhan L. Outcomes of Descemetopexy with Isoexpansile Perfluoropropane after Cataract Surgery. *J Ophthalmic Vis Res* 2016;11(2):168-73.
67. Annamalai Odayappan, Narayana Shivananda, Seema Ramakrishnan. A retrospective study on the incidence of

postcataract surgery Descemet's membrane detachment and outcome of air descemetopexy. *Br J Ophth*

How to cite this article: Singh SP, Srivastava M, Singh BK, Agrahari S, Kumar S. To study the efficacy of air descemetopexy in the management of various types of descemet membrane detachment based on anterior segment – optical coherence tomography & to know the role of other gases Perfluoropropane (14% C3F8) and sulphur hexafluoride (20% SF6) in failed cases of air descemetopexy, *Int J Ocul Oncol Oculoplasty* 2019;5(3):124-9.