

Bilateral Vogt-Koyanagi-Harada disease with poliosis (a rare initial presentation)

Vinay Gupta¹, Kalpana Sharma^{2*}, Pramod Guleria³, RL Sharma⁴

¹Assistant Professor, ^{2,3}Medical Officer, ⁴Professor and HOD, Dept. of Ophthalmology, Indira Gandhi Medical College, Shimla, Himachal Pradesh, India

***Corresponding Author: Kalpana Sharma**

Email: doctorkalpana.84@gmail.com

Abstract

Vogt Koyanagi Harada is a multisystem, granulomatous autoimmune disease with delayed onset of cutaneous manifestation. The case of an adolescent male with bilateral decreased vision is presented. The patient was diagnosed Vogt-Koyanagi-Harada (VKH) syndrome, with extraocular systemic manifestations in the form of sensory neural hearing loss (SNHL) and greying of scalp hairs at initial presentation which is very rare as cutaneous involvement usually occurs 2 to 3 months after the onset of disease. The syndrome may result in permanent visual loss but prompt treatment with corticosteroid therapy can restore vision. Therefore early ophthalmologic consultation must be sought.

Keywords: Vogt-Koyanagi-Harada, Sensory neural hearing loss, Greying hairs.

Introduction

Vogt-Koyanagi-Harada syndrome (VKH) is a bilateral granulomatous panuveitis first reported by Vogt in 1906 associated with cutaneous, neurological and auditory manifestations.^{1,2} In 1929, Koyanagi described the similar cases after which the entity was named as Vogt-Koyanagi syndrome.³ It is characterised by panuveitis, serous retinal detachments, diffuse choroidal swelling and optic disc hyperemia. It may be associated with neurologic and later in course of disease dermatologic manifestations (vitiligo and poliosis). There are 4 stages of VKH disease-prodromal, acute uveitis, convalescent and chronic/recurrent uveitis:

Prodromal Phase

It consists of neurological symptoms of headache, fever, tinnitus followed by blurring of vision 1 or 2 days later.

Uveitic Phase

It consists of acute phase comprising bilateral exudative retinal detachment, vitritis and disc hyperemia.

Chronic Phase

It comprises depigmentation of inferior fundus (sunset glow appearance), Sugiura sign (depigmentation of limbus), Dalen-Fuchs nodules (epitheloid and macrophages with melanin granules)

Recurrent Phase

It consists of anterior uveitis and subretinal neovascularisation. Systemic involvement consists of auditory signs (tinnitus, vertigo) and neurological signs (fever, headache, cerebrospinal fluid pleocytosis) which occur at the onset of the disease. The dermatologic signs of poliosis and vitiligo occur 2-3 months after the onset of VKH.⁴ The ocular manifestations are usually bilateral, but an asymmetric presentation may be there.⁵⁻⁸ In the present case, we describe a bilateral case of VKH disease with hearing loss in left ear and greying of scalp hairs at initial presentation only.

Case Presentation

A 28years old male presented with decrease vision in the both eyes (BE) for 8 days with prior 2weeks frontal

headache. The vision loss started in left eye a day before right eye. There was no history of penetrating ocular trauma or surgery. He had greying of hairs on his head for last two years. (Fig. 1)



Fig. 1: Greying of hairs

There was history of impaired hearing in left ear since childhood. Best-corrected visual acuity (BCVA) was 1/60 in both eyes. His light reflexes (pupillary), intraocular pressure, anterior segment examinations and slit-lamp biomicroscopy were normal in both eyes. On fundus examination, right eye showed hyperemia of optic disc, with exudative retinal detachment and left eye showed optic disc hyperemia, with peripapillary hemorrhage nasal to optic disc (Fig. 2) and posterior pole exudative retinal detachment.

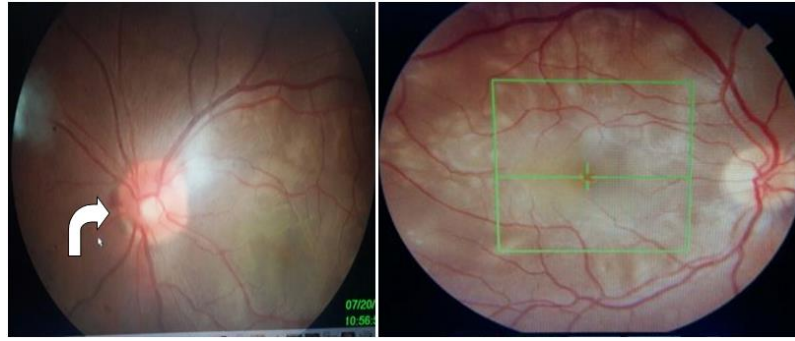


Fig. 2: Fundus photograph LE showing Papillitis with arrow showing peripapillary haemorrhage nasally and BE showing serous detachments

Optical coherence tomography (OCT) showed multiple serous retinal detachment in macula (Fig. 3) with thickening of the posterior choroid in both eyes.

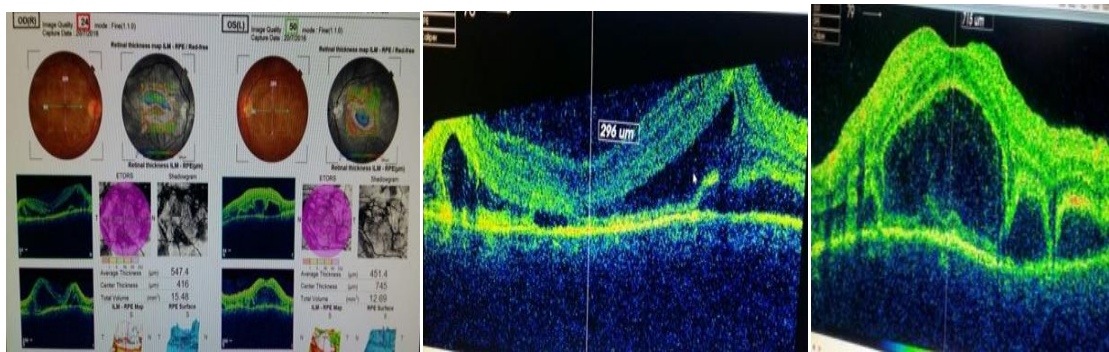


Fig. 3: OCT showing bilateral serous detachments

A fundus fluorescein angiography (FA) showed focal areas of delayed choroidal perfusion multifocal areas of pinpoint leakage with late pooling into areas of serous detachment and late leakage which were typical of Vogt-Koyanagi-Harada (VKH) disease. On ENT check up he was found to have profound sensory neural hearing loss (SNHL) in left ear on PTA (Pure tone audiometry).

Diagnosis of VKH was made and the patient was put on Injection Methyl prednisolone 1gram for three days and received systemic steroids. Bilateral BCVA started to improve after first injection of methyl prednisolone only and was 6/60 in both eyes after three injections. There was immediate relief in his headache allegedly after first dose of Methyl prednisolone. Patient was put on systemic steroids in the form of oral Prednisolone 1.5 mg/kg body weight with omeprazole 20 mg for 08 weeks. Four weeks after the beginning of oral steroid therapy, the patient was put on 7.5 mg of Methotrexate per week for 8 weeks till the time serous detachments did not settle. His BE BCVA improved to 6/6 in 8 weeks only with complete absorption of subretinal fluid and normal retinal and choroidal thickness on OCT in bilateral eyes. After 8 weeks oral Prednisolone was tapered off slowly by 05 mg per week for 8 months and methotrexate was continued up to 15mg/week for about one year. The patient is continuously on follow up with no recurrent attack till now.

Discussion

Vogt Koyanagi Harada disease comprises granulomatous uveitis with exudative retinal detachment and extraocular manifestation with bilateral ocular involvement essential for its diagnostic criteria however rarely it may be unilateral or asymmetric.⁹ The diagnosis of VKH disease is clinically and angiographically based. In acute stage of the disease there are hypofluorescent dots corresponding to multifocal areas of inflammation in choroid and altered retinal pigment epithelium with multiple areas of leakage and pooling in subretinal space in late phase.

Differential diagnosis includes other causes of posterior/panuveitis, such as:

1. Sympathetic ophthalmitis which is differentiated by history of trauma (surgical or accidental),
2. Uveal effusion syndrome –It involves both eyes although not simultaneous with no intraocular inflammation,
3. Posterior scleritis-It affects females more than males and on B-scan reveals “T” sign corresponding to thickening of coats of globe posteriorly and retrobulbar edema.

Other differential diagnosis are primary intraocular lymphoma, uveal, lymphoid infiltration, acute posterior multifocal placoid pigment epitheliopathy and sarcoidosis which maybe differentiated from by a complete history, systemic and physical examination associated with a laboratory evaluation.²

The treatment involves use of systemic steroids with slow tapering in order to control active inflammation, to prevent recurrence of inflammatory episodes and to ameliorate extra ocular manifestations.⁹ Recent studies have supported combination of corticosteroid with immunosuppressive agents as first line which decreases the development of late complications, prevents recurrence, improves long-term vision and facilitates rapid steroid tapering.⁹⁻¹¹ In the present case the patient received systemic corticosteroid therapy for 8 weeks at dose of 1.5mg/kg /BW which was tapered off in 8 months at 5 mg per week and methotrexate for one year under medical specialist supervision.

Irrespective of the form of disease, three conditions are essential for the diagnosis of VKH: (1) no past history of penetrating ocular trauma (surgical or accidental); (2) the possibility of any other ocular disease must be ruled out; and (3) bilateral ocular involvement. In the present case, the blood investigations were negative and the systemic examination was normal which excluded the other possible diagnoses. There were no dermatologic changes. The frontal headache before the onset of ocular manifestations suggested prodromal stage. The greying of eyelashes and scalp hair of the patient with Vogt-Koyanagi-Harada Disease is seen during the chronic phase about 2-3 months of onset (4), but in our patient there was greying of scalp hairs as initial presentation only.

Conflict of Interest: None.

References

1. Moorthy RS, Inomata H, Rao NA. Vogt-Koyanagi-Harada syndrome. *Surv Ophthalmol* 1995;39:265-92.
2. Vogt A. Frühzeitiges Ergrauen der Zilien und Bemerkungen über den sogenannten plötzlichen Eintritt dieser Veränderung. *Klin Monatsbl Augenheilk* 1906;44:228-42.
3. Koyanagi Y. Dysakusis, Alopecia und Poliosis bei schwerer Uveitis nicht traumatischen Ursprungs. *Klin Monatsbl Augenheilk* 1929;82:194-211.
4. Inomata H. Vogt-Koyanagi-Harada Disease. In: Yanof f M, Duker JS, editors. *Ophthalmology*. 2nd ed. Missouri: Mosby; 2004,pp. 1196-98.
5. Usui Y, Goto H, Sakai J, Takeuchi M, Usui M, Rao NA, et al. Presumed Vogt Koyanagi Harada disease with unilateral ocular involvement: report of three cases. *Graefes Arch Clin Exp Ophthalmol* 2009;247:1127-32.
6. Agrawal A, Biswas J. Unilateral Vogt-Koyanagi-Harada disease: report of two cases. *Middle East Afr J Ophthalmol* 2011;18:82-4.
7. Kouda N, Sasaki H, Harada S, Yamada Y, Takahashi N, Sasaki K, et al. Early manifestation of Vogt Koyanagi Harada disease as unilateral posterior scleritis. *Jpn J Ophthalmol* 2002;46:590-3.
8. Roe RH, Rathinam SR, Wong RW, McDonald HR, Jumper JM, Cunningham ET., Jr Delayed fellow eye involvement in patients with Vogt-Koyanagi-Harada disease. *Br J Ophthalmol* 2009;93:701-2.
9. Cunningham ET, Jr, Rathinam SR, Tugal-Tutkun I, Muccioli C, Zierhut M. Vogt-Koyanagi-Harada disease. *Ocul Immunol Inflamm* 2014;22:249-52.
10. Paredes I, Ahmed M, Foster CS. Immunomodulatory therapy for Vogt-Koyanagi-Harada patients as first-line therapy. *Ocul Immunol Inflamm* 2006;14:87-90.
11. Cuchacovich M, Solanes F, Díaz G. Comparison of the clinical efficacy of two different immunosuppressive regimens in patients with chronic Vogt-Koyanagi-Harada disease. *Ocul Immunol Inflamm* 2010;18:200-7.

How to cite this article: Gupta V, Sharma K, Guleria P, RL Sharma. Bilateral Vogt-Koyanagi-Harada disease with poliosis (a rare initial presentation). *Int J Ocul Oncol Oculoplasty* 2019;5(2):94-6.