

Comparative analysis between blood clot conjunctival autografting (CAG) versus amniotic membrane (AMG) grafting on pterygium excision surgery

Pankaj Soni^{1*}, Suroma Joysmine Marndi², Ashutosh Kumar Singh³

¹Associate Professor, ²Senior Resident, ³Junior Resident, Dept. of Ophthalmology, BRD Medical College, Gorakhpur, Uttar Pradesh, India

***Corresponding Author: Pankaj Soni**

Email: joysmine1990@gmail.com

Abstract

Objective: To compare the efficacy and analyse between autologous blood clot limbal conjunctival autograft (CAG) with amniotic membrane grafting (AMG) on pterygium excision surgery.

Materials and Methods: This study included 62 patients (18-70 years) with primary pterygium attending OPD in Dept. of Ophthalmology in our tertiary care hospital. It is a 1 year observational study (February 2018 to January 2019) with 6 months period of observation in post-operative patients of CAG and AMG groups in primary pterygium excision surgery and the results have been compared in the study.

Results: The mean age group being 42 ± 7 years of total 62 patients with 54 male patients and 8 female patients with no drop out throughout the study. 38 patients were randomly selected for CAG group rest 24 patients were selected into AMG group. In 6 months of post-operative observation 2 (3.23%) patients in CAG group and 6 (9.68%) patients in AMG group had recurrence of pterygium while 1 patient had symblepharon in the intermediate period of observation in CAG group.

Conclusion: The recurrence of pterygium (≥ 1 mm) was more in amniotic membrane graft patient compared to autologous blood clot tenon free conjunctival autograft. Autologous blood clot conjunctival graft required more surgical skills, proper techniques and took more surgical time as compared amniotic membrane grafting, but BCAG more economical compared to AMG. Both CAG & AMG appears to be safe for excision of pterygium with fewer recurrence of pterygium.

Keywords: Pterygium, Recurrence, Autologous blood clot conjunctival autograft, Amniotic membrane graft.

Introduction

Pterygium is a wing-shaped fibrovascular growth that extends from the conjunctiva onto the nasal, temporal or both (double pterygium) aspect of the cornea. The major contributor to formation of pterygium has been considered to be exposure to ultraviolet (UV) light. Early pterygium is usually asymptomatic. The main concern of a patient with pterygium is cosmetic disfigurement, while other being recurrent inflammation, visual impairment (due to induced astigmatism/ altered tear film layer), difficulty to wear contact lens and rarely diplopia from motility restriction by tenon capsule contraction. These were the indication for pterygium excision surgery.

Pathogenesis – recent evidence implicates anti-apoptotic mechanism, cytokines, growth factors; extracellular matrix modulators, genetic factors and viral infections among other possible causative factor other than exposure to UV light.

Excision surgery is the only known treatment for pterygium; however no technique has entirely prevented recurrence of pterygium, which is more pronounced in malignant pterygium than in a primary pterygium. The most common technique can be: 1) bare sclera excision 2) tissue grafting- conjunctival graft or amniotic membrane graft alone or grafting combined with mitomycin C (MMC). It has been reported that the risk of recurrence is about 25-45% in cases with simple bare sclera technique¹ in certain population where the risk of recurrence is reduced by 5-15% with pterygium excision with tissue grafting. The higher rate of the recurrence have been explained by the theory of corneal limbal stem cell deficiency. Spaeth et al² in a study explained the modification of the surgical technique using

conjunctival autograft for covering bare sclera after pterygium excision, which resulted in decrease recurrence rate. Kenyon et al³ introduced the surgical technique using conjunctival autograft in the management of primary and recurrent pterygium. Tissue grafting is more time consuming and more difficult compared to bare sclera technique. Use of suture is an older technique with maximum surgical time and post-operative discomfort. Suture free methods- tissue adhesives fibrin glue or autologous blood clot method are now widely used surgical techniques with better outcome in pterygium surgeries. Autologous blood clot with tissue grafting is an effective alternative which is easily available, economical compared to fibrin glue with less surgical time and post-operative discomfort. Suture free tissue grafting were associated with graft reposition/loss, bleb formation, granuloma (tenon's), rise in IOP, corneoscleral dellen formation, epithelial inclusion cyst. AMG had advantage over CAG in cases with advanced (grade IV) pterygium, bilateral heads or those who might need glaucoma surgery later. Adjunctive therapies along with pterygia excision- Beta irradiation, 5- fluorouracil (5-FU) and MMC has been recommended due to their antifibrotic and angiogenic properties. Use of MMC has higher efficacy in reducing recurrency but it can be associated with vision threatening complications, including delayed conjunctival epithelisation leading to poor wound healing, scleral thinning and ulceration; there are evidence of increased complications with increased concentration and duration of exposure to MMC. Conjunctival/limbal conjunctival autograft was superior to amniotic membrane graft in reducing the rate of pterygium recurrence.

Aim of the Study

This study aims to compare the outcome of pterygium surgical excision between autologous blood clot conjunctival autograft (CAG) versus amniotic membrane graft (AMG).

Materials and Methods

This is an observational study included 62 patients (18-70 years) with primary pterygium undergone pterygium surgery in our tertiary care hospital. There were 54 male and 8 female patients included in the study. The mean age in the study was 42 ± 7 years (18-70 years). There was random categorization of patients into two groups where 38 patients had undergone blood clot conjunctival autograft (grouped as CAG) and 24 patients had undergone pterygium excision with Amniotic membrane graft (grouped as AMG). 6 months period of observation in post-operative patients of CAG and AMG groups in primary pterygium excision surgery and the results have been compared in the study.

Inclusion Criteria

1. Patients with primary pterygium (>2mm) involving any eye or both eye
2. Pterygium of grade 1 to grade 4
3. Patient between the age group of 18-70 years

Exclusion Criteria

1. Presence of double pterygium
2. Recurrent pterygium
3. Pseudopterygium
4. Patients with history of scleritis, ocular surface disorders such as chemical injuries, vernal/allergic keratoconjunctivitis, symblepharon, Steven Johnson syndrome, pemphigus vulgaris, pemphigus foliaceus.
5. Patients with diabetes mellitus, collagen vascular disease, bleeding disorders, pregnancy.
6. Patient with a known history of glaucoma or patient requiring future/ have undergone glaucoma filtration surgery.

An informed consent was taken from all patients included in the study and underwent the following pre-operative evaluation:

1. Pre-operative visual acuity assessment with UCVA and BCVA recordings was done.
2. Baseline intraocular pressure (IOP) measurement by Goldmann applanation tonometry.
3. Slit lamp biomicroscopy
4. Fundus examination and
5. Photographic documentation of pterygium.

All the surgeries were done by a single surgeon. The operative time was documented by recorded video during the whole surgery.

Pre-operative use of antibiotic 0.5% moxifloxacin eyedrop instillation was started 24 hours prior to the pterygium surgery in all cases.

Method in CAG Group

Peribulbar anaesthetic (2% lignocaine)

Taking all aseptic methods, betadine cleaning and use of lid speculum.

Superior rectus bridle suture.

The pterygium head and neck were avulsed with an iris repositor and the pterygium tissue and excess of conjunctiva was excised Fig. 1.

In case of excessive bleeding tamponade with cotton tipped applicator was done to check haemorrhage, saline irrigation and cautery was completely avoided in both CAG and AMG groups (all cases).

The bare sclera was measured with a Castroviejo caliper. With the help of Vannas scissors 0.5 mm oversized free conjunctival graft was taken from the superior limbus. Care was taken to prevent button holing of conjunctival tissue and tenon to be avoid in the graft. Thereby prior obtaining free conjunctival graft 0.5 ml of lignocaine was injected subconjunctivally to created subconjunctival space between conjunctiva and tenon.

The conjunctival graft was laid unto the bare sclera so that the limbal side of the graft lies on the limbus, thus ensuring limbal to limbal orientation.

In case of lack of clot formation at recipient site the episcleral vessels were punctured to create bleeding.

Eyedrop 0.5% moxifloxacin was instilled and 24 hours eye patching was done.

Method in AMG Group

Pre-operative peribulbar anaesthesia to pterygium excision and creating a bare sclera was performed similarly as described in CAG group except there was no requirement for applying superior rectus bridle suture.

Amniotic membrane graft oversizing the bare sclera was applied and sutured with 10-0 polyamide monofilament sutures at four corners to prevent graft repositioning. Similarly eye drop 0.5% moxifloxacin was instilled and 24 hours eye patching was done, Fig. 2. Followed by suture removal after 2 weeks of post-operative period.

During both of the procedure care was taken to prevent corneal desiccation by applying viscoelastics onto the corneal surface.

In both of the groups, on next day of surgery the eye was examined for graft adherence under slit lamp, or any other complications.

Post-operatively the patients were on topical 0.5% Moxifloxacin eye drop in QID dose in both groups followed by topical 0.5% loteprednol ebonate in QID dose for another 2 weeks thereafter tapered in another 4 weeks. Topical 1% carboxymethylcellulose in QID dose for 6 weeks. Patients were observed and followed up on post-operative day 1, 3, 7, 14, 30, 120 and 180 (i.e. 6 months).

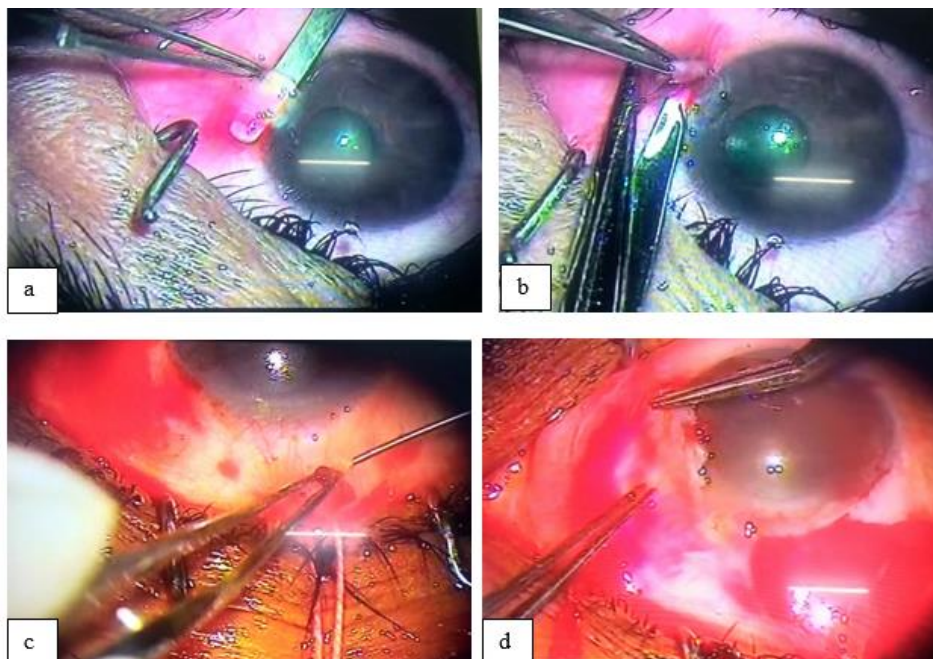


Fig. 1: Procedure performed in CAG group patients; **a):** separation of pterygium tissue at its neck; **b):** excision of granulation tissue with excess conjunctival tissue resection; **c):** separation of conjunctiva from tenon by injecting 0.5% lignocaine subconjunctival space prior harvesting the CAG; **d):** orientation of conjunctival graft in limbus to limbus orientation

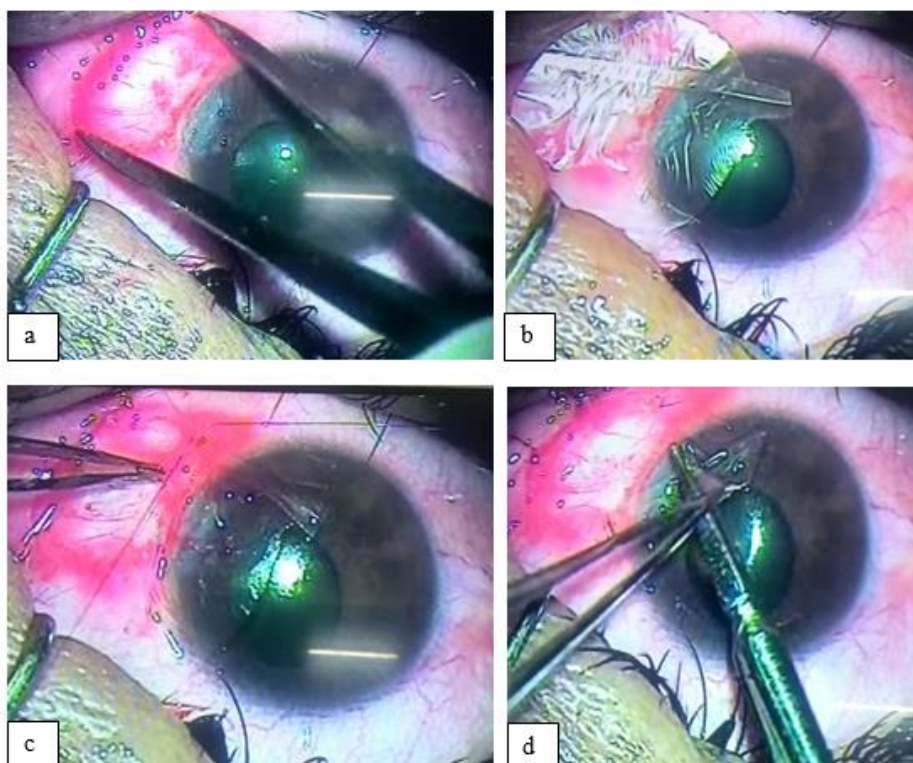


Fig. 2: Procedure performed in AMG group patients **a):** Measuring bare sclera with Castroviejo caliper **b):** Amniotic membrane graft **c):** Suturing of AMG **d):** Resecting excess of AMG.

Observation

Table 1: Grading of pterygium

Grading	Description of pterygium tissue
Grade 0	There is no pterygium tissue present
Grade 1 (trace)	Pterygium tissue is translucent, similar to conjunctiva Episcleral vessels under the body of pterygium are easily visible. Minimal dilated vessels.
Grade 2 (mild)	Pterygium tissue is pink in colour Episcleral vessels under the body of pterygium are distinguishable. Dilated vessels with increased density.
Grade 3 (moderate)	Pterygium tissue is red in colour Episcleral vessels under the body of pterygium are not distinguishable. Significant tortuous and engorged vessels.
Grade 4 (severe)	Pterygium tissue is deep bright diffused red in colour, very thick pterygium tissue. Episcleral vessels under the body of pterygium are totally obscured. Dense network of engorged vessels.

Table 2: Distribution of patients into following group in relation to grade of pterygium

Pterygium	CAG	AMG	Total/percentile
Grade 1	14	5	19 (30.41%)
Grade 2	16	12	28 (45.87%)
Grade 3	8	7	15 (23.72%)
Grade 4	0	0	0 (0.00%)
Total	38	24	62 (100%)

Table 3: Comparison of results following post-operative on day 1- day 3

S. No.		CAG	AMG
1	Graft dehiscence/ Recession	3	Nil
2	Edema/chemosis	1	Nil
3	Subconjunctival haemorrhage	7	2
4	Post-operative infection	Nil	Nil

Table 4: Comparison of results following post-operative 1 to 6 months (180th day) period

S. No.		CAG	AMG
1	Recurrence	2 (3.23%)	6 (9.68%)
2	Symblepharon	1 (1.61%)	Nil
3	Graft loss	Nil	Nil
4	Granuloma	Nil	1 (1.61%)
5	Corneoscleral Dellen	Nil	Nil
6	Diplopia	Nil	Nil
7	Scleral thinning	Nil	Nil
8	Scleral ulceration	Nil	Nil
9	Raised IOP	Nil	Nil
10	Post-op infection	Nil	Nil

Results

The mean age group being 42 ± 7 years. A total of 62 patients with 54 male patients and 8 female patients were taken in the study. 38 patients were randomly selected for CAG group rest 24 patients were selected for AMG group, majority had grade 2 type of pterygium in both the groups, table 2. Majority of patients had nasal pterygium accounting up to 60 patients while 2 patients had temporal pterygium.

Graft dehiscence was noticed in 2 patients and 1 patient had graft recession in CAG group at the first post-operative day, thus underwent resurgery to reposit the graft with sutures and was followed for 6 month which did not result in any recurrence of pterygium, Fig. 3. Following other complications are depicted in the table 3.

In 6 months of post-operative observation 2(3.23%) patients in CAG group and 6(9.68%) patients in AMG group had recurrence of pterygium or fibrovascular tissue at the site of previous pterygium excision, Fig. 4, 5. 1 patient with temporal pterygium had symblepharon in the intermediate period of observation in CAG group.

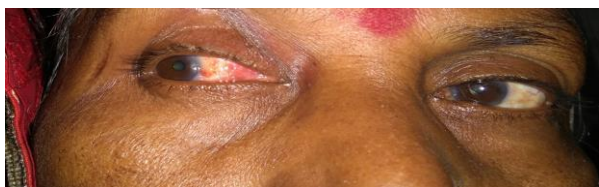

Fig. 3: Showing partial graft dehiscence of CAG in initial pre-operative day (day 3).

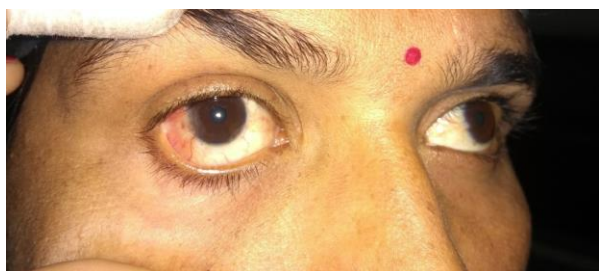

Fig. 4: Recurrence of temporal pterygium with symblepharon near lateral canthus in right eye following 15 days of pterygium excision with autologous blood clot conjunctival autografting

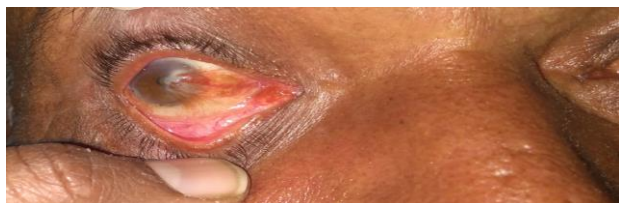

Fig. 5: Aggressive regrowth of pterygium tissue in patient operated with pterygium excision with AMG

Discussion

The modern day concept of pterygium surgeries is to avoid recurrence of pterygium after its surgical excision along with minimum discomfort and better cosmetic appearance has encouraged ophthalmic surgeons to go for different

modalities of pterygium excision with grafting either combined with autologous blood clot, fibrin glue or sutures to secure the graft. Commercial fibrin glue has an advantage over suture related complication but it carries risk of contamination with prion disease and parvovirus B19^{4,5} apart from being costly and its not easily available. Anaphylaxis, even death has been reported with the use of bovine fibrin glue, bovine aprotinin protein in the glue is the allergen.⁶ Thus autologous blood clot CAG was comparatively safer and cheapest to fibrin glue. MMC and 5-FU have been tried in preventing recurrence but it was associated with vision-threatening complications. Kaufman et al study has demonstrated better outcomes of pterygium excision with CAG and LCAG over AMG, as well with MMC recorded fewer recurrence in CAG/LCAG operated patients.⁷ AMG is a good option in case with suspected limbal stem cell deficiency, which carries a risk at the donor site.

In our study the graft related complications such as partial / complete graft dehiscence was observed in 3 patients in their day 1 to day 3 post-operative period who underwent CAG surgery, Fig. 3. The cause was constant vigorous eye rubbing by the patient. These patients were taken for re-surgery to secure the graft with sutures and followed up for next 6 month, these patients did not have any recurrence or any other complications during their follow up period. It was observed that patient who underwent amniotic membrane grafting with suturing had more post-operative discomfort due to sutures in their initial 15 days of surgery till the removal of sutures on 15th postoperative day. The discomfort was tackled with frequent use of lubricating agents (0.5% CMC). This group also showed more pterygium recurrence in 6 patients with AMG and other suture related complications such as prolonged healing, fibrosis and granuloma formation in the 1st post-operative month. Thus during the 1st post-operative month 1 recurrence of pterygium was seen in CAG groups while another 1 during 2nd month of post-operative time (total 3.23% in CAG group). While 6 patients in (9.68%) AMG group was observed during 2nd to 4th month after surgery. 1 female patient operated for temporal pterygium developed recurrence of pterygium with lower lid symblepharon within first 15 days after CAG pterygium excision surgery, Fig. 4. Thus the number of cases reported with recurrence was more in patient operated for pterygium excision with amniotic membrane graft with suturing. The recurrent pterygium tissue was more fibrovascular and adherent to the underlying tissue that the primary pterygium; repeat surgery is often difficult in such cases,⁸ Fig. 5. Use of fibrin glue versus suture for CAG /AMG in primary pterygium was found to result in low recurrence of pterygium.⁹ There was 1 line Snellen's decrease in UCVA in some patients after surgery.

Advantage of CAG over AMG is avoidance of allograft tissue which directly or indirectly effect the cost of the surgery. CAG is more time consuming as well requires surgical precision to obtain the graft as in comparison to AMG; while in our study AMG was secured in place with

the help of sutures thus there was a little time difference in the operating time recorded during the whole surgery in both groups.

Till recent years, autologous blood clot / fibrin glue / suture CAG surgery is generally regarded as the choice of surgery in primary or recurrent pterygium for its lower recurrence, long term safety in contrast to other procedure.^{6,10} The main disadvantage of blood clot conjunctival autograft is the risk of graft loss or graft dehiscence in the first post-operative day, but once the graft adherence is good in within 24-48 hours of surgery the graft stay at it place thus minimizing the graft loss.¹¹

Conclusion

The recurrence of pterygium (≥ 1 mm) was more in amniotic membrane graft patient compared to autologous blood clot tenon free conjunctival autograft. Autologous blood clot conjunctival graft required more surgical skills, proper techniques and took more surgical time as compared amniotic membrane grafting, but BCAG more economical compared to AMG. To conclude, both CAG & AMG appears to be safe for excision of pterygium with fewer recurrence of pterygium.

Conflict of Interest: None.

References

- Sanchez-Thorin JC, Rocha G, Yelin JB. Meta-analysis on the recurrence rates after bare sclera resection with and without mitomycin C use and conjunctival autograft placement in surgery for primary pterygium. *Br J Ophthalmol* 1998;82:661-5.
- Spaeth EB. Rotational island graft for pterygium *Am J Ophthalmol* 1926;9:649-55
- Kenyon KR, Wagoner MD, Hettinger ME. Conjunctival autograft transplantation for advanced pterygium and recurrent pterygium. *Ophthalmol* 1985;92:1461-70.
- de Wit D, Athanasias I, Sharma A, Moore J. Sutureless and glue-free conjunctival autograft in pterygium surgery: A case series. *Eye(Lond)*2010;24:1474-7.
- Koranyi G, Seregard S, Kopp ED. Cut and paste: A no suture, small incision approach to pterygium surgery. *Br J Ophthalmol* 2004;88:911-4.
- Oswald AM, Joly LM, Gury C, Disdet M, Leduc V, Kanny G. Fatal intraoperative anaphylaxis related to aprotinin after local application of fibrin glue. *Anesthesiol* 2003;99(3):762-3.
- Kaufman SC, Jacobs DS, Lee WB, Deng SX, Rosenblatt MI, Shtein RM. Options and adjuvants in surgery for pterygium: A report by the American Academy of Ophthalmology 2013;120:201-8.
- Hirst LW, Recurrent pterygium surgery using pterygium extended removal followed by extended conjunctival transplant: recurrence rate & cosmesis. *Ophthalmol* 2009;116(7):1278-86
- Romano V, Cruciano M, Conti L, Fontana L. Fibrin glue versus sutures for conjunctival autografting in primary pterygium surgery. *Cochrane Database Syst Rev* 2016;12:CDO11308.
- Zheng K, Cai J, Jhanji V, Chen H. Comparison of pterygium recurrence rates after limbal conjunctival autograft transplantation and other techniques: Meta-analysis. *Cornea* 2012;31:1422-7.
- Mitra S. Autoblood as Tissue Adhesive for Conjunctival Autograft Fixation in Pterygium Surgery. Poster Presented at the Annual Meeting of the American Academy of Ophthalmology; 2011, Orlando, FL;2011.

How to cite this article: Soni P, Marndi SJ, Singh AK. Comparative analysis between blood clot conjunctival autografting (CAG) versus amniotic membrane (AMG) grafting on pterygium excision surgery. *Int J Ocul Oncol Oculoplasty* 2019;5(2):55-60.