

Case report: Microphthalmos associated with cataract, persistent fetal vasculature, coloboma and retinal detachment

VP Singh¹, Shrinkhal^{2,*}

¹Professor, ²Junior Resident, Department of Ophthalmology, Institute of Medical Sciences, Banaras Hindu University, Varanasi, Uttar Pradesh

***Corresponding Author:**

Email: shrinkhalbhu@gmail.com

Abstract

We present here a case of left eye microphthalmos associated with cataract, persistent fetal vasculature (previously known as persistent hyperplastic primary vitreous), iris and retinochoroidal coloboma and retinal detachment. No surgical intervention was done and the patient was kept on regular follow-up.

Keywords: Microphthalmos, Cataract, Persistent fetal vasculature, Coloboma, Retinal detachment.

Case Summary

A 12 years old girl was referred to our department with chief complaint of sudden diminution of vision in left eye for last 20 days. She was apparently well 20 days back, and then incidentally she closed her right eye and noticed diminution of vision in her left eye. Antenatal history was uneventful. There was no history of trauma during delivery or during perinatal period. Parents took her to a local practitioner where she was diagnosed with unilateral left eye congenital cataract and referred to our centre.

Her visual acuity at presentation was 6/6 in right eye on Snellen's chart; left eye visual acuity was only 6/60 on Snellen's visual acuity chart. Intraocular pressure was 18 mm of Hg in right eye and 14 mm of Hg in left eye by Applanation tonometry. There was no history of trauma, fever, headache, any drug intake before she noticed her decreased vision in right eye. She had normal birth at term.

On ocular examination, Left eye was smaller than right eye and left eye exotropia of about 15 degree was present (Fig. 1).

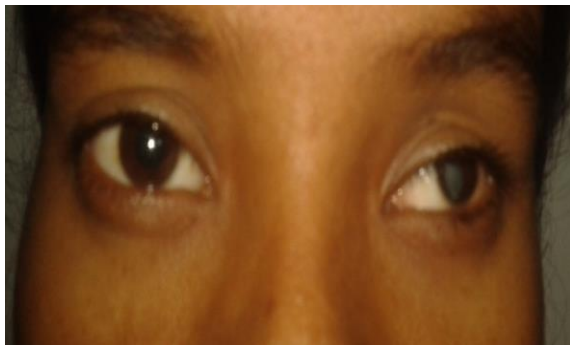

Fig. 1: Left eye microphthalmos and exotropia

Left eye iris coloboma inferiorly with key hole deformity (Fig. 2) associated with posterior synechiae at 12'o clock hr. position was present. Pupil was non-

reacting in left eye. Mature cataract (Fig. 2) was present with fundus details not visible.

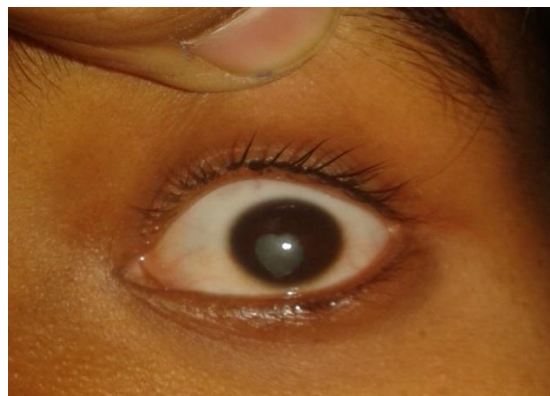

Fig. 2: Left eye inferior iris coloboma, posterior synechiae superiorly and cataract

Left eye corneal diameter (9.50 mm) was also smaller than the right eye(11.03 mm) (Fig. 3).

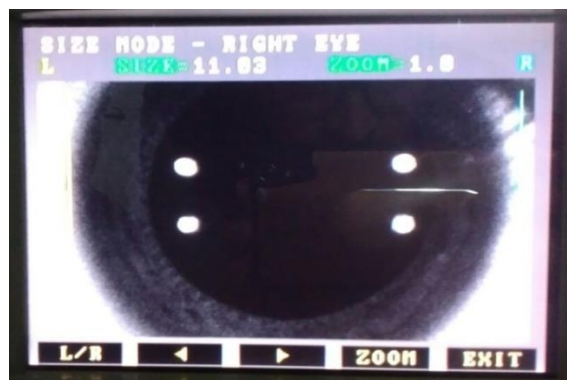



Fig. 3: Corneal diameter of both the eyes

Right eye was within normal limits (Fig. 4).

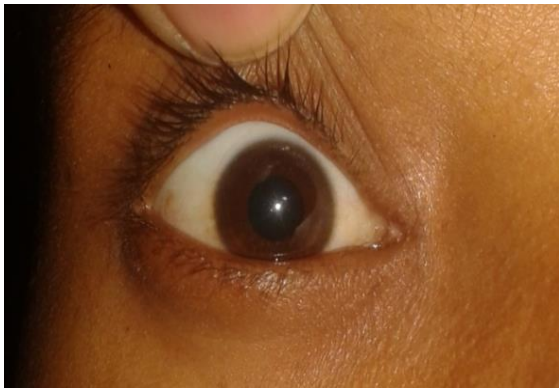

Fig. 4: Normal Right eye

Left eye B-scan Ultrasound with 10 MHz probe revealed cataractous lens, short axial length (13mm) and a V-shaped membrane connecting from optic nerve head to the lens associated with retinochoroidal coloboma at peripapillary area (Fig. 5).

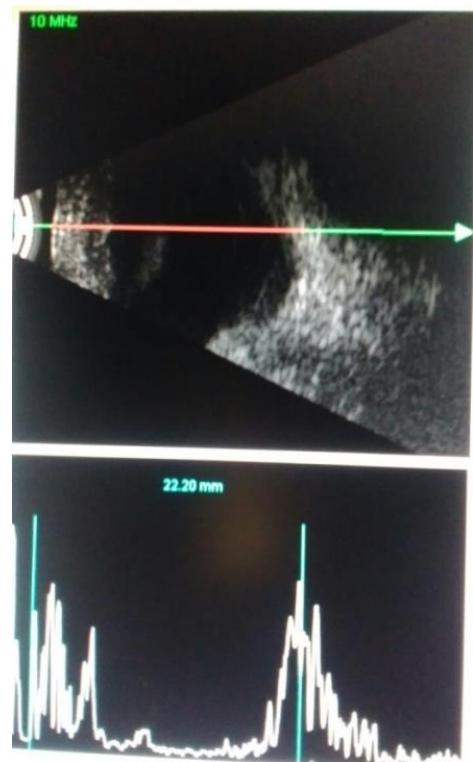
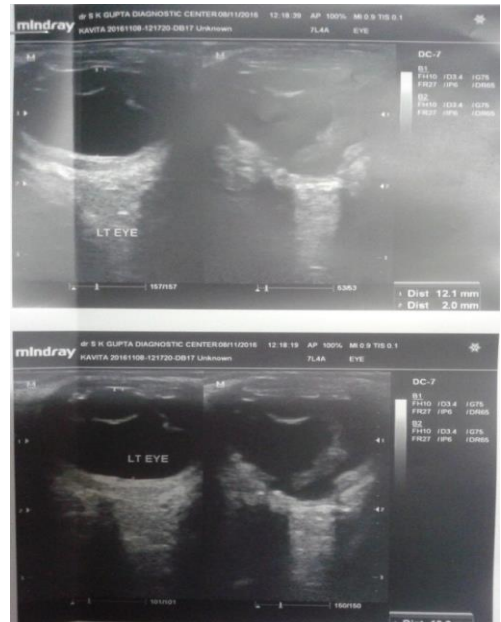


Fig. 5: USG B-scan of left eye demonstrating V-shaped vitreous opacity (connecting optic disc and lens; also shown by A-scan impulses in vitreous cavity) and peripapillary retinochoroidal coloboma

Right eye axial length was 19.4mm. Rest of the posterior segment structures were within normal limits (Fig. 6).

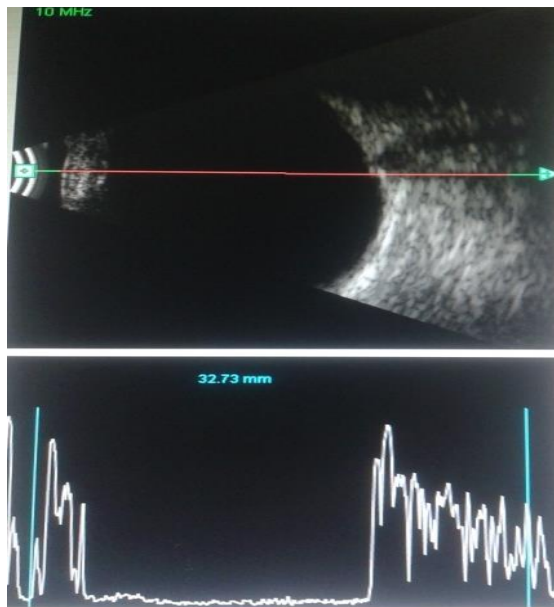


Fig. 6:USG B-scan of right eye showing normal optically clear vitreous with no associated abnormality

Diagnosis of Left eye Microphthalmos associated with persistent fetal vasculature with iris and retinochoroidal coloboma and retinal detachment was made.

As the patient already has developed amblyopia and there are utter chances of development of vitreous haemorrhage and increased retinal detachment intra-operatively; so there was no need for intervention as it may further deteriorate the condition. Poor visual prognosis and nature of the disease has been explained to the patient and her attendant and was kept on regular follow-up.

Discussion

Ocular coloboma can involve any part of the eye and is due to defective embryogenesis. The affected eye is most commonly associated with microphthalmia. The prevalence of coloboma among blind adults is around 0.6–1.9%;⁽¹⁾ and among children, it accounts for a greater proportion of blindness (3.2–11.2%).⁽²⁾ The common cause of coloboma is failure of fetal fissure to close during the 5th to 7th week of fetal life, at the 7–14mm stage.⁽³⁾ During this period, there is invagination of the optic vesicle and the closure of the fetal fissure. The coloboma is called “typical”, if the inferonasal quadrant is involved and it is the most frequent type to be found. It may involve any part of the globe from the iris to the optic nerve. If the coloboma is located anywhere other than the inferonasal quadrant of the globe, it is termed “atypical”.

A complete iris coloboma is a full thickness defect, involving both the pigment epithelium and the iris stroma. It may be total, extending to the iris root and giving rise to the “keyhole pupil”, or partial, involving

only the pupillary margin and causing a slightly oval pupil. Small strands of mesodermal tissue are occasionally seen bridging the coloboma and forming multiple pupils, or polycoria. Such strands may extend to the lens as a persistent pupillary membrane. An incomplete iris coloboma is usually partial thickness, involving either the pigment epithelium or the iris stroma. It tends to be wedge-shaped and is best demonstrated by iris transillumination.

Retinochoroidal coloboma is more commonly associated with visual prognosis. The defect represents an area of bare sclera devoid of overlying normally differentiated retina or choroid. Some retinal vessels may remain and are visible easily. The sclera in the affected area may bulge posteriorly, forming a staphyloma which may involve the entire posterior pole. Histological findings include absence of the RPE, hypoplastic and gliotic overlying retina. Where retinal tissue is recognizable, the retinal layers are reversed, with the rods and cones facing inward and the nerve fiber layer adjacent to the sclera.⁽⁴⁾ But, the RPE at the edge of the defect is hyperplastic. Clinically, they can be seen as leukocoria due to exposed sclera. The coloboma can be involving the macula in which case visual prognosis is poor; or sparing macula where visual prognosis is good. The ocular colobomas may be associated with many chromosomal aberrations and syndromes. Environmental causes and intrauterine insults as thalidomide A exposure, intrauterine Vit. A deficiency, use of anti-convulsants in pregnancy, fetal alcohol syndrome, intrauterine infections can also lead to these complications.

The visual prognosis depends mainly on the fact that the optic nerve, macula, and papulomacular bundle is involved or not. If these structures are involved, severe visual loss is inevitable. Bilateral cases present early in infancy with poor visual function and nystagmus. Unilateral cases may develop a sensory strabismus. Retinal detachment and cataract are the most common complications associated with retinochoroidal coloboma. Of all cases of retinal detachment, 0.6–1.7% is associated with retinochoroidal coloboma.⁽⁵⁾

Proper detailed evaluation of infants with coloboma is really difficult, due to their lack of cooperation, presence of nystagmus and microphthalmos. Infact, effective examination cannot be done without general anesthesia. Retinal, choroidal and optic nerve involvement can be examined with direct and indirect ophthalmoscopy. Accurate refraction should be done, as amblyopia can be induced by anisometropia or by bilateral high ametropia.

Iris coloboma patients can be given cosmetic contact lenses or in severe cases coloboma can be repaired surgically by non-absorbable sutures (Mc-Canal’s iridoplasty). For retinochoroidal coloboma, as it is associated with non-rheumatogenous retinal detachment, prophylactic laser treatment is applied posteriorly along the edge of the coloboma and cryopexy anteriorly. If

surgical intervention is at all required, first laser treatment is done followed by vitrectomy, buckling and air fluid exchange.

During the development of the eye in the womb, there is a blood vessel which runs between the optic nerve and the back of the lens. This blood vessel carries nutrients and oxygen to the developing parts of the front section of the eye. The blood vessel is known as the hyaloid vessel. The vessel, along with surrounding embryonic material, is also known as the primary vitreous. In the 3rd trimester (last third) of pregnancy, the hyaloid vessels are supposed to dissolve, as they are no longer needed. However, if the blood vessels do not disappear, this can result in a particular form of cataract involving the back part of the lens. The condition is known as Persistent Hyperplastic Primary Vitreous, or now named as Persistent fetal vasculature. PHPV is sometimes further divided into subtypes. **Anterior PHPV** occurs when the remnant vascular stalk is seen attached to the back of the lens but no longer extends back to the optic nerve. They have best chance of visual rehabilitation. Here the posterior pole is totally normal with no retinal folds. They present with leukokoria early in life. There is characteristic elongation of ciliary processes and anterior chamber may be shallow leading to glaucoma.

Posterior PHPV occurs when the remnant vascular stalk is seen arising off the optic nerve but not reaching the lens and therefore not usually causing cataract. Posterior PHPV may be associated with developmental abnormalities of the optic nerve or surrounding retina. The surrounding retina can be scarred or even detached. If there is significant involvement of the optic nerve and/or retina, good vision may not be possible. Most often, patients have some element of **both Anterior and Posterior PHPV**. PHPV is often associated with a small eye (microphthalmia). In addition, the pupil often does not dilate well and there may be traction on the tissue behind the iris (ciliary processes).

Surgical management of PHPV depends on its type.^(6,7) In patients with anteroposterior PHPV in which vision is unsalvageable, a lensectomy may be done. In posterior PHPV, when rehabilitation of the eye is deemed possible, a vitrectomy may be performed. In cases of purely anterior PHPV, a lensectomy-membranectomy and anterior vitrectomy. The goal of surgery is to salvage useful vision (in concert with

aggressive amblyopia therapy) and/or to prevent or alleviate glaucoma and to correct amblyopia. Prognosis depends on the type of PHPV. Treatment of posterior and combined anteroposterior PHPV has a less favorable outcome, with most patients attaining perception only of motion or light. Conversely, in purely anterior PHPV, a good visual outcome is achieved when aphakic correction (contact lenses) and amblyopia therapy are successful.

However, surgery for PHPV is complicated by a higher rate of retinal detachment than seen with any other pediatric cataract surgery. The cause of PHPV is unknown. It is almost always a disorder that affects one eye. When PHPV is found in both eyes, this may indicate a syndrome affecting other parts of the body as well.

Conclusion

Patient with microphthalmos associated with cataract, iris and retinochoroidal coloboma and persistent fetal vasculature is a complex situation which should be handled very carefully. The visual prognosis already remains poor and can sometimes be worsened with surgical intervention. So, not all cases with cataract and related complications should be operated. An expert decision and approach is required to tackle these cases.

Acknowledgement: None to declare.

Financial support and sponsorship: Nil.

Conflict of interest: There are no conflicts of interest.

References

1. MacDonald AE: Causes of blindness in Canada: an analysis of 24,605 cases registered with the Canadian National Institute for the Blind. *Can Med Assoc J* 92:264,1965.
2. Fraser GR, Friedman AL: *The Causes of Blindness in Child- hood*. Baltimore, Johns Hopkins Press, 1967.
3. Duke-Elder S: *System of Ophthalmology*, Vol 3, Part 2. St. Louis, CV Mosby, 1963, pp 456–72.
4. Barber AN: *Embryology of the Human Eye*. St. Louis, CV Mosby, 1955, pp 50–63.
5. Wang K, Hilton GF: Retinal detachment associated with coloboma of the choroid. *Trans Am Ophthalmol Soc* 83:49–62,1985.
6. Reese AB. Persistent hyperplastic primary vitreous. *Am J Ophthalmol* 1955;40:317–331.
7. Pollard ZF. Results of treatment of persistent hyperplastic primary vitreous. *Ophthalmic Surg* 1991;22:48–52.