

## Ocular findings in population latino-mestiza of patients with renal carcinoma: first report

Daniel Moreno-Páramo<sup>1,\*</sup>, Victor Enrique Corona-Montes<sup>2</sup>, Marco Antonio Rayón-Rodríguez<sup>3</sup>, Jonathan Alonso Rodríguez-Robles<sup>4</sup>

<sup>1</sup>Retina Specialist, <sup>3</sup>Resident, Dept. of Ophthalmology, <sup>2</sup>Urologist Oncologist, <sup>4</sup>Resident, Dept. of Urology, General Hospital of Mexico

**\*Corresponding Author:**

Email: antor46@hotmail.com, danomp@hotmail.com

---

### Abstract

**Introduction:** In the adult population, renal cell carcinoma (RCC) is the tenth fourth place representing about 2-3% of cancers worldwide. This tumor metastasizes more frequently to lung, liver, bone, subcutaneous tissue and rare way to choroid. There isn't currently, an study describing the posterior segment alterations associated with renal cell carcinoma that may arise in the course of the disease and its relationship to the stadium it.

**Objective:** To evaluate patients diagnosed with RCC to determine the presence of alterations in the posterior segment and its relationship to the stadium it.

**Materials and Methods:** Observational, transverse and descriptive study of 40 patients (80 eyes) with diagnosis of renal cell carcinoma. Demographic data: age, gender, histological type, duration, stage, type of treatment and comorbidities at the time of the review. Measurement variables: visual acuity (LogMAR), biomicroscopy of the anterior segment with slit lamp, photographic record of posterior pole and peripheral retina, retinal fluorescein angiography, electroretinography and optical coherence tomography. Each patient was evaluated by 2 ophthalmologists.

**Results:** 6 patients were excluded due to retinal changes associated with type 2 diabetes mellitus and hypertension. The average age was 55 years (29-78 years), 16 men (47.1%) and 18 women (52.8%), the average time of diagnosis of renal cell carcinoma was 4 months (1-14 months). A total of 33 patients (97%) were treated surgically and 1 (3%) received chemotherapy, the most common histological type was clear cell carcinoma (91.2%) and most patients were in stage II (50 %) at the time of assessment, 4 of them (11.7%) had metastases (stage IV) at diagnosis (lung, skin, bone and choroid respectively). The alterations of posterior segment found during the ophthalmologic evaluation were: choroidal metastases (2.9%), cancer associated retinopathy (2.9%), pigmentary changes in the retinal pigment epithelium of the retina (8.8%) and finally vascular tortuosity (11.7%), 73.5% of patients had a normal posterior segment features. Most patients who had posterior segment alterations were stage IV.

**Conclusions:** In the renal cell carcinoma can be found pigmentary changes at the level of retinal pigment epithelial, vascular tortuosity, cancer associated retinopathy and metastases choroid, these are more common in advanced stages of the disease and are usually found in a routine examination in patients asymptomatic, and independent treatment established.

**Keywords:** Renal Carcinoma, Choroidal metastases, Cancer associated Retinopathy

---

### Introduction

In the adult population, renal cell carcinoma (RCC) is the tenth fourth place representing about 2-3% of cancers worldwide and its incidence is highest in western countries. The clear cell RCC is the most common histologic subtype, according to the classification of Heidelberg,<sup>(1)</sup> 65 560 new cases of RCC per year are diagnosed in the United States and 14 080 deaths per year related to this. It has a male predominance 3:2, and an average age of diagnosis of 65 years. Its incidence has increased from 2 to 4% due to increased use of imaging techniques and are discovered incidentally between 48% and 66% of tumors compared to 3% to 13% in 1970, 25% of people die from causes related to their cancer.<sup>(2,3)</sup>

Many renal masses are asymptomatic and non-palpable until the late stages of the disease. The classic triad of renal fossa pain, hematuria and palpable abdominal mass is now rare (6-10%), paraneoplastic syndromes are identified in 30% of patients with symptomatic RCC.<sup>(4)</sup>

This tumor metastasizes more frequently to lung, liver, bone, subcutaneous tissue and rare way to choroid.

Some patients even present with symptoms of metastatic involvement, such as bone pain or persistent cough. The mainstay of treatment is the removal of the tumor by partial or radical nephrectomy and chemotherapy in advanced stages.<sup>(5-7)</sup>

Currently it is well documented that ocular metastases (METS) are the secondary intraocular malignant tumor more common in the adult, nevertheless, the METS from renal carcinoma are extremely rare, have a predilection for the choroid tissue by up to 80% and the main mechanism pathogenic involved is the hematogenous spread tumor emboli towards the ophthalmic circulation.<sup>(8,9)</sup>

There are other ophthalmological disorders of the posterior segment that may arise during the course of a neoplastic disease, the optic neuropathy, vascular abnormalities, cancer associated retinopathy (CAR) and retinopathy associated with treatment, are some examples, all them, are secondary to immunological mechanisms antigen-antibody;<sup>(10-14)</sup> however, until now, the literature around these changes and their relationship with the CCR is scarce, limited to case reports on METS

as described by LM Holbach,<sup>(15)</sup> Haimovici R,<sup>(16)</sup> S. Srinivasan,<sup>(17)</sup> among others to choroid; and postmortem histopathologic findings made secondary to carcinomas of all kinds as reported by Shields.<sup>(18)</sup>

Up to a third of patients with any type of malignancy that has been studied in ophthalmologic consultation has retinochoroidal alterations of some kind, and turns out to be the first manifestation of the disease in 10-30% of cases, once completed the study protocol.<sup>(7)</sup>

There isn't currently, an study describing the posterior segment alterations associated with renal cell carcinoma that may arise in the course of the disease and its relationship to the stadium it, reason that were evaluated a total of 40 patients (80 eyes) with diagnosis of RCC, to determine the presence of alterations in the posterior segment.

The importance lies in three main points: to keep in mind the RCC as part of the diagnostic protocol in a patient with atypical alterations of posterior segment, implementation of chemotherapy or radiotherapy as adjuvant treatment once identified and improve the visual prognosis by providing treatment to those changes when required.

## Materials and Methods

An observational, transverse and descriptive study was conducted.

**Inclusion criteria:** Forty patients (80 eyes) of the Department of Urology of General Hospital of Mexico (HGM) between March 2015 and April 2016, diagnosed with CRC in different stages and types of treatment.

**Exclusion criteria:** patients with congenital or retinochoroidal alterations associated with chronic degenerative diseases and history of vitreoretinal surgery.

All patients signed an informed consent according to the criteria established by the General Health Law and the Declaration of Helsinki consent.

**Demographics data:** age, sex of patients, histological type of RCC, duration, stage, type of treatment and comorbidities at the time of the review.

**Measurement variables:** visual acuity (LogMAR), biomicroscopy of the anterior segment with slit lamp, photographic record and evaluation with indirect ophthalmoscopy of posterior pole and peripheral retina under pharmacological mydriasis (0.8% Tropicamide/phenylephrine 5%).

Each patient was evaluated by two ophthalmologists.

Retinal fluorescein angiography and Optical coherence tomography were performed on all patients and ocular ultrasound, visual field or electroretinography in cases that required it.

Each patient was rated by 2 ophthalmologists in the General Hospital of Mexico (GHM), to determine the presence of ophthalmic disorders and retinochoroidal in patients with RCC.

All information was recorded in a database in SPSS version 15.0 and descriptive analysis was performed.

## Results

They were assessed a total of 40 patients (80 eyes) of the Department of Urology of GHM diagnosed with RCC, 6 patients were excluded from the study because they showed retinal changes associated with type 2 diabetes mellitus and hypertension (5 and 1 respectively). The average age at the time of the revision was 55 years (29-78 years), 16 men (47.1%) and 18 women (52.8%) of which 5 (11.8%) had systemic arterial hypertension, 4 (14.7%) Diabetes mellitus type 2 and 1 (2.9%) liver failure, the rest without comorbidities. The average time between the ophthalmologic evaluation and the time of diagnosis of RCC was 4 months (1-14 months) (Table 1).

**Table 1: Patients with renal carcinoma (Demographics data)**

Variable	Number of patients (%)	Average (SD)
Sex		
Male	16	(47.1)
Female	18	(52.9)
Comorbidity		
Any	24	(70.6)
SAH	5	(11.8)
DM2	4	(14.7)
Liver Failure	1	(2.9)
Age (years)	55.38	(±11.94)
Diagnostic time (months)	4.35	(±2.82)
Visual Acuity (LogMAR)		
Right eye	0.20	(±0.15)
Left eye	0.19	(±0.09)

SD: Standard Deviation. SAH: Systemic arterial hypertension, DM2: Diabetes Mellitus type 2. LogMAR (Logarithm of the minimum angle of resolution).

A total of 33 patients (97%) were treated surgically and 1 (3%) received chemotherapy, the most common histological type was clear cell carcinoma (91.2%), and most patients were in stage II (50%) at the time of assessment, 4 of them (11.7%) had metastasis (stage IV) at diagnosis (lung, skin, bone and choroid respectively) (Tables 2-5; Image 1).

**Table 2: Type treatment of renal carcinoma**

Type of treatment	Number of patients	(%)
Surgery	33	(97)
Partial nephrectomy	12	(36)
Radical nephrectomy	21	(63)
Medical	1	(3)

**Table 3: Histological type of renal carcinoma**

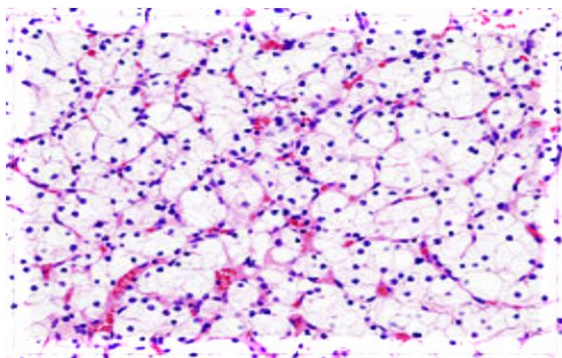
Histological type	Number of patients	(%)
Clear cell	31	(91.2)
Urothelial	2	(5.9)
Oncocytoma	1	(2.9)

**Table 4: Stage renal carcinoma**

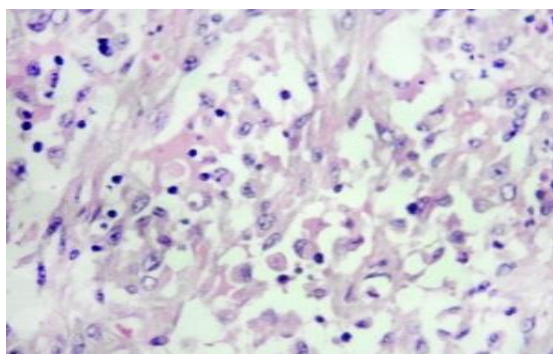
Stage	Number of patients	(%)
I	8	(23.5)
II	17	(50.0)
III	5	(14.7)
IV	4	(11.7)

**Table 5: Site of metastatic renal carcinoma**

Metastasis	Number of patients	(%)
Any	30	(88.2)
Choroid	1	(2.9)
Lung	1	(2.9)
Skin	1	(2.9)
Bone	1	(2.9)

**Image 1: A) Histological section of urothelial tumor.****B) Histological section of clear cell tumor**

A



B

The alterations of posterior segment found during the ophthalmologic evaluation were: choroidal metastasis (2.9%), cancer associated retinopathy (2.9%), pigmentary changes in the retinal pigment epithelium of the retina (8.8%) and finally vascular tortuosity (11.7%), 73.5% of patients had a posterior segment of normal

characteristics (Table 5, images 2-6). Most patients showed changes posterior segment were stage IV (Table 6).

**Table 5: Alterations of posterior segment**

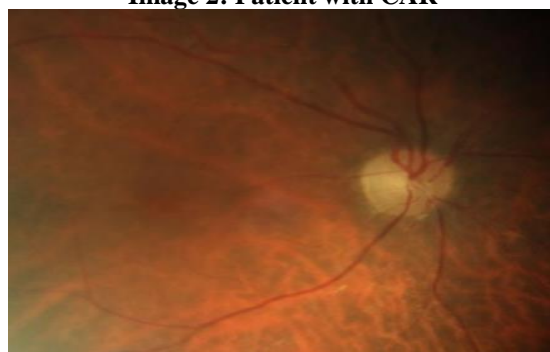
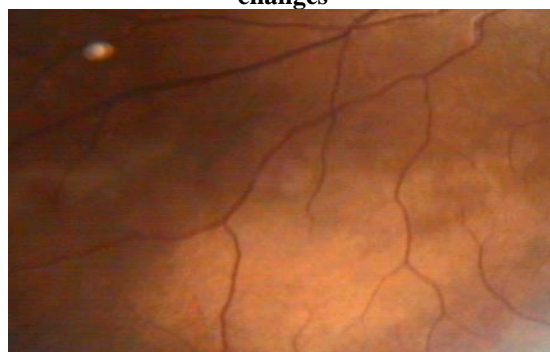
Posterior segment	Number of patients (%)
Normal	25 (73.5)
Vascular tortuosity	4 (11.7)
PC	3 (8.8)
CAR	1 (2.9)
METS	1 (2.9)

PC: pigmentary changes, CAR: cancer associated retinopathy, METS: metastasis.

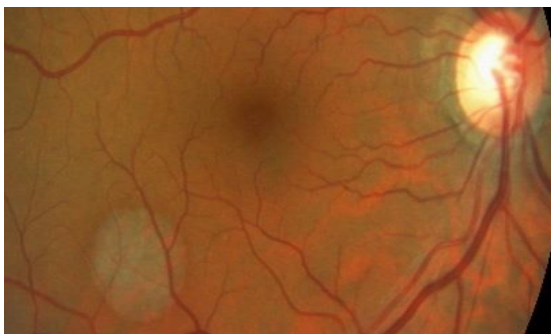
**Table 6: Alterations of posterior segment by stage**

Alteración SP/ Estadio	I	II	III	IV	Total
PC	1	2	0	0	3
VT	1	1	0	2	4
CAR	0	0	0	1	1
METS	0	0	0	1	1
Total	2	3	0	4	9

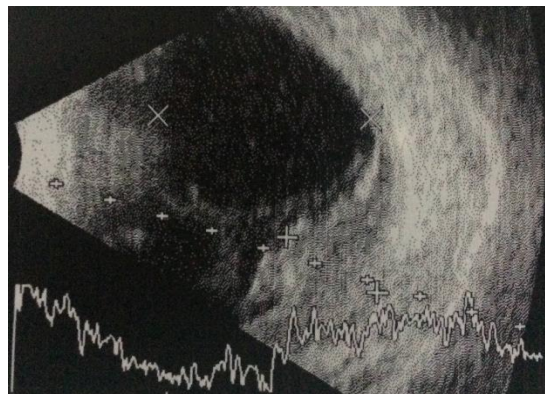
PS: Posterior segment, PC: pigmentary changes, VT: vascular tortuosity, CAR: cancer associated retinopathy, METS: metastasis.

**Image 2: Patient with CAR****Images 3A and 3B: Patients with pigmentary changes**

A

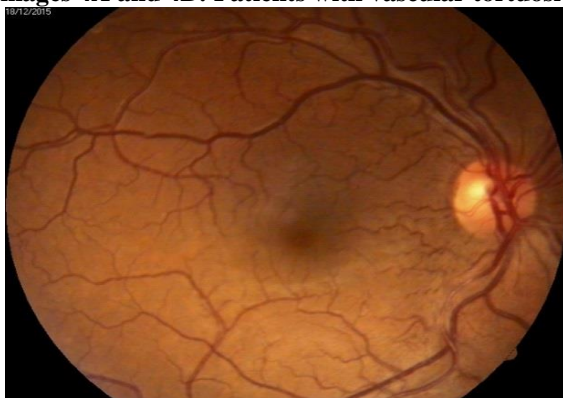

B

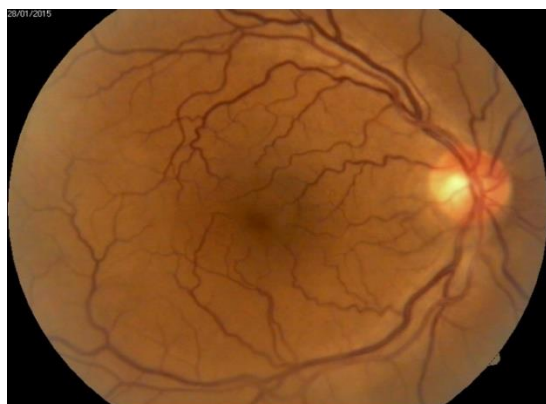

B

Images 4A and 4B: Patients with vascular tortuosity

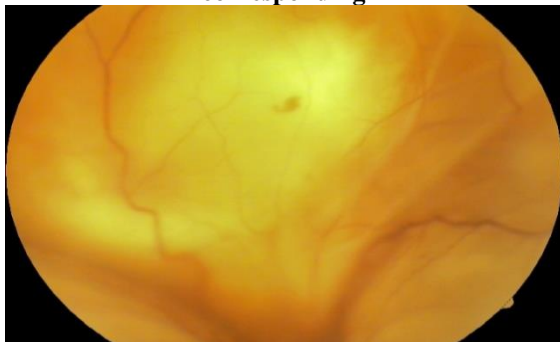


A



B

Image 5 A: Choroidal metastasis. B: Ultrasound A-B corresponding



A

### Discussion

Ocular alterations associated with cancer have in specific symptomatic representation, up to 70% of them can attend asymptomatic and detected in a routine check, the other 30% may present with blurred vision, floaters and even low visual.<sup>(8,9)</sup> In our study, the patient with choroidal metastases came initially to ophthalmology, referring visual low; after ophthalmological and systemic evaluation led to the diagnosis of CRC, chemotherapy was initiated and died within 2 months, the remaining patients they were asymptomatic at the time of the review, as previously described.

The most common histological type of RCC in patients Latino-mestizos found in our study was the clear cell at 91.2% as reported in other reviews.<sup>(1-3)</sup>

This study, to our knowledge, is the first to perform a review ophthalmological posterior segment in patients with RCC for alterations. Pigmentary changes at the level of the retinal pigment epithelium, vascular tortuosity and cancer associated retinopathy, had not been previously reported in that entity. This may be due to the lack of ocular symptoms reported by patients, leading to the absence of ophthalmological assessments during the course of the disease.

The patient with cancer associated retinopathy was in stage IV (lung metastases) at the time of the review and referred asymptomatic, electroretinography and ophthalmological alterations led to the diagnosis. This is similar than that reported in other studies, where low visual and alterations ophthalmoscopic, preceding the diagnosis of primary tumor in 50%, and other 50% course asymptomatic how our study.<sup>(19,20)</sup>

Pigmentary changes in the retinal pigment epithelium were found in early stages of RCC. Three asymptomatic patients without comorbidities presented multiple well defined hypopigmented areas ranging in diameters between 1/2 and 2 disc diameters, located in equatorial region and posterior pole, respecting the foveal area without underlying vascular disorders.

On the other hand four patients in advanced stages of CRC, asymptomatic and without comorbidities showed generalized vascular dilation and tortuosity and some focalized areas of narrowing, their angiographic



studies were within normal parameters. These vascular changes found in our study had been described previously associated with hypertension, phacomatosis, specific and congenital hematologic disorders,<sup>(21,22)</sup> but never to RCC.

It is important to note that although most patients with ophthalmologic disorders were treated surgically different (partial or radical nephrectomy) and adjuvant chemotherapy for cases with METS, no differences were found in the expression of the same, it will be important follow the patients studied and assess the evolution of alterations in subsequent studies, for your understanding.

The time evolution was not a determining factor in the expression of ophthalmological disorders, although most patients were diagnosed at 4 months of evolution on average, there was no correlation between time of evolution and ophthalmologic manifestations, contrary to RCC stage, 4 of the 9 patients with alterations were stage IV at the time of the review.

Generally paraneoplastic syndromes can occur in the context of any tumor, and consist of a wide range of signs and symptoms secondary to distal or local tissue damage of any tumor or their metastasis, the ocular affection in most times, can be asymptomatic despite of the clinical or physiological evidence of structural damage.

All oncologic patients with and without metastases should be sent periodic ophthalmologic exams for early detection of eye disorders associated to provide comprehensive management. Similarly ophthalmologists are obliged to make a systemic and concrete assessment, to reach the etiologic diagnosis of all eye disorders atypical presentation.

## Conclusions

In this study 80 eyes of 40 Latino-mestizos patients diagnosed with renal cell carcinoma (clear cell, oncocyoma, urothelial) the presence of pigmentary changes at the level of pigment epithelial retinal vascular tortuosity, cancer associated and choroidal metastases was observed, these were more frequent in advanced stages of the disease and found in a routine examination in asymptomatic patients undergoing different types of medical and surgical treatment. Because of this we recommend the ophthalmological even in the absence of visual symptoms.

## Acknowledgment

Alfredo Arturo Domínguez López. Degree in optometry. Fluorescein angiography.

## References

1. Ljungberg B, Bensalah K, Canfield S, Dabestani S, Hofmann F, Hora M, et al. EAU guidelines on renal cell carcinoma: 2014 update. *European Urology*. 2015;67(5):913–24.
2. Siegel RL, Miller KD, Jemal A. Cancer statistics, 2015. *CA Cancer J Clin*. 2015;65(1):5–29.

3. Cohen HT, McGovern FJ. Renal-cell carcinoma. *N Engl J Med*. 2005;353(23):2477–90.
4. Gill IS, Aron M, Gervais DA, Jewett MA. Clinical practice: small renal mass. *N Engl J Med*. 2010;362(7):624–34.
5. Delahunt B, Egevad L, Montironi R. International Society of Urological Pathology (ISUP) consensus conference on renal neoplasia: rationale and organization. *Am J Surg Pathol*. 2013;37:1463–1468.
6. Volpe A, Panzarella T, Rendon RA, Haider MA, Kondylis FI, Jewett MA. The natural history of incidentally detected small renal masses. *Cancer*. 2004;100(4):738–45.
7. Yagoda A, Abi-Rached B, Petrylak D: Chemotherapy for advanced renal-cell carcinoma: 1983-1993. *Semin Oncol*. 1995;22:42-60.
8. Solomon SD, Smith JH, O'Brien J. Ocular manifestations of systemic malignancies. *Curr Opin Ophthalmol*. 1999;10:447-51.
9. Kurli M, Finger P. The Kidney, Cancer, and the Eye: Current Concepts. *Surv Ophthalmol*. Nov-Dic 2005;50(6):1-12.
10. Chan JW: Paraneoplastic retinopathies and optic neuropathies. *Surv Ophthalmol*. 2003;48:12-38.
11. Adrean SD, Schwab IR. Central retinal vein occlusion and renal cell carcinoma. *Am J Ophthalmol*. 2003;136:1185-6.
12. Wahner-Roedler DL, Sebo TJ. Renal cell carcinoma: diagnosis based on metastatic manifestations. *Mayo Clin Proc*. 1997;72:935-41.
13. Gold PJ, Fefer A, Thompson JA. Paraneoplastic manifestations of renal cell carcinoma. *Semin Urol Oncol*. 1996;14:216-22.
14. Guyer DR, Tiedeman J, Yannuzzi LA. Interferon associated retinopathy. *Arch Ophthalmol*. 1993;111:350-6.
15. Holbach LM, Chévez P, Snyder WB. Unsuspected renal cell carcinoma metastatic to the choroid nine years after nephrectomy. *Am J Ophthalmol*. 1990;110:441-3.
16. Haimovici R, Gragoudas ES, Gregor Z. Choroidal metastases from renal cell carcinoma. *Ophthalmol*. 1997;104:1152-8.
17. Srinivasan S, Gray DG. Images in clinical medicine. Choroidal metastasis from renal-cell carcinoma. *N Engl J Med*. 2003;349:22.
18. Shields CL, Shields JA, Gross NE, Schwartz GP, Lally SE. Survey of 520 eyes with uveal metastases. *Ophthalmol*. 1997;104:1265-76.
19. Jacobson DM, Thirkill CE, Tipping SJ. A clinical triad to diagnose paraneoplastic retinopathy. *Ann Neurol*. 1990;28:162-167.
20. Adamus G, Machnicki M, Seigel GM. Apoptosis: la muerte celular de la retina inducida por autoanticuerpos de cáncer asociado retinopatía. *Invest Ophthalmol Vis Sci*. 1997;38:283-291.
21. Santos-Bueso E, Fernández-Tresguerres F, Sáenz-Francis F, García-Sáenz S, Martínez-de-la-Casa JM, García-Sánchez J. Retinopatía maligna. *Arch Soc Esp Oftalmol*. 2014;89:298-300.
22. Asensio-Sánchez VM, Torreblanca-Agüera B, Miñambres-Villar MA. Tortuosidad retiniana vascular en neurofibromatosis tipo I. *Arch Soc Esp Oftalmol*. 2005;80:607-9.