

Orbital inflammation caused by bisphosphonates case report and literature review

Gonzalez Barlatay Joaquin Miguel^{1,*}, Ortiz-Basso Tomas², Hernandez Gauna Guillermo³, Vigo Rodolfo Luis⁴, Premoli Eduardo Jorge⁵

^{1,2,3,4}Dept. of Oculoplastic, ⁵Chief, Dept. of Ophthalmology Service, Hospital Italiano De Buenos Aires

***Corresponding Author:**

Email: joaquin.gonzalezbarlatay@gmail.com

Abstract

Bisphosphonates are drugs broadly disseminated and frequently used in clinical practice. Ocular adverse effects are already known and orbital inflammation outstands as one of the most severe. It is clinically evident by palpebral edema, conjunctival congestion, chemosis, ocular motility impairment, pain, diplopia, and blurred vision. It can affect both eyes and be accompanied by anterior uveitis. Timely treatment is vital to expect a favorable outcome. Systemic corticosteroids are the treatment of choice. We present the case of a patient whose inflammation improved after treatment with oral doses of diclofenac.

Introduction

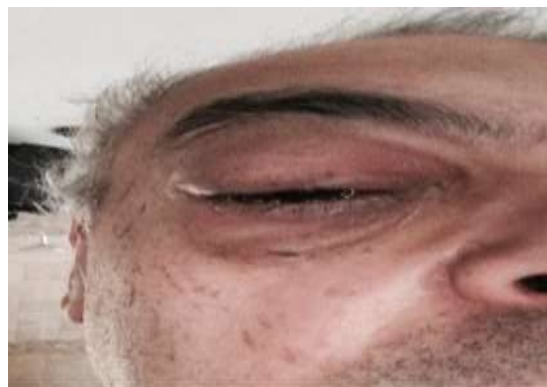Bisphosphonates drugs are widely used in diseases like osteoporosis, Paget's disease, osteoclastic bone metastases, and multiple myeloma. These drugs have high affinity to bone tissue, where they join with hydroxyapatite crystals inhibiting bone reabsorption, decreasing bone unwanted events and improving pain. Among the well-known adverse effects outstands the possibility to trigger an acute systemic inflammatory phase response, characterized by fever, pain, nausea, and fatigue within the first 72 hours after administration in approximately 40% to 50% of the patients.^(1,2) Symptoms are usually transient and resolved spontaneously. However, in a number of cases, they may be treated with analgesic and antipyretic drugs. The clinical presentation is accompanied with a decrease in the lymphocyte count and an increase in pro-inflammatory markers, like cytokines IL-6, IFN- γ , and TNF- α .^(3,6) Ocular adverse effects related to bisphosphonates have been reported. The most frequent are: conjunctivitis, anterior uveitis, episcleritis and scleritis.^(7,8) Orbital inflammation outstands for its clinical degree of severity. Systemic corticosteroids are the treatment of choice. We intend to report a case of orbital inflammation associated with the use of bisphosphonates that was successfully treated with the administration of an oral non-steroidal anti-inflammatory drug (NSAID).

Case Report

Male patient, 52 years old, with a gastric bypass record followed by bone remodeling and knee avascular osteonecrosis that required starting intravenous treatment with pamidronate 60 mg. Seventy two hours later from the administration of the second dose, the patient began with right palpebral edema, chemosis and ocular pain. The patient was treated with tobramycin plus topical prednisolone and intramuscular Duo-Decadron[®] (dexamethasone acetate 8mg and dexamethasone phosphate 2mg). Having not seen any improvement after six days of clinical progress, the

patient looked for medical advice in our service. By the time of the initial medical evaluation, the patient presented visual acuity (VA) of 20/20 in both eyes, isochoric and reactive pupils, ocular motility preserved without diplopia, conjunctival congestion, proptosis of the affected eye, Hertel: right eye 20mm; left eye 17mm (Fig. 1, photo A).

The fundoscopic examination and the computerized visual field were normal. An orbital CT scan showed increase in fat density and lacrimal gland size at the right orbital cavity (Fig. 1). The lacrimal gland was biopsied. The anatomic pathology report preserved acini with little foci of lymphocytes linked to dacryoadenitis (Fig. 2). Based on the patient's medical history of knee bone necrosis, we decided to avoid the use of oral corticosteroids, starting treatment with the oral administration of diclofenac 75mg three times a day (t.i.d.). Thirty three days after the beginning of the clinical presentation, the patient referred significant improvement, with no pain. There were no longer conjunctival congestion and proptosis at the physical exam.



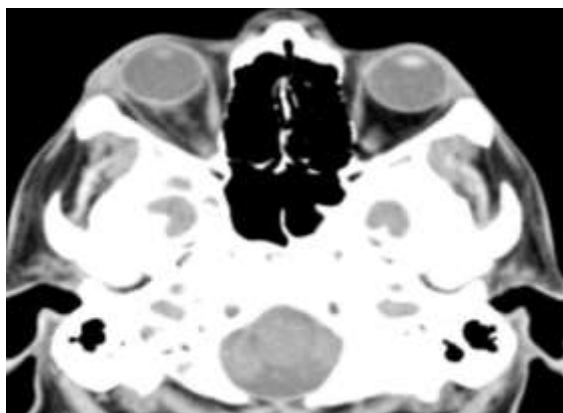
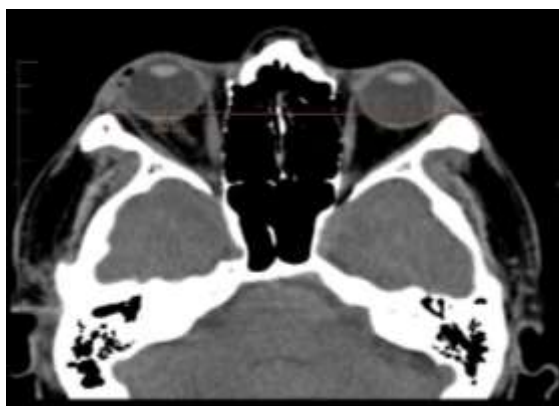
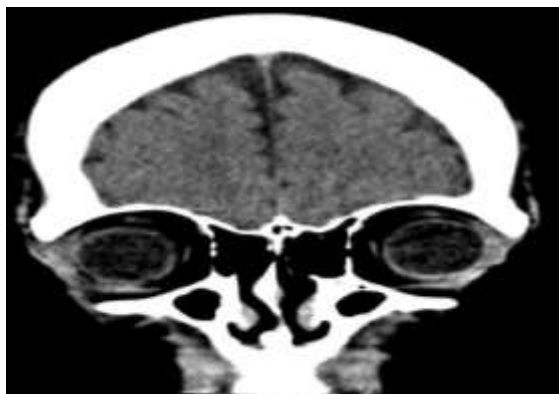
Fig. 1:

- Palpebral edema with chemosis and pain 72 hrs. after administration of 60mg of pamidronate IV.
- Diffuse size enlargement of right lacrimal gland. CT scan coronal plane.
- Diffuse size enlargement of right lacrimal gland with ocular globe proptosis. CT scan axial plane.
- Increase in retroocular and intraconal right orbital mass density. CT scan axial plane.

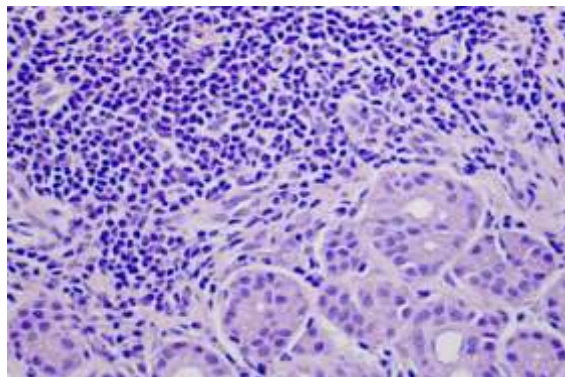


Fig. 2: Lymphocyte infiltration in lacrimal gland with preserved acini

Discussion

Orbital inflammation caused by bisphosphonates is a rare adverse drug reaction. Up to date, there are only 32 case reports published worldwide (9-29). It can be in relation to different routes of administration, like oral alendronate or intravenous pamidronate and zoledronate. Symptoms start within 2 or 3 weeks after the oral administration or 3 days after the intravenous administration⁽⁹⁻²⁹⁾. Zoledronate is the bisphosphonate most frequently associated with this reaction when compared with others, due to its frequent use, potency and effectiveness to treat osteoporosis⁽⁹⁻³⁰⁾. Both, the risk of suffering this acute response and the severity are higher after the first intravenous administration; occurs less frequently with fewer symptoms in subsequent administrations. The Horizon Trial reported an incidence of orbital inflammation associated with the administration of intravenous zoledronate of 30% with the first dose, 7% with the second dose, and 3% with the third dose⁽⁶⁻³⁰⁾. Orbital inflammation can be unilateral or bilateral. Clinical signs are palpebral edema, ocular motility impairment, conjunctival congestion or chemosis associated with symptoms such as pain, diplopia and blurred vision^(11,13,17,19). Moreover, 18% of the cases can be associated with anterior uveitis. On the contrary, this sign is not associated with idiopathic orbital inflammation; for that reason when anterior uveitis develops, physicians may exclude bisphosphonates administration. The mechanism by which these drugs produce inflammation could be potentially related to the presence of a nitrogenous group that rapidly activates monocytes and a subtype of T cells called gamma-delta, both in vitro⁽³¹⁻³⁵⁾ and in vivo^(1,2,36). This activation leads to the release of cytokines and inflammatory mediators producing an acute inflammatory response. Local inflammation is followed by an acute phase of systemic inflammatory response with the presence of symptoms such as fever, pain, nausea, and fatigue in 30% of the patients. It is worth mentioning that 12% of the patients that developed a bilateral orbital condition also had systemic symptoms.

As of today, all reported cases have been treated with oral systemic corticosteroids alone or following an intravenous corticosteroids cycle. The response was effective in all cases, symptoms and CT scan or MRI findings had a complete resolution. In our case report, the patient had received a dose of intramuscular dexamethasone in another medical Centre, which helped to mitigate symptoms temporarily. Based on his medical history of knee bone necrosis, the patient was treated with an oral NSAID (diclofenac sodium 75mg t.i.d.). Signs and symptoms resolved completely after 4 weeks of treatment. Then, we may propose that the orbital and systemic inflammations are self-limited; they may be treated with systemic NSAIDs in cases of mild inflammation, avoiding the side effects associated with the administration of oral or intravenous corticosteroids. However, it is worth noting that treatment with corticosteroids must be initiated immediately in those cases of moderate to severe inflammation.

Conclusion

Orbital inflammation caused by bisphosphonates drugs is a condition rather infrequent; however ophthalmologists must recognize this adverse effect. Furthermore, this condition must be ruled out when bilateral orbital inflammation, with or without anterior uveitis, is present. Patients' acknowledgement of the use of these drugs is key to diagnosis. The treatment of choice is the administration of systemic corticosteroids, which are effective in suppressing the inflammatory response. Oral NSAIDs administration is as effective as corticosteroids in mild inflammation. The use of NSAIDs may be an alternative treatment option for those patients who present contraindications to receive treatment with corticosteroids.

References

- Olson K, Van Poznak C. Significance and impact of bisphosphonate-induced acute phase responses. *J Oncol Pharm Pract.* 2007;13(4):223-9.
- Walton JL, Morgan MP, Martí S, et al. Monocytes and GD T Cells Control the Acute-Phase Response to Intravenous Zoledronate: Insights From a Phase IV Safety Trial. *Journal of Bone and Mineral Research.* 2013;28(3):464-471.
- Thie'baud D, Sauty A, Burckhardt P, et al. An in vitro and in vivo study of cytokines in the acute-phase response associated with bisphosphonates. *Calcif Tissue Int.* 1997;61:386-92.
- Buckler HM, Mercer SJ, Davison CE, et al. Evaluation of adverse experiences related to pamidronate infusion in Paget's disease of bone. *Ann Rheum Dis.* 1998;57:572.
- Dicuonzo G, Vincenzi B, Santini D, et al. Fever after zoledronic acid administration is due to increase in TNF- α and IL-6. *J Interferon Cytokine Res.* 2003;23(11):649-54.
- Reid IR, Gamble GD, Mesenbrink P, et al. Characterization of and risk factors for the acute-phase response after zoledronic acid. *J Clin Endocrinol Metab.* 2010;95:4380-7.
- Macarol V, Fraunfelder FT. Pamidronate disodium and possible ocular adverse drug reactions. *Am J ophthalmology.* 1994;118(2), 220-224.
- O'Donnell NP, Aguis Fernandez A. Paget's Disease: ocular complications of disodium pamidronate treatment. *Br J Clin Pract.* 1995;49:272-273.
- Mbekeani JN, Slamovits TL, Schwartz BH, et al. Ocular inflammation associated with alendronate therapy. *Arch ophthalmology.* 1999;117(6):837-838.
- Ryan PJ, Sampath R. Idiopathic orbital inflammation following intravenous pamidronate. *Rheumatology (Oxford).* 2001;40:956-957.
- Subramanian PS, Kerrison JB, Calvert PC, et al. Orbital inflammatory disease after pamidronate treatment for metastatic prostate cancer. *Arch Ophthalmology.* 2003;121:1335-1336.
- Benderson D, Karakunnel J, Kathuria S, et al. Scleritis complicating zoledronic acid infusion. *Clin Lymphoma Myeloma.* 2006;7(2):145-147.
- Phillips PM, Newman SA. Orbital inflammatory disease after intravenous infusion of zoledronate for treatment of metastatic renal cell carcinoma. *Arch ophthalmology.* 2008;126:137-139.
- Sharma NS, Ooi JL, Masselos K, et al. Zoledronic acid infusion and orbital inflammatory disease. *N Engl J Med.* 2008;359:1410-1411.
- Seth A, Anderson DP, Albiani DA, et al. Orbital inflammation and optic neuropathy with zoledronic acid for metastatic prostate cancer. *Can J ophthalmology* 2009;44:467-468.
- Procianoy F, Procianoy E. Orbital inflammatory disease secondary to a single-dose administration of zoledronic acid for treatment of postmenopausal osteoporosis. *Osteoporosis Int.* 2010;21(6):1057-1058.
- Yang EB, Birkholz ES, Lee AG. Another case of bisphosphonate-induced orbital inflammation. *J Neuroophthalmol.* 2010;30(1):94-95.
- Missotten G, Verheezzen Y. Orbital inflammation after use of zoledronic acid for metastasized prostate carcinoma. *Bull Soc Belge Ophthalmol.* 2010;(315):23-24.
- Yeo J, Jafer AK. Zoledronate associated inflammatory orbital disease. *NZ Med J.* 2010;123(1323):50-52.
- Kaur H, Uy C, Kelly J, et al. Orbital inflammatory disease in patient treated with zoledronate. *Endocr Pract* 2011;17;4e:101-3.
- Ortiz-Perez S, Fernandez E, Molina JJ, et al. Two Cases of Drug-Induced Orbital Inflammatory Disease. *2011 Orbit* 30(1),37-39.
- Peterson JD, Bedrossian EH. Bisphosphonate-Associated Orbital Inflammation—A Case Report and Review. *Orbit,* 2012;31(2),119-123.
- Rahimy E, Law S. Orbital inflammation after zoledronate infusion: an emerging complication. *Can JO phthalmol* 2013;48;1e:11-2.
- Sharma NS, Ooi JL, Masselos K, et al. Zoledronic acid infusion and orbital inflammatory disease. *N Engl J Med* 2008;359(13):1410-1411.
- Schwab P, Harmon D, Bruno R, et al. A 55-year-old woman with orbital inflammation. *Arthritis Care Res (Hoboken)* 2012;64(11):1776-1782.
- Boni C, Kordic H, Chaloupka K. Bisphosphonate-associated orbital inflammatory disease and uveitis anterior—a case report and review. *Klin Monbl Augenheilkd* 2013;230(4):367-369.
- Lefebvre DR, Mandeville JT, Yonekawa Y, et al. A Case Series and Review of Bisphosphonate-associated orbital inflammation. *Ocul Immunol Inflamm* 2014;25:1-6.
- Vora MM, Rodgers IR, Uretsky S. Nitrogen bisphosphonate-induced orbital inflammatory disease: gamma delta Tcells—a report and review of 2 cases. *Ophthal Plast Reconstr Surg* 2014;30(4):e84-85.

29. Pirbhai A, Rajak AN, Goold AL, et al. Bisphosphonate-Induced Orbital Inflammation: A Case Series and Review. *Orbit*. 2015;34(6):331–335.
30. Black DM, Delmas PD, Eastell R, et al. HORIZON Pivotal Fracture Trial. Once-yearly zoledronic acid for treatment of postmenopausal osteoporosis. *N Engl J Med*. 2007;356:1809–22.
31. Kunzmann V, Bauer E, Feurle J, et al. Stimulation of gd T cells by amino bisphosphonates and induction of antiplasma cell activity in multiple myeloma. *Blood*. 2000;96:384–92.
32. Gober HJ, Kistowska M, Angman L, et al. Human T cell receptor gd cells recognize endogenous mevalonate metabolites in tumor cells. *J Exp Med*. 2003;197:163–8.
33. Hewitt RE, Lissina A, Green AE, Slay ES, Price DA, Sewell AK. The bisphosphonate acute phase response: rapid and copious production of proinflammatory cytokines by peripheral blood gd T cells in response to amino bisphosphonates is inhibited by statins. *Clin Exp Immunol*. 2005;139:101–11.
34. Roelofs AJ, Jauhainen M, Mo`nkko`nen H, et al. Peripheral blood monocytes are responsible for gd T cell activation induced by zoledronic acid through accumulation of IPP/DMAPP. *Br J Haematol*. 2009;144:245–50.
35. Thompson K, Keech F, McLennan DJ, et al. Fluvastatin does not prevent the acute-phase response to intravenous zoledronic acid in most-menopausal women. *Bone*. 2011; 49:140–5.
36. Kunzmann V, Bauer E, Wilhelm M. gd T-cell stimulation by pamidronate. *N Engl J Med*. 1999;340:737–8.