

Content available at: <https://www.ipinnovative.com/open-access-journals>

IP International Journal of Ocular Oncology and Oculoplasty

Journal homepage: <https://ijooo.org/>

Case Report

Periocular calcinosis cutis in teen age due to hyperparathyroidism – A rare situation with a mini review

Soma Rani Roy^{1*}, Rahat Anjum², Sujit Kumar Biswas³, Md. Sazzad Kader³, Nabil Islam³

¹Dept. of Orbit & Oculoplasty & Ocular Oncology, Chittagong Eye Infirmary & Training Complex, Chattogram, Bangladesh

²Apollo- Imperial Hospital, Chattogram, Bangladesh

³Chittagong Eye Infirmary & Training Complex, Chattogram, Bangladesh



ARTICLE INFO

Article history:

Received 05-07-2024

Accepted 22-07-2024

Available online 27-08-2024

Keywords:

Calcinosis cutis

Metastatic calcinosis

Hyperparathyroidism

Surgical excision

ABSTRACT

Ocular calcinosis cutis of metastatic type is very rare. Metastatic calcinosis due to chronic renal failure is common than other causes. There are very few reports of such disorder due to hyperparathyroidism and mostly related to secondary hyperparathyroidism. Our patient was a teen age boy with single lesion in both lower lids due to primary hyperparathyroidism and was managed by surgical excision.

This is an Open Access (OA) journal, and articles are distributed under the terms of the [Creative Commons Attribution-NonCommercial-ShareAlike 4.0 License](https://creativecommons.org/licenses/by-nc-sa/4.0/), which allows others to remix, tweak, and build upon the work non-commercially, as long as appropriate credit is given and the new creations are licensed under the identical terms.

For reprints contact: reprint@ipinnovative.com

1. Introduction

Calcinosis cutis is a rare disorder of calcium metabolism where insoluble calcium salts are deposited in skin and subcutaneous tissue which may be in association with different diseases.¹ These usually appear as firm, yellow to white nodular or sheet like lesion and may be single or multiple.²

There are several causes for this disorder and divided in five subtypes such as dystrophic, metastatic, idiopathic, iatrogenic, and calciphylaxis.³ Among these five types, dystrophic type is the commonest one and usually associated with autoimmune connective tissue diseases as a result of tissue damage.⁴ One of least variety is metastatic calcinosis which occurs due to alteration in hemostasis of serum calcium and phosphate in blood. In this type, deposits usually located in periarticular regions. The commonest cause of metastatic calcinosis is chronic renal failure though hyperparathyroidism, hypervitaminosis D, sarcoidosis, malignancy can also cause it.³

Location of such deposition depends on the causes of the calcinosis and common site are finger tips. Ocular adnexal involvement is an uncommon event and there are only 56 cases have been reported from 1970 up to January 2024.^{5–7} Here we describe a case of periocular calcinosis cutis in a teen age patient due to primary hyperparathyroidism.

2. Case Report

A 14 years old male patient presented with painless whitish nodular lesion in both lower lids near medial canthus for last 5 months. He also complained of occasional headache for 7 months. He was the 3rd child and had no history of other systemic diseases. There was no history of trauma or weight loss. He did not have any positive family history of any such disease or other disease. Ocular examination revealed an elevated, pearly to chalky white almost nodular lesion about 5x4x3 mm in right side and 6x5x3 mm in left side in medial aspect of both lower lids. The lesions were firm, non-tender, with a rough surface which were fixed to skin. His vision, anterior and posterior segment was normal. The differentials were sebaceous cyst, Molluscum

* Corresponding author.

E-mail address: dr.somaroy2020@gmail.com (S. R. Roy).

contagiosum and milia. He underwent excisional biopsy and histopathology revealed that, the lesion was lined by stratified squamous epithelium with granular basophilic deposits in dermis and papillary dermis representing the calcification. There were few chronic inflammatory cells in sparse fibro collagenous stroma and also acanthosis of epidermis, suggesting of calcinosis cutis.

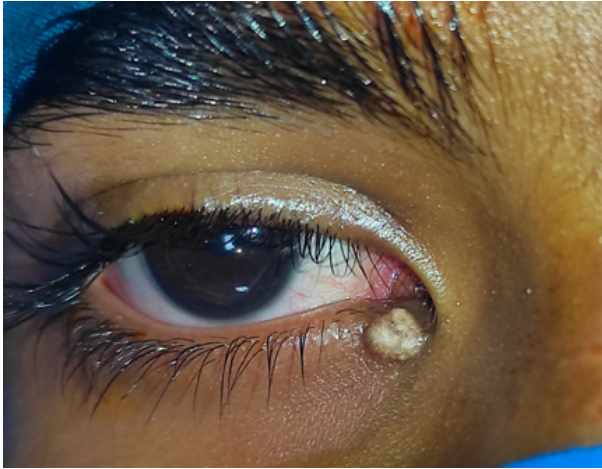


Figure 1: Right eye showing 5x4x3 mm nodular whitish lesion in lower lid.

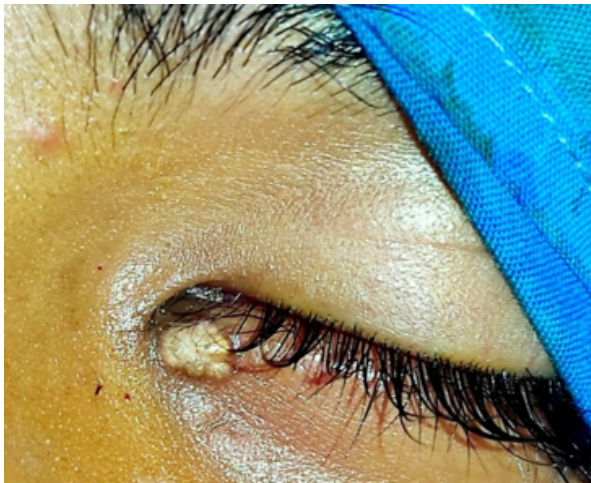


Figure 2: Left eye showing 6x5x3 mm nodular whitish lesion in lower lid.

The patient's history and clinical examination was re-evaluated to find other systemic clue but no additional finding was found. He was then advised several investigations to find out the cause of abnormal deposition of calcium under the skin. His serum calcium was 75mg/dl which was high; normal phosphorus level, 2.5 mg/dl and a high parathyroid hormone level 210 pg/mL but serum Vitamin D was little bit low. His ANA, serum creatinine, chest x-ray, ultrasonography of abdomen was normal.

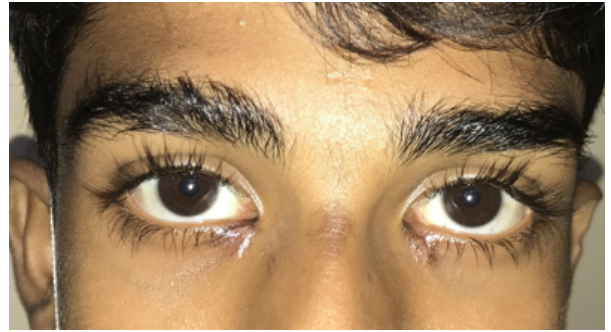

Figure 3: Post operative picture after 2 months, showing mild scarring.

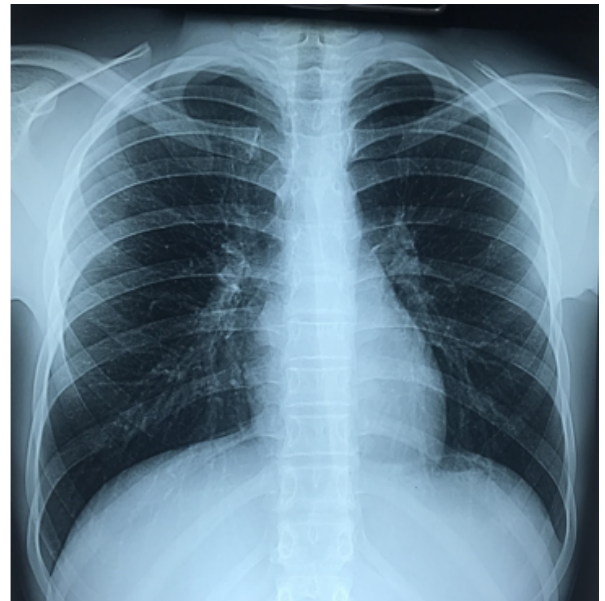


Figure 4: Chest x-ray showing no bony deformity.

Due to raised parathyroid hormone he was referred to endocrinologist. He was also asked for regular ocular check-up and there was no recurrence of lesion for 8 months.

3. Discussion

In 1855, Virchow first described the condition where insoluble amorphous calcium salts are deposited under the epidermis in various parts of the body and termed as calcinosis cutis.⁸

Calcinosis cutis is rare, association may be multiple systemic or iatrogenic and not so much well documented in literature. The dystrophic type is the most common variety of calcinosis cutis with normal blood level of calcium and phosphorous but calcium salt deposited due to tissue damage. Autoimmune connective tissue especially systemic sclerosis and dermatomyositis are the commonest association with dystrophic calcification.

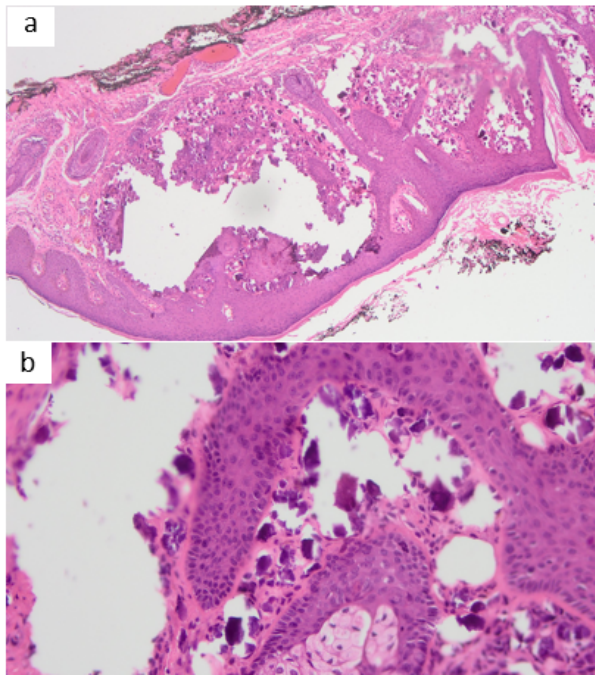


Figure 5: a,b: Histopathology image- the lesion lined by stratified squamous epithelium with granular basophilic deposits in dermis and papillary dermis representing the calcification. Few chronic inflammatory cells in sparse fibro collagenous stroma and acanthosis of epidermis.

Beside wide spectrum of connective tissue diseases, dystrophic calcification can be caused by localized trauma, burn, cutaneous malignancy and rarely due to systemic fungal infections.^{3,9} In Idiopathic variety, the laboratory values are also normal and not associated with any tissue damage. This idiopathic calcinosis has some sub variety such as subepidermal calcified nodules, familial tumoral calcinosis and scrotal calcinosis.³ The metastatic type is associated with some systemic disorder which causing elevated serum calcium and/or phosphorus level. Calcium salt precepted when serum calcium level exceeds 70 mg/dl, usually in skin and subcutaneous tissues.^{3,10} This type of calcification can also occur in blood vessels, kidneys, gastric mucosa and lungs.¹⁰ The commonest disorder is chronic renal failure and others are hyperparathyroidism, hypervitaminosis D, sarcoidosis, malignant neoplasm and milk-alkali syndrome.³

The occurrence of iatrogenic calcinosis is due to administration of calcium or phosphate containing agent and inducing precipitation of calcium salts. This was observed during treatment with intravenous calcium gluconate, calcium chloride, and para-amino-salicylic acid during the treatment of pulmonary tuberculosis. It can be prevented by diluting the calcium solution and lowering phosphorus levels before administration.¹¹ Some authors classified another variety of calcinosis termed as calciphylaxis which

involves of small and medium-sized vessels of the dermis or subcutaneous fat mainly in the end stage of renal disease.⁸

The current case was a male patient of 14 years old, presented with single lesion in both lower lids near medial canthus. Literature search showed female were most reported in combined cases of calcinosis cutis^{11–13} but in periocular cases male were more.¹⁴ Epidemiology stated that, about 30% adult and 70% child and adolescent can present with calcinosis cutis.³ Two different study showed the mean age of presentation was 40 years in a 78 patients' series with autoimmune disease¹² and 48.6 ± 18.6 years in 34 patients with multiple cases of calcinosis cutis.¹³ But in periocular cases, in 90% cases the age of presentation was 21 years or younger.¹⁴ About 63% patients were non-caucasian and most (82%) presented with single lesion.

Regarding location, it was categorized 1. Extremities (shoulder, upper arm, forearm, thighs, and calves), 2. hands and feet, trunk (chest, abdomen, back, waist), 3. Buttocks and groin (genitalia, hips), and 4. Head (scalp, neck, face). Most reported location was hand and feet (fingertips) followed by extremities and mostly associated with pain.^{10,13} In periocular cases upper lid (63%) predilection was more than the medial canthus (28%) and lower lid (9%).⁵ In ocular presentation, lesions are usually small and about 81% were found less than 5 mm and our case had both lesions located in lower lid with diameter of lesion of 5 and 6 mm respectively.¹⁴

To determine the exact cause of calcinosis is important for knowing the systemic association and to select management options. In current case, there was elevated serum calcium and parathyroid hormone level and normal serum phosphorus and low level of vitamin D level. His other blood test, ultrasonography and x-ray were normal. These reports primarily suspect the cause of calcinosis cutis is metastatic calcinosis due to primary hyperparathyroidism. There is paucity in literature regarding this situation especially ocular adnexal presentation due to metastatic calcification. Hamny et al, recently reported one case of calcinosis cutis with primary hyperparathyroidism in a 77 years old lady and mentioned that previously they have reported 5 cases of secondary hyperparathyroidism with calcinosis and primary one is very rare.¹⁵ One review article from 2003 to 2016 in a 34 patients series showed that 70.6% were dystrophic calcification, 11.8% were idiopathic calcification and calciphylaxis each and only 5.9% were metastatic calcification.¹³

It is a challenge to manage calcinosis and it depends on cause, location, numbers of the lesions. The options are conservative, medical and surgical. The aim of conservative management is to facilitate main treatment and to increase blood flow which includes avoiding trauma, stress, cold, cessation of smoking etc. Medical treatment includes treatment of inciting factors or associations along with local treatment. Warfarin, ceftriaxone, and intravenous

immunoglobulin (IVIG) are reported to be effective for small lesions. Larger lesions respond to diltiazem, bisphosphonates, probenecid, aluminum hydroxide. For calciphylaxis, sodium thiosulfate can be the first choice and phosphate binders, bisphosphonates, and cinacalcet are beneficial too.¹⁶ Surgical excision and carbon dioxide laser can be used for localized lesions and surgical curettage for larger lesions but there is chance of recurrence.³

4. Conclusion

Ocular metastatic calcinosis is very rare and it is important to find out association for further treatment. Calcinosis can be kept as a differential for any unusual skin lesion in periocular region.

5. Declaration of patient consent

The authors certify that they have obtained all appropriate patient consent forms. In the form the patient's parent have given their consent for his images and other clinical information without name to be reported in the journal.

6. Conflict of Interest

None.


7. Source of Funding

None.


References

- Gutierrez-Jr A, Wetter DA. Calcinosis cutis in autoimmune connective tissue diseases. *Dermatol Ther.* 2012;25(2):195–206.
- Davuluri S, Lood C, Chung L. Calcinosis in systemic sclerosis. *Curr Opin Rheumatol.* 2022;34(6):319–27.
- Le C, Bedocs PM. Calcinosis Cutis. 2023 Jul 10. In: StatPearls [Internet]. Treasure Island (FL): StatPearls Publishing; 2024.
- Walsh JS, Fairley JA. Calcifying disorders of the skin. *J Am Acad Dermatol.* 1995;33(5 Pt 1):693–706.
- Bothra N, Ali MJ, Trakos N, Naik MN. Lacrimal punctal and peripunctal involvement in calcinosis cutis. *Indian J Ophthalmol.* 2018;66(5):720–22.
- Reeves C. SKIN J Cutaneous Med. *Eyelid Calcinosis Cutis.* 2024;8(1):1297–300.
- Jain P, Trivedi S, Singhal U, Kumar R. Unusual presentation of calcinosis cutis: A diagnostic dilemma. *Indian J Pathol Oncol.* 2022;9(2):169–72.
- Reiter N, El-Shabrawi L, Leinweber B, Berghold A, Aberer E. Calcinosis cutis: part I. Diagnostic pathway. *J Am Acad Dermatol.* 2011;65(1):1–12.
- Walsh JS, Fairley JA. Calcifying disorders of the skin. *J Am Acad Dermatol.* 1995;33(5 Pt 1):693–706.
- Fernandez KH, Ward DS. Calcinosis cutis: Etiology and patient evaluation. Wolters Kluwer; 2023. [Mar 14, 2023]. Available from: <https://www.uptodate.com/contents/calcinosis-cutis-etiology-and-patient-evaluation>.
- Valenzuela A, Chung L. Calcinosis: pathophysiology and management. *Curr Opin Rheumatol.* 2015;27(6):542–8.
- Balin SJ, Wetter DA, Andersen LK, Davis MD. Calcinosis cutis occurring in association with autoimmune connective tissue disease: the Mayo Clinic experience with 78 patients. *Arch Dermatol.* 1996;148(4):455–62.
- Róbert L, Kiss N, Medvecz M, Kuroli E, Sárdy M, Hidvégi B, et al. Epidemiology and Treatment of Calcinosis Cutis: 13 Years of Experience. *Indian J Dermatol.* 2020;65(2):105–11.
- Khine KT, Shi DS, Bernhisel A, Gertsch KR, Mamalis N, Patel BCK, et al. *Ophthalmic Plast Reconstr Surg.* 2018;34(2):101–5.
- Hamny I, Mendes M. Calcinosis cutis as a rare manifestation of primary hyperparathyroidism: a case report. *Endocrine Abstracts.* 2023;90:317. doi:10.1530/endoabs.90.P317.
- Vedvyas C, Winterfield LS, Vleugels RA. Calciphylaxis: A systematic review of existing and emerging therapies. *J Am Acad Dermatol.* 2012;67(6):253–60.

Author biography

Soma Rani Roy, Consultant  <https://orcid.org/0000-0002-7095-4489>

Rahat Anjum, Associate Consultant  <https://orcid.org/0009-0005-2233-6992>

Sujit Kumar Biswas, Consultant  <https://orcid.org/0000-0002-7006-5788>

Md. Sazzad Kader, Senior Assistant Surgeon

Nabil Islam, Assistant Surgeon

Cite this article: Roy SR, Anjum R, Biswas SK, Kader MS, Islam N. Periocular calcinosis cutis in teen age due to hyperparathyroidism – A rare situation with a mini review. *IP Int J Ocul Oncol Oculoplasty* 2024;10(2):102-105.