

Content available at: <https://www.ipinnovative.com/open-access-journals>

IP International Journal of Ocular Oncology and Oculoplasty

Journal homepage: <https://ijooo.org/>

Review Article

A systematic review on prosthodontic rehabilitation of hemimandibulectomy patients

Aishwarya Soni^{1*}, Shreyans Damade¹, Swapnil Parlani¹, Aishwarya Bisen¹¹Dept. of Prosthodontics, People's College of Dental Sciences and Research Centre, Bhopal, Madhya Pradesh, India

ARTICLE INFO

Article history:

Received 19-03-2024

Accepted 15-04-2024

Available online 03-05-2024

Keywords:

Hemimandibulectomy

Guiding flange

Twin occlusion

ABSTRACT

To restore oral function after tumor excision, practitioners must undertake the enormous challenge of restoring hemimandibulectomy deficits.

Depending on the type and extent of mandibular reconstruction (Cantor-Curtis classification), there are many prosthetic treatment options available for the rehabilitation of acquired hemimandibulectomy abnormalities.

The objective of this systematic study is to evaluate the range of prosthodontic rehabilitation techniques in relation to the kind of repair and severity of mandibular surgical abnormalities.

The databases incorporated for literature search were Google Scholar and Medline (PubMed). Relevant search terms for hemimandibulectomy and reconstruction with prosthetic rehabilitation were used.

Two reviewers independently assessed the articles using eligibility criteria; published case reports and case series in the English language and depicting prosthodontic treatment modality of patients greater than 13 years were included.

A total of 212 records were identified from the database search of which 29 duplicates were removed.

The remaining articles were assessed for eligibility, and 50 articles (comprising 50 cases) were finally included in the study.

This review identified a number of prosthetic options, including some novel prosthetic techniques, guiding flange, twin occlusion, palatal ramp, conventional to hybrid partial and complete dentures, and implant-supported prosthesis.

The prosthetic options covered in this review included implant-supported prosthesis, guide flange, dual occlusion, palatal ramp, conventional, hybrid, and full dentures, as well as a few cutting-edge prosthetic techniques.

As they plan and manage sequential therapy for hemimandibulectomy cases in their daily practice, practitioners and prosthodontists will find this helpful.

This is an Open Access (OA) journal, and articles are distributed under the terms of the [Creative Commons Attribution-NonCommercial-ShareAlike 4.0 License](https://creativecommons.org/licenses/by-nc-sa/4.0/), which allows others to remix, tweak, and build upon the work non-commercially, as long as appropriate credit is given and the new creations are licensed under the identical terms.

For reprints contact: reprint@ipinnovative.com

1. Introduction and Background

Partial or complete maxillofacial deformities involving hard and soft tissues have been caused by surgical excision of a variety of benign and malignant tumors, such as osteosarcoma and ameloblastoma, as well as numerous injuries to the maxilla and/or mandible injuries.¹⁻³

Oral function, appearance, and comfort are all negatively impacted by these disorders, which lowers life quality. Significant surface area is needed for sufficient prosthesis retention, which is significantly lessened as a result of complete surgical resection.⁴⁻⁶

Patients' prosthodontic rehabilitation becomes more difficult as a result of the radiation and surgery combined, which further reduces the underlying tissue that supports

* Corresponding author.

E-mail address: soni.aish21@gmail.com (A. Soni).

their dentures' ability to bear weight.¹

There are a number of categories for hemimandibulectomy abnormalities depending on the type and degree of mandible resection, but the Cantor and Curtis (CC) classification, developed in the 1970s, was extensively used in most of the research studies.

Six classes are created by this system to categorize problems based on the remaining structures.³

Class I: Mandibular resection involving alveolar defect with preservation of mandibular continuity Class II: Resection defects involve loss of mandibular continuity distal to the canine area. Class III: Resection defect involves loss up to the mandibular midline region. Class IV: Resection defect involves the lateral aspect of the mandible, but are augmented to maintain pseudoarticulation of bone and soft tissues in the region of the ascending ramus. Class V: Resection defect involves the symphysis and parasymphysis region only, augmented to preserve bilateral temporomandibular articulations. Class VI: Similar to class V, except that the mandibular continuity is not restored.

A multidisciplinary approach involving an oncologist, oral and maxillofacial surgeon, prosthodontist, speech therapist, physiotherapist, etc. is used to restore the hemimandibular deformity.⁷

The course of treatment varies according on the type of mandibular reconstruction (soft tissue graft, such as pectoralis major myocutaneous flaps, or hard tissue transplant, such as fibula, iliac, etc.).⁸

The course of treatment varies according on the type of mandibular reconstruction (soft tissue graft, such as pectoralis major myocutaneous flaps, or hard tissue transplant, such as fibula, iliac, etc.).

Despite these suggested courses of care, clinicians still struggle to reach a consensus on the best prosthetic rehabilitation for hemimandibulectomy patients.

There has already been a review of the literature on the functional outcomes of prosthetic treatment following hemimandibulectomy, but there hasn't been a published systematic review on the subject.

In order to provide treatment recommendations based on the type of mandibular reconstruction and the extent of the defect based on the available evidence, the current systematic review conducted a thorough analysis of prosthetic treatment approaches in patients who had hemimandibulectomy.²

2. Review

2.1. Methodology

2.1.1. Review protocol

The systematic literature search was performed according to the Preferred Reporting Items for Systematic Reviews and Meta-analysis (PRISMA) guidelines³ and was registered at the International Prospective Register of Systematic

Reviews (PROSPERO-CRD42021264928).

2.1.2. Literature search strategy

An initial search was conducted on December 30, 2023, by using electronic databases of Medline (PubMed) and Google Scholar by two independent researchers (SK and SS) for published articles from January 1, 2011, to June 30, 2023, as per inclusion criteria. The database Medline (PubMed) was searched with the following keywords for Medical Subject Headings (MeSH) terms: "hemimandibulectomy", "rehabilitation", "prosthetic" and combinations of these keywords were used for Google Scholar with appropriate filters.

2.2. Screening and selection

All published case reports and case series on human subjects having hemimandibulectomy defects, fulfilling the inclusion criteria and depicting a type of prosthetic rehabilitation were considered. Only full-text articles published in the English language were included. Original research, clinical trials, laboratory studies, animal studies, editorials, questionnaire studies and reviews were excluded. Titles and abstracts were screened (HD and SK) according to the inclusion criteria, and those with unclear methodology were included in the full text assessment (Table 1).

2.3. Risk of bias assessment

Quality assessment of all the relevant studies included in the present review was performed by two reviewers (HD and BS) according to the Joanna Briggs Institute (JBI, Adelaide, Australia).⁴

This JBI critical appraisal tool comprises eight questions for case reports and 10 questions for case series that assess specific domains to determine the potential risk of bias and could be answered with 'yes', 'no' or 'unclear' (Supplementary Appendix 1).

Reports scoring less than four questions out of eight as 'yes' (<50% JBI) in case reports and less than five answers as 'yes' out of 10 questions in case series were denoted as high risk of bias and were excluded. Any disagreements between reviewers were discussed and resolved by consensus.

If no consensus could be reached, a third reviewer (RJ) gave a binding verdict. The risk of bias in individual studies was determined with the following cut-offs: low risk of bias if 70% of answers scored yes, moderate risk if 50% to 69% of questions scored yes and high risk of bias if yes scores were below 50% and were excluded.

Table 1: Inclusion and exclusion criteria

S.No.	Year	Author	Age/ sex	Patient info t/t	C/C	h/o Radiotherapy	Mouth opening	T/T
1.	1976	Dorsey J. Moore, D.D.S.,* and Donald 1. Mitchell, D.D.S.**	56/M	SCC	3	NAD	NAD	The maxillary removable partial denture performed two functions. On the unoperated side, the denture guided the mandible into a functional occlusion.
2.	2011	Pravin kumar Gajanan Patil, Smita Pravinkumar Patil	17/F	the follicular ameloblastoma of the left mandible 6 months back	6	YES	40mm	GFP.
3.	2011	Manchikalapud I Githanjali*, Hegde Veena	77/M	proliferative verrucous leukoplakia of the left mandible	3	NAD	NAD	Neutral Zone Denture
4.	2011	Sandeep Yadav, 2 Aman Arora	64/M	squamous cell carcinoma and patient went for surgical resection of the same	3	NAD	25mm	CPD
5.	2011	Palekar U.*, DugadJ.*	67/F	SCC of the alveolus of left side of mandible	3	NAD	NAD	GFP followed by complete denture
6.	2012	Gupta SG*, Sandhu D	55/f	Carcinoma of left mandible	3	YES	NAD	GFP with a palatal flange
7.	2012	Fabrizio Carini, Giambattista Gatti	64/m	pathological fracture of Right Side of mandible	4	NAD	NAD	implant-supported overdenture.
8.	2014	Anand V. Pradhan, S.P. Dange,	40/M	follicular ameloblastoma of left side of mandible	4	NAD	25mm	GFP
9.	2013	Dr. Laxmi Chhuchha, Dr. Mahesh A Gandhewar	71/M	SCC of the right side of mandible	3	YES	NAD	GFP was fabricated in clear acrylic resin
10.	2014	RAVI SUREJA, Y G NAVEEN	47/m	SCC on the right side of the mandible	3	NAD	NAD	TWIN OCCLUSION
11.	2014	Virendra Atodaria I Sareen Duseja	46/M	SCC of Left buccal mucosa	3	YES	NAD	Twin Occlusion with denture
12.	2014	RAVI SUREJA, Y G NAVEEN	47/m	SCC on the right side of the mandible	3	NAD	NAD	TWIN OCCLUSION
13.	2015	Romesh Soni 1, Rajul Vivek	58/m	SCC on the left side of the mandible	4	NAD	NAD	RPD
14.	2015	Mahajan T, Trivedi	75/m	Carcinoma of the Right mandible	2	NAD	NAD	TWIN OCCLUSION
15.	2015	Rajendran Appadurai	49/M	carcinoma left buccal mucosa	3	YES	35mm	Palatal GFP

Continued on next page

Table 1 continued

16.	2015	Dr. Anurag Ahuja, Dr.Jagadees	40/M	SCC on the right side of the mandible	2	YES	NAD	RPD
17.	2015	H.S. SHASHIDHARA, Roopa Kundur Thippanna	50/F	SCC	3	YES	22mm	TWIN OCCLUSION DENTURE
18.	2015	Koralakunte PR, Shamnur SN	55/F	differentiated SCC of left mandibular alveolus	2	NAD	NAD	maxillary acrylic guided inclined plane with twin occlusion prosthesis
19.	2015	J.Gandhimathi1, N.Krishnameera	25/F	loss of right side of the mandible due to road traffic accident	3	YES	25mm	The design of the definitive non-guiding prosthesis for mandibulectomy patient depend upon the relation of the remaining teeth to the opposing occlusal surface
20.	2015	Mahajan T, Trivedi	75/m	Carcinoma of the Right mandible	2	NAD	NAD	TWIN OCCLUSION
21.	2016	Rajul Vivek	59/m	carcinoma of alveolus with cervical nodes	2	YES	NAD	Tooth Supported Overdenture
22.	2017	Shailendra Kumar Sahu, B.K. Motwan	56/m	SCC of left buccal mucosa, and alveolus	2	NAD	NAD	Twin occlusion
23.	2017	Lara Jain1, Himanshu Aeran	53/M	SCC on the right side of the mandible	3	NAD	25mm	Acrylic Denture
24.	2017	Deenadayalan Lingeshwar, Rajendran Appadurai	36/M	carcinoma left buccal mucosa for which he underwent hemimandibulectomy.	2	NAD	25mm	GFP
25.	2018	Choudhary S, Ram S, Kumar A	31/F	Cemento Ossifying Fibroma	2	YES	25mm	CPD
26.	2019	Dr. Angleena Y. Daniell, Dr. B Vinod		Ameloblastoma of the left mandible	4	Nad	nad	CPD
27.	2019	Sangeeta Madan, Sapna Rani	35/M	SCC in right buccal mucosa 2 years back	3	NAD	25mm	GFP
28.	2019	Rongguang Liu, MBBS,a Mariko Hattori, DDS, PhD,	35/M	carcinoma left buccal mucosa.	3	NAD	30mm	GFP
29.	2020	Cora A Coutinho, Divya Hegde	74/M	early squamous cell carcinoma involving left mandibular alveolus	3	YES	32mm	TWIN OCCLUSION
30.	2020	Vivek Gaur, Anita Gala Doshi	68/m	OSCC, extirpation of the right retromolar trigone	1	YES	NAD	Implant Supported Overdenture, with maxillary twin occlusion,

Continued on next page

Table 1 continued

31.	2020	Cora A. Coutinho, Ivy F. Coutinho	75/M	early SCC involving left mandibular alveolus.	3	YES	32mm	Twin Occlusion.
32.	2020	Mohammed Mubasheeruddin, S.C. Nagaral	23/M	Cemento Ossifying Fibroma	3	NAD	NAD	GFP , CPD
33.	2020	P. Venkat Ratna Nag, Tejashree Bhagwatkar	36/M	ameloblastoma of left mandibular alveolus	4	NAD	NAD	Implant supported Fixed Prosthesis
34.	2020	Akshay Patel1, Sunil Ronad2	68/M	carcinoma of right buccal mucosa.	2	NAD	NAD	implant retained overdenture
35.	2021	Siddharth Bandodkar, Deeksha Arya,	42/M	SCC of the left mandible	3	NAD	30mm	GFP
36.	2021	Rahul Bahri1, Poonam Prakash	53/M	oropharyngeal carcinoma 04 years back	2	NAD	8 mm	Cast metal guidance prostheses
37.	2020	Vivek Gaur, Anita Gala Doshi	68/m	OSCC, extirpation of the right retromolar trigone	1	YES	NAD	Implant Supported Overdenture, with maxillary twin occlusion,
38.	2023	Gupta SG, Sandhu D, Pasam N	27/M	Carcinoma of the left mandible	2	NAD	NAD	Maxillary GFP Followed by Removable partial Denture
39.	2023	Ritu Sharma, Akanksha Sharma	62/M	SCC on the left side of the mandible	4	NAD	NAD	TWIN OCCLUSION
40.	2023	Manu Rathee, Prachi Jain	63/M	SCC OF right buccal mucosa	2	NAD	25mm	GFP with RAMPS, followed by RPD

Abb: c/c – Cantor and Curtis classification, SCC- Squamous Cell Carcinoma, GFP- Guiding Flange prosthesis, NAD- No Adequate description, CPD-Cast partial Denture

3. Data extraction

The relevant studies obtained following screening were categorised into two groups: case reports and case series. Two reviewers (HD and SK) accomplished data extraction individually, while AJ checked the data: author name, year of publication, JBI score, age, gender, extent of defect (CC classification), name and type of prosthesis in both arches, reconstruction type (if any), surgical scarring, radiotherapy, follow-up period and adverse effect.

4. Results

4.1. Study characteristics

The initial literature search from the selected databases revealed 202 records from which 19 duplicates were identified and removed. After the screening of titles and abstracts, 55 articles (58 cases) with moderate to low risk of bias were finally included after quality assessment (Figure 1).

A total of 58 individuals (28 males and 7 females) with hemimandibular defect according to the Cantor Curtis classification (class I: n= 3; class II: n= 25; class III: n= 24; class IV: n=6; class V and VI: n=0) were finally included.

4.2. Prosthetic rehabilitation

Implant-supported prosthesis (ISP) was adopted in four studies. Thirteen cases used guide flange (palatal/mandibular (MGFP)/maxillary ramp prosthesis (MRP)) for the correction of mandibular deviation, whereas twin occlusion prosthesis was delivered in 10 individuals. Interim (MGFP/MRP) followed by definitive prosthesis like cast partial denture (CPD; n=4), CPD with attachment and overlay denture was noted. In two cases, implant-supported overdenture was the treatment of choice,

4.3. Post-prosthetic Follow-Up

Post-prosthetic recall visits were reported in 28 cases with duration ranging between 48 hours to four years (n=9; < 1 month, n=27; 1 month to 1 year, n=4; >1 year). Recall visit without duration was noted in twelve cases, while follow-up was not reported among 2 cases.

4.4. Inclusion criteria

1. Patient above 20 years of age
2. Hemimandibulectomy following surgical resection

4.5. Exclusion criteria

1. Patient 20 years or less
2. Total mandibulectomy

5. Discussion

Prosthetic rehabilitation of hemimandibulectomy defects is a challenging task including multiple procedures with an interdisciplinary approach towards restoring function and patient satisfaction.^{9–14}

5.1. Prosthetic alternatives according to nature and extent of the defect

Given the possibility of radiation-induced osteoradionecrosis at the bone level, prosthetic rehabilitation following resection involving radiotherapy presents placement problems for implants.

Dental implants should be placed after a year of radiation therapy as doing so correlates with a 34% higher failure rate when placed within 12 months after radiotherapy. When radiation exposure surpasses 5,000 cGy, implant failure rate rises to 33%.

A single-piece smooth surface cortically anchored implant-supported fixed partial denture put in native bone was used to successfully rehabilitate a case of class I defect demonstrating marginal mandibulectomy.^{15–20}

As opposed to two-piece implants, these implants are the better option in post-radiotherapy cases because they don't require active biologic osseointegration (immediate loading is possible), transmit occlusal forces at the cortical bone, lower the risk of infection, and don't have micro gap junctions, which results in the least amount of plaque accumulation that causes peri-implantitis.²¹

In situations where dental implants are not practical, removable CPD or CD with extracoronary semi-precision attachments is a less intrusive and more affordable treatment option.⁵

Due to mandibular deviation towards the resected side displaying rotation and angular course of jaw closure, a segmental mandibulectomy distal to the canine (CC class II) without hard tissue repair prevents the patient from being able to chew.

Implant supported overdenture adjunct with MRP has solved these issues and shown to be beneficial for patients who are completely edentate. This is made worse in edentate arches because unilateral occlusal forces generated during mastication cause the maxillary denture to become dislodged.

The use of monoplane teeth in conjunction with a neurocentric concept is recommended to create a non-restrictive occlusion due to the irregular jaw connections and the angular path of closure.²²

The maxillary ramp offers a wide occlusal table for comfortable mastication, stabilizes the prosthesis, and restricts mandibular deviation.

If implants are impractical, it is advised to use detachable MGFP/MRP, in which the deviation can be corrected by manipulating the mandible, and then a definitive

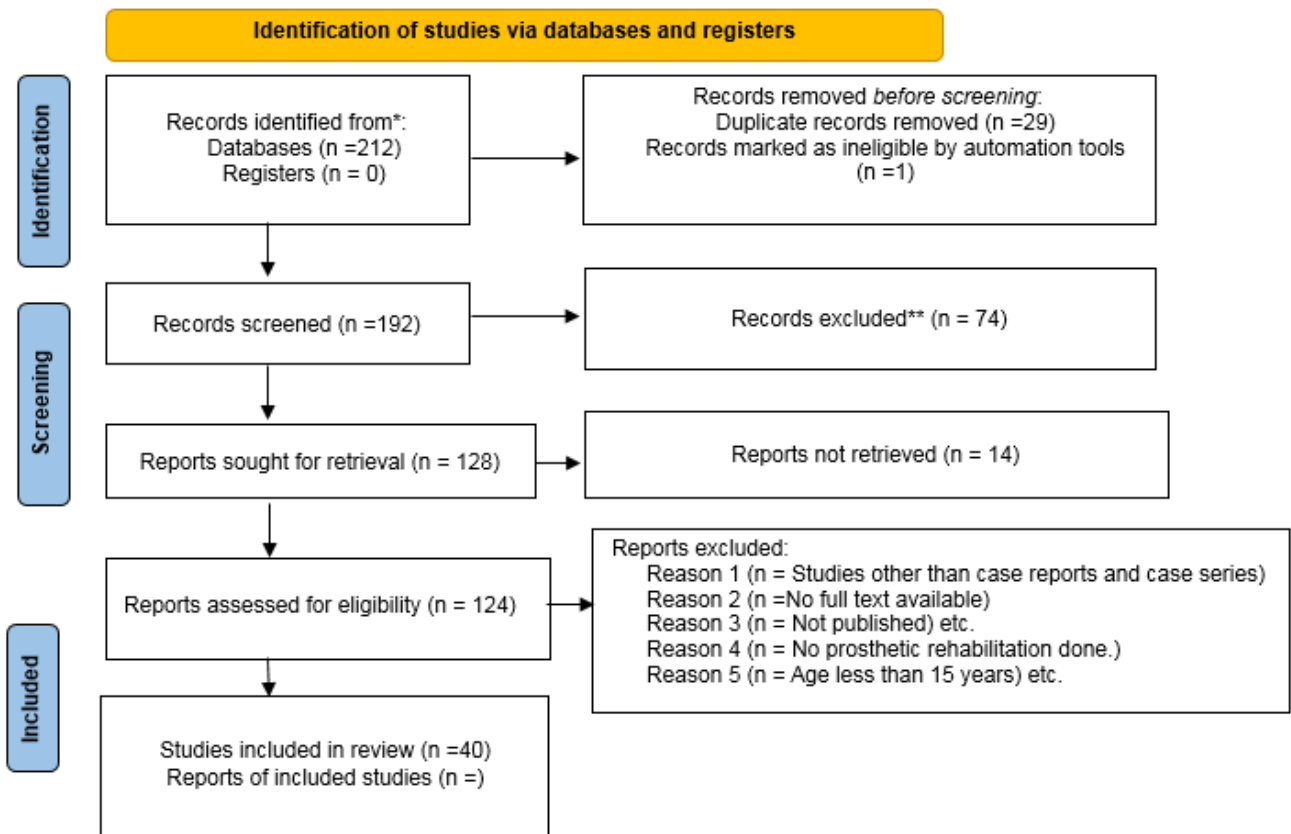


Figure 1: PRISMA flow diagram depicting the literature selection process

prosthesis.⁷

When mastication and aesthetics are desired but manual mandibular deviation correction is not achievable, as is typically the case after radiotherapy and scar formation, a twin occlusion—a buccal row for cheek support and a palatal row for occlusion—has shown to be helpful.⁴

The prognosis for treatment becomes more complicated when a class III segmental resection that extends to the midline causes increased mandibular deviation with noticeable facial disfigurement, decreased masticatory function, diminished speech, and altered occlusion with condylar rotation leading to an anterior open bite.²³

Jaw exercises after resection should be started as soon as possible to enhance the maxillomandibular connection and loosen the scar contracture.

Moreover, intermaxillary fixation may reduce deviation, although it makes feeding more difficult.⁴

Comparing acrylic MGFP to metal guide flange, it is less expensive and has the benefit of periodic adjustment.⁵

The sequential adjustment process thins and weakens the acrylic flange; therefore, an inventive way to address this issue is to reinforce with wrought wire formed like a "W."²⁴

With regard to class II problems, the twin occlusion prosthesis as described in that scenario is recommended.

In completely edentate individuals, the definitive treatment of choice is similar to class II defect.²⁵

Because they are easy to insert and remove, flexible dentures (Valplast) are recommended in cases of restricted mouth opening and mandibular deviation.

To improve retention and attractiveness, acetal resin clasp was used in conjunction with monoplane occlusion, which reduces stress and increases stability.²²

Resection of the mandible's lateral aspect is necessary for Class IV defects in order to preserve the pseudoarticulation of soft tissue and bone in the ascending ramus area.²⁶

Due to the depressor muscle action of the normal side, it manifests as facial asymmetry, mandibular deviation, and incorrect occlusion.²⁷

A number of therapeutic approaches, such as intermaxillary fixation, resection guidance restorations, and mandibular guiding therapy, have been suggested to lessen post-surgical mandibular deviation.²⁸

By using an MRP in respect to the non-defect side and MGFP on the defect side to establish bilateral guidance, a comparable difficult situation with restricted interarch distance creating occlusal interference by the buccal flange of MGFP on the non-resected side has been overcome.⁸

This special combination of prosthesis minimizes the deviation and uses neuromuscular reprogramming activity to retrain the user to achieve appropriate occlusion.²⁹

The authors have proposed the use of vascularized free flaps for rapid mandibular reconstruction following resection in order to improve masticatory efficiency and prevent implant placement difficulties following radiation therapy.³⁰

For a mandible that has been rebuilt, implant prosthesis is the preferred treatment. However, the osseous graft must heal and the implants must osseointegrate over a prolonged period of time (in radiation therapy).

In the early stages of recovery, early prosthodontic intervention with MGFP and a maxillary stabilization prosthesis helps to decrease mandibular deviation, prevent maxillary teeth from being driven out of place, and improve masticatory efficiency.²⁹

An efficient, cost-effective substitute for implants in situations where they are not practical is an interim MGFP/MRP followed by CPD.^{3,22,29}

Authors have replaced the traditional complex design with a modified swing lock CPD that has the flexible arc of the acetal labial bar for improved retention and stability.⁵

A final prosthesis can be used after MGFP to correct mandibular deviation and anterior open bite in a difficult class IV deformity, combined with extensive neck dissection and base of the tongue.^{2,4,6}

In cases where a guiding appliance is not able to adequately correct a patient's mandibular rotation, an overlay RPD can provide ideal bilateral occlusion, compensate for any residual open bite, and enhance the patient's form and function.²⁷

The present systematic review had limitations as it was restricted only to Medline by means of PubMed and Google Scholar; so, the literature published on other databases and languages apart from English may have been omitted despite meeting all our inclusion criteria. Randomised controlled trials (RCT) were scarce in our search on the particular topic; therefore, the next level of evidence (i.e. case reports and series) was included; therefore, authors are urged to perform extensive RCTs on similar topics. Post-prosthesis observation duration was a deficit in many studies, while few reported short-term (less than one month) follow-up; therefore, future studies with long-term follow-up data are recommended for assessing the prosthesis longevity. Several data were lacking from the reviewed literature including CC classification, reconstruction type and scarring which decreases the article quality limiting us to deduce a strong correlation among the type of prosthesis to be selected for a particular situation.

6. Conclusions

This study suggests that the first line of treatment following surgical resection should be hard tissue graft reconstruction

along with interim guiding and definitive implant prosthesis (after one year in case of irradiation).

If occlusion can be achieved manually in cases of CC grades II, III, IV, and V problems related to mandibular deviation, MGFP/MRP would be the recommended treatment method, followed by a definitive prosthesis.^{4,6}

In cases where mandibular deformity prevents manual occlusion, a dual occlusion prosthesis is recommended.

Despite its limitations, this analysis offers a summary of several prosthetic approaches according on the kind of reconstruction and level of hemimandibular deformity. Enough patient adjustment, with a couple minor problems that were beneficial once fixed.

When treating individuals who have hemimandibulectomy, this study will help clinicians plan their care.^{4,23,31}

7. Source of Funding

None.

8. Conflict of Interest


None.

References

1. Soni R, Vivek R. A Prosthetic Rehabilitation of Hemimandibulectomy Patients With Twin Occlusion – A Case Report. *Unique J Med Dent Sci.* 2015;3(3):33–5.
2. Vivek R, Report PAFTOHPAC. *Unique Journal of Medical and Dental Sciences.* 2016;04(02):34–37.
3. Gupta S. The use of mandibular guidance prosthesis to correct mandibular deviation following hemimandibulectomy-Case reports. *Medicine.* 2012;.
4. Carini F, Gatti G, Saggese V, Monai D, Porcaro G. Implant-supported denture rehabilitation on a hemimandibulectomized patient: A case report. *Ann Stomatol (Roma).* 2012;3(2):26–31.
5. Sureja R, Naveen YG, Sethuraman R, Prajapati P, Patel JR. Twin occlusion prosthesis: a ray of hope for hemimandibulectomy patient- A case report. *Eur J Dent Ther Res.* 2014;3(3):231–3.
6. Mahajan T, Trivedi R, Singh S, Sangur R. Prosthetic Management of Edentulous Mandibulectomy Patient with Modified Occlusion - A Case Report. *Rama Univ J Dent Sci.* 2015;2(4):42–5.
7. Sharma R, Sharma A, Verma BP, Singh S, Singh S. occlusion prosthesis: A glimmer of hope for hemimandibulectomy patient. *Indian J Dent Sci.* 2019;11(1):61. doi:10.4103/IJDS.IJDS_89_18.
8. Kumar S, Dwivedi H, Singh B, Jha AK, Jain R, Singh S. A Systematic Review on Prosthodontic Rehabilitation of Hemimandibulectomy Defects. *Cureus.* 2023;15(9).
9. Chhuchhar L, Gandhewar MA. Guide Flange Prosthesis for Management for a Hemimandibulectomy Patient- A Clinical Case Report. *J Dent Med Sci.* 2013;8(6):23–5.
10. Rathee M, Jain P, Shetye AG, Alam M. Prosthodontic rehabilitation using balancing ramp-guided flexible prosthesis in a squamous cell carcinoma patient treated with hemimandibulectomy. *Indian J Dent Sci.* 2022;14(1):28–31.
11. & Ahuja A, Jagadeesh HG, & Choudhary, & Vikram A, & Hasti J, Anurag. Prosthetic Management of Hemimandibulectomy Patient -A Case Report. *IOSR Journal of Dental and Medical Sciences.* 2015;.
12. Shashidhara HS, Thippanna RK, Dang K, Hajira N, Sharma A. Modified Occlusal Table - An Aid to Enhance Function of Hemimandibulectomy Patient: A Case Report. *J Clin Diagn Res.* 2015;9(9):1–3.


13. Nag PV, Bhagwatkar T. Prosthetic management of a hemimandibulectomy patient using tilted implant protocol with 3‑year follow‑up. *J Indian Prosthodont Soc.* 2020;20(3):326–30.
14. Mubasheeruddin M, Nagal SC, Kalburgi M, Lijeena A, Benji ROAHPAC, Report. *The journal of PROSTHETIC AND IMPLANT DENTISTRY*;
15. Kumar S, Yadav R. Prosthetic rehabilitation of a hemimandibulectomy patient. *Gen Dent.* 2014;62(2):30–2.
16. Atodaria, & Duseja V, & Sareen, Shah, & Dipti, Vaishnav, et al. 2014.
17. Patel A, Ronad S, Gandhewar M, Kuwlekar SD, Nagal S, Dodamani G, et al. Management of Edentulous Hemimandibulectomy Patient with Implant Retained Overdenture- A Case Report. *J Appl Dent Med Sci.* 2020;6(4):1–12.
18. & Prakash P, Bahri, Issar, Bhandari S. Management of hemimandibulectomy patients with guidance flange prosthesis using combination technique- A case report. *IP Annals of Prosthodontics and Restorative Dentistry.* 2021;7.
19. Anand AV, Pradhan SP, Vaidya S. Mandibular repositioning in a hemimandibulectomy patient using guide flange prosthesis: A Case Report. *J Adv Med Dent Sci.* 2014;2(2):161–5.
20. Bandodkar S, Arya D, Singh SV, Chand P. Guide flange Prosthesis for management of hemimandibulectomy. *Natl J Maxillofac Surg.* 2021;12:289–93.
21. Moore DJ, Mitchell DL. Rehabilitating dentulous hemimandibulectomy patients. *J Prosthet Dent.* 1976;35(2):202–206.
22. Sahu SK, Motwani BK, Dani A. Prosthetic rehabilitation of edentulous hemimandibulectomy patient: a clinical report. *Clin Case Rep.* 2017;5(11):1739–42.
23. Lingeshwar D, Appadurai R, Sswedheni U, Padmaja C. Prosthodontic management of hemimandibulectomy patients to restore form and function - A case series. *World J Clin Cases.* 2017;5(10):384–389.
24. Holland N, Mckenna G. Prosthodontic management of a patient with mandibular asymmetry: a case report. *Clin Case Rep.* 2018;6(7):1258–1263.
25. Daniel DAY, Vinod DB. Prosthetic rehabilitation of dentulous hemimandibulectomy patient - a clinical case report. *Int J Med Biomed Stud.* 2019;3(7):183–7.
26. & Madan S, Rani, & Sapna, Jainer, Kumar, & Shalabh, et al. 2018.
27. Patil PG, Patil SP. Guide flange prosthesis for early management of reconstructed hemimandibulectomy: a case report. *J Adv Prosthodont.* 2011;3(3):172–6.
28. Gaur V, Doshi AG, Gandhi S. Immediate Prosthetic Rehabilitation of Marginal Mandibulectomy Post Radiation Case by Single-Piece Implant - A Case Report. *Ann Maxillofac Surg.* 2020;10(2):501–6.
29. Sangeeta J, Nair IN, Aparna I B, Dhanasekar I N, Prabhu. Prosthetic Rehabilitation of Hemimandibulectomy Defect with Removable Partial Denture Prosthesis Using an Attachment-Retained Guiding Flange. *Contemporary Clinical Dentistry.* 2018;.
30. Koralakunte PR, Shamnur SN, Iynalli RV, Shivmurthy S. Prosthetic management of hemimandibulectomy patient with guiding plane and twin occlusion prosthesis. *J Nat Sci Biol Med.* 2015;6(2):449–53.
31. Jain L, Aeran H, Sharma N. Prosthetic management of hemimandibulectomy patient . *Int J Oral Health Dent.* 2021;3(3):195–8.

Author biography

Aishwarya Soni, Post Graduate Student  <https://orcid.org/0009-0006-6670-0976>

Shreyans Damade, Reader  <https://orcid.org/0000-0003-3490-8490>

Swapnil Parlani, Professor and HOD

Aishwarya Bisen, Post Graduate Student  <https://orcid.org/0009-0001-0733-9758>

Cite this article: Soni A, Damade S, Parlani S, Bisen A. A systematic review on prosthodontic rehabilitation of hemimandibulectomy patients. *IP Int J Ocul Oncol Oculoplasty* 2024;10(1):6-14.