

Synovial sarcoma involving lacrimal gland: A rare clinical entity

Syed Mehbub Ul Kadir

Consultant, Department of Orbit & Ophthalmic Plastic Services, Bangladesh Eye Hospital, Dhaka and Sk. Fazilatunnesa Mujib Eye Hospital & Training Institute, Bangladesh

Email: mehbubkadir@gmail.com

Abstract

Purpose: To report a rare case of synovial sarcoma in the lacrimal gland fossa of the orbit.

Patient and methods: A female 70-years in age has presented to the department of orbit and ophthalmic plastic services of tertiary care eye hospital with eccentric proptosis of right eye of one month duration and pain for the past one week. Clinical examination revealed fullness in the right lacrimal gland region. CT scan of the orbit has shown a mass lesion in the fossa of the lacrimal gland. Its margin is irregular and erosion of lateral wall and roof of the orbit is noted. From the clinical picture and imaging, diagnosis of malignant tumor of the lacrimal gland was made. The tumor was excised through lateral orbitotomy. Histopathology and immunohistochemistry revealed that the tumor is synovial sarcoma.

Conclusion: Synovial sarcoma is a very rare lacrimal gland malignant tumor in the orbit. Immunohistochemistry is very important to confirm the diagnosis.

Key words: Synovial sarcoma, Histopathology, Immunohistochemistry

Introduction

Sarcoma is rare malignant tumor of the orbit except rhabdomyosarcoma in infants and young children.¹ Synovial sarcoma (SS) is one of the common soft tissue malignancies in the adolescents and young adults.² Synovial sarcoma can occur anywhere in soft part of the body and most predominate in the leg, thigh or around the knee (70%-80%), only 1-10% involve the head and neck region.^{3,4,5,6} The tumors often near a joint, tendon and bursa. It accounts 8% of all soft tissue sarcomas.^{1,2} The peak of incidence is in the 3rd decade and males are affected more often than females (male/female ratio around 1.2:1).^{7,8} Despite its name, it is not histogenetically derived from the synovium.⁹ The most common benign tumor of lacrimal gland fossa is pleomorphic adenoma of the lacrimal gland (57%) and most common malignant tumor is adenoid cystic carcinoma (38%) of the lacrimal gland.¹⁰ Synovial sarcoma of the orbit is very rare clinical entity. In our experience, no such tumor is diagnosed in the orbit. We report a rare case of synovial sarcoma of the lacrimal gland fossa in the orbit and underwent surgical removal of the lesion through lateral orbitotomy followed by histopathological examination and immunohistochemistry.

Case report

A female 70 years in age was seen in the department of orbit and ophthalmic plastics of a tertiary eye hospital with eccentric proptosis of right eye of one month duration and intermittent pain for the past one week. She also complained of gradual dimness of vision of both eyes since 6 months. She did not give any history of diplopia, ocular trauma and ocular surgery. She had bilateral asymmetrical drooping of the eyelid but she didn't aware of it. She had no diabetes, hypertension, bronchial asthma, no known drug allergy. Inspection revealed that fullness in the lacrimal gland region of right orbit, non-pulsatile eccentric proptosis of the right eye, the eyeball pushed downwards and inwards, ocular motility was mild restricted in up gaze and abduction in right eye and full in all gazes of left eye, pupil was normal in size and reacting to light, valsalva maneuver was absent, mild ptosis (MRD1+D2: +2+5) was in right eye and moderate ptosis (MRD1+d2: +0.5+5) in left eye. On palpation, we found a mass which was 2.5×1.2 cms, nodular in shape, irregular surface, tender, firm in consistency in the supero-temporal quadrant of right orbit (lacrimal gland fossa). The proptosis of right eye was 6 mm by Hertel's exophthalmometry, the right eye was displaced horizontally 3 mm and vertically 2 mm. Hypoesthesia was present over the skin of the lacrimal gland, supero-lateral part of brow and

adjacent forehead skin along the supply of lacrimal nerve. Slit lamp examination of anterior segment revealed immature cortical cataract in both eye and vascularized opacity at superior part of cornea. Schirmer's test-1 was 10 mm in right eye and 12 in left eye. Lacrimal excretory apparatus system was patent. IOP was 12 in both eye by GAT. Posterior segment was normal study in both eyes. General examination and systemic examination showed normal study. Our clinical diagnosis was malignant tumor of the lacrimal gland.

CT scan of the orbit has shown a mass lesion in the fossa of the lacrimal gland. It's margin are irregular and erosion of lateral wall and roof of the orbit is noted. So, the imaging diagnosis is malignant lesion in the lacrimal gland.

The management plan score based on the clinical picture and imaging study of the tumor in the lacrimal gland fossa was - 2. Hence, our diagnosis was malignant tumor of the lacrimal gland fossa. On investigation, the haemogram, blood sugar, liver and kidney function were essentially normal.

The patient was consented for surgery. The tumor was excised through modified lateral orbitotomy. We had sent the excised tissue for histopathological & immunohistochemistry examination. Histopathology and immunohistochemistry revealed that the tumor is synovial sarcoma.

Histopathological examination report

Gross appearance showed brownish fragment of tissue of 2.8×1 cms. Cut section shows solid, firm & gray-white in appearance.

Microscopic evaluation revealed well demarcated tumor mass with fibrous capsule composed of spindle cells having plump uniform nuclei arranged in irregular fascicles. Vascularity is prominent with narrow irregular lumened arborizing blood vessels, No giant cells are seen. No significant mitotic figures present. Tumors shows thick fibrotic capsule. Lobules of normal acinar tissue are seen at periphery. There is no evidence of glandular differentiation, haemorrhage or necrosis. Features suggestive of synovial sarcoma

Immunohistochemistry (IHC markers) for further confirmation

IHC: CD34 in paraffin block, IHC- negative, BCL-2, Tissue/paraffin block -positive, Smooth muscle actin, IHC- negative, KI-67 Tissue/paraffin block- positive, Pan Cytokeratin IHC: Negative. Impression: synovial sarcoma

Following HPE & IHC confirmation, we referred to the patient whether the lesion is primary or secondary. The internist reported that there is no any abnormality in other system. So the lesion was primary synovial sarcoma. Finally, we referred the patient to oncologist for further management. The oncologist gave radiotherapy to the patient. Now patient condition is satisfactory and no recurrence in 6 months follow up.

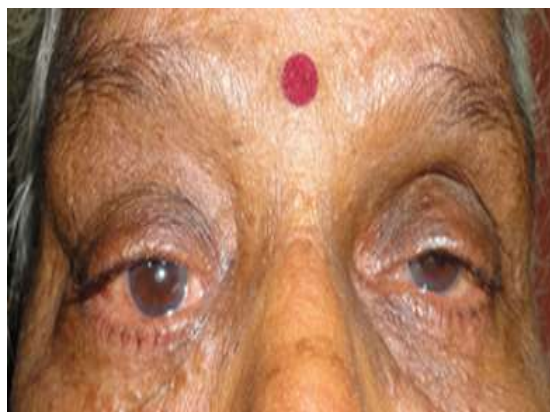

Fig. 1: Mass in the superotemporal quadrant of the right orbit

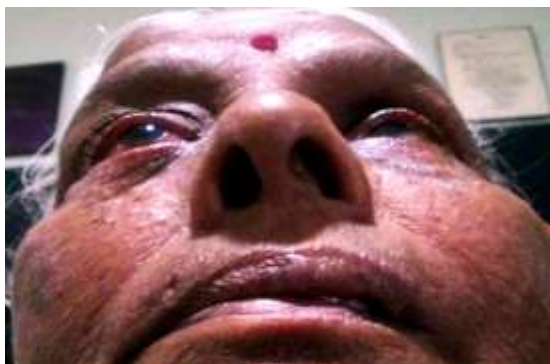

Fig. 2: Worms eye view

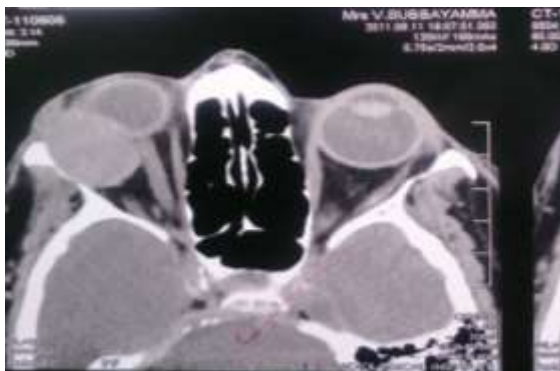

Fig. 3: Axial view of CT scan of orbit showing round shaped mild enhancement soft tissue mass of right lacrimal gland with erosion of bone

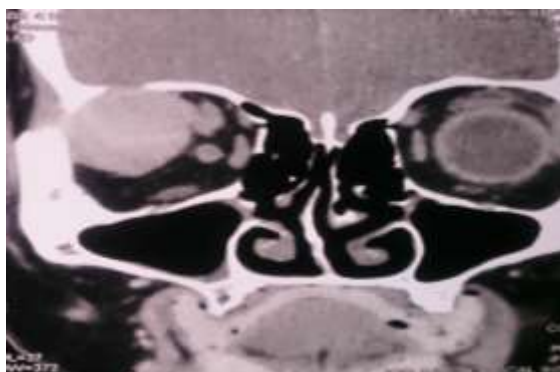


Fig. 4: Coronal view of CT scan of orbit revealed round shaped soft tissue lesion involving the lacrimal gland with erosion superior and lateral wall of the right orbit



Fig. 5: Photomicrograph of Histopathology & Immunohistochemistry of Synovial Sarcoma

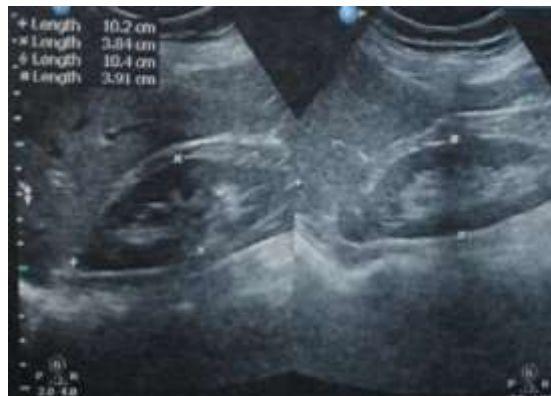

Fig. 6: Normal study of USG of the Abdomen

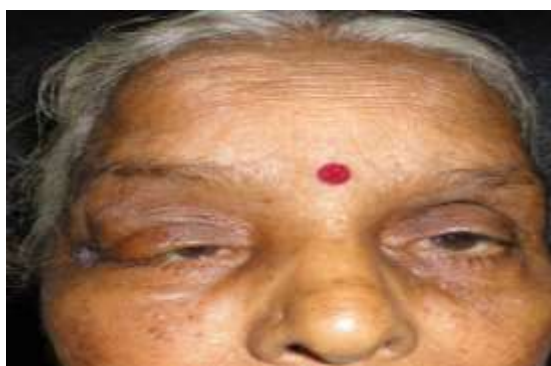

Fig. 7: Postoperative status of the patient

Discussion

Synovial sarcoma account for less than 1% of all malignant tumors and 2% of all cancer-related deaths but in children soft tissue sarcomas represent about 8% of all malignancies.^{1,2,8} Synovial sarcoma occurs primarily in the para-articular regions of the extremities and paravertebral areas of the neck. The most typical presentation is palpable deep-seated swelling associated with pain or tenderness. Other clinical symptoms are rare and depend on the location of the tumor.¹¹

Histopathologically, synovial sarcoma can be categorized as a classical biphasic type (with distinct epithelial and spindle-cell components in varying proportions), a monophasic fibrous type (without epithelial components) and poorly differentiated synovial sarcoma. Synovial sarcoma is positive for keratin, vimentin, CD-99 and BCL2 on immunohistochemistry.¹²

We believe that this is the first reported case of synovial sarcoma in the lacrimal gland fossa and 4th reported case of synovial sarcoma of the orbit. After histopathologic and immunological diagnosis, we referred the patient to internal medicine specialist for evaluation of primary or

secondary sarcoma. The internist reported that there is no any pathology on clinical & radiological assessment in other organ of the body. So, the tumor was primary synovial sarcoma of the lacrimal gland fossa. Synovial sarcoma of the orbit is a rare occurrence, but there are isolated reports in the literature.

Shukla PN et al.¹¹ reported a case primary orbital calcified synovial sarcoma in a 32-year-old woman presented with a progressively increasing recurrent swelling of the left eye. An orbital tumor was detected, immunohistochemistry and electron microscopy confirmed the tumor as a synovial sarcoma.

Votruba M et al.¹³ described Primary monophasic synovial sarcoma of the conjunctiva in a 29 year old man presented with a 4 month history of a growing mass in the conjunctiva at the medial canthus of the right eye. Gross appearance was of a pink, fleshy, soft tumor, 10 mm in diameter, with a prominent feeding blood vessel. Computed tomograph (CT) scan showed no deep extension of the mass. Histology showed a spindle cell tumor with collagen bundles and frequent vessels in the stroma and immunohistochemistry showed widespread EMA staining and scattered keratin positive cells. Stain for CD-99 and bcl-2 was positive. These were characteristic features of a monophasic synovial sarcoma.

Hartstein ME et al.¹⁴ described the clinicopathologic and immunohistochemical features and treatment of a rare case of primary synovial sarcoma of the orbit in a 14-year-old young man. The diagnosis was confirmed by demonstration of a specific chromosomal translocation by polymerase chain reaction studies.

Ratnatunga N et al.¹⁵ reported primary biphasic synovial sarcoma of the orbit in a young adult as a slowly enlarging sub-conjunctival mass. It is noteworthy at this juncture that the present case was also a slow-growing biphasic synovial sarcoma in a 21 year old woman. Primary synovial sarcoma of the kidney, primary cutaneous synovial sarcoma, and primary cardiac sarcoma are other unusual manifestations.

The role of irradiation in the management of synovial sarcoma was evaluated by Fontanes J et al.¹⁶ who concluded that addition of radiotherapy is of questionable benefit for patients with adequate surgical resection and good tumor characteristics (IRS Gr I and II); however, for lesions that have been resected incompletely, there is evidence that irradiation may provide a durable

local control. The case reported here was treated with postoperative adjuvant radiotherapy in view of the incomplete resection.

Shmookler et al.¹⁷ presented a clinicopathologic study of 11 cases of orofacial synovial sarcoma, observed a median follow-up of 2.9 years and interestingly noted that all the fatalities were associated with extensive, often deeply invasive, local recurrences. The mean survival in this group was 5.6 years. Greater emphasis was placed on irradiation and chemotherapy in the management of fatal cases. The authors conclude that surgical resection is the primary modality of treatment, but complete resection in the head and neck is rarely feasible, necessitating adjuvant radiotherapy to reduce local failure; however, this will have to be confirmed in larger studies.

So, histopathology and immuno-histochemistry is essential diagnostic tool to confirm the diagnosis of orbital tumor in respect of age and sex. Surgery is the primary treatment of choice. Radiotherapy and or chemotherapy may be used as adjunctive therapy.

Conclusion

Synovial sarcoma is a very rare malignant tumor in the orbit. Involving the lacrimal gland is the first reported case in our knowledge till submission of this article. Histopathologic examination, immuno-histochemistry and polymerase chain reaction (PCR) is very important tools to confirm the diagnosis of synovial sarcoma.

Acknowledgment

The author would like to thank Professor Dr M. Subrahmanyum, Professor, Dept. of Ophthalmology, Maharajah's Institute of Medical Sciences, Vizianagaram, A.P., India for his guidance in diagnosis, managing and reporting this case.

References

1. Shields JA, Bakewell B, Augsburger JJ, Flanagan JC. Classification and incidence of space-occupying lesions of the orbit. A survey of 645 biopsies. *Arch Ophthalmol* 1984;102:1606-11.
2. Schmidt D, Thum P, Harms D, Theuner J. Synovial sarcoma in children and adolescents: A report from Kiel Pediatric Tumor Registry. *Cancer*. 1991;67:1667-72.
3. Roth JA, Enzinger FM, Tannenbaum M. Synovial sarcoma of the neck: a follow-up study of 24 cases. *Cancer* 1975;35:1243-53.

4. Flieder DB, Moran CA. Primary cutaneous synovial sarcoma: A case report. *Am J Dermatopathol.* 1998;20(5):509–12.
5. Enzinger FM, Weiss SW. *Soft tissue tumors.* 3rd ed. St. Louis: Mosby, 1995.
6. Machen SK, Easley KA, Goldblum JR. Synovial sarcoma of the extremities: a clinicopathological study of 34 cases, including semi quantitative analysis of spindled, epithelial and poorly differentiated areas. *Am J Surg Pathol.* 1999;23:268–75.
7. Fisher C. Synovial sarcoma. *Ann Diagn Pathol.* 1998;2:410–21.
8. Ladenstein R, Treuner J, Koscielniak E, et al. Synovial sarcoma of childhood and adolescence: report of the German CWS-81 study. *Cancer.* 1993;71:3647-55.
9. Fletcher CDM, McKee PH. *Pathobiology of soft tissue tumors.* Edinburgh: Churchill Livingstone, 1990.
10. Rootman J, White VA, Katan HA. *Tumors of the lacrimal gland. Diseases of the Orbit: A Multidisciplinary Approach.* 2nd ed. Lippincott Williams & Wilkins. 2003;343-79.
11. Shukla P.N., Pathy S, Sen S, Purohit A, Julka P K et al., 'Primary orbital calcified synovial sarcoma: A case report', *Orbit, Swets & Zeitlinger,* 2003;22(4):299-303.
12. Van de Rijn, Barr FG, Xiong QB, Hedges M, Shipley J, Fischer C. Poorly differentiated synovial sarcoma: An analysis of clinical, pathologic and molecular genetic features. *Am J Surg Pathol.* 1999;23:106–112.
13. Votruba M, Hungerford J, Cornes P G S, Mabey D and Luthert P. Primary monophasic synovial sarcoma of the conjunctiva. *Br J Ophthalmol.* 2002 December; 86(12):1453–54.
14. Hartstein ME, Silver FL, Ludwig OJ, O'Connor DM. Primary synovial sarcoma. *Ophthalmology.* 2006 Nov;113(11):2093-6.
15. Ratnatunga N, Good lad JR, Sankarakumaran N, et al. Primary biphasic synovial sarcoma of the orbit. *J Clin Pathol.* 1992;45:265–67.
16. Fontanesi J, Pappo AS, Parnam DM et al. Role of irradiation in management of synovial sarcoma: St. Jude Children's Research Hospital Experience. *Med-Pediatr Oncol.* 1996;26(4):264–67.
17. Shmookler BM, Enzinger FM, Brannon RB. Orofacial synovial sarcoma. A clinicopathologic study of 11 cases and review of the literature. *Cancer* 1982;50:269-76.