

Content available at: <https://www.ipinnovative.com/open-access-journals>

IP International Journal of Ocular Oncology and Oculoplasty

Journal homepage: <https://ijooo.org/>

Case Report

Bilateral proptosis with hypertelorism - An unusual presentation of extensive allergic fungal sinusitis

Nirupama Damarla^{1*}, Madhavi Chevuturu¹, Hymavathi Bommiseti¹,
Sanjay Reddy Tadisina¹, Satyanarayana Reddy G¹, Sridhar Reddy Dandala²,
Vinod Kumar Gonuru², Likhita Reddy P¹, Alekya Santoshi M¹, Usha Rani Eslavath¹

¹Dept. of Ophthalmology, Apollo Institute of Medical Sciences and Research, Hyderabad, Telangana, India

²Dept. of ENT, Apollo Institute of Medical Sciences and Research, Hyderabad, Telangana, India



ARTICLE INFO

Article history:

Received 09-10-2023

Accepted 04-11-2023

Available online 01-02-2024

Keywords:

Allergic fungal rhinosinusitis (AFRS)

Proptosis

Hypertelorism

ABSTRACT

Allergic fungal rhinosinusitis (AFRS) is one of the most common form of fungal sinusitis. It is a hypersensitivity reaction to fungal infection. The patients are either atopic or immunocompetent. Such patients suffer from rhinosinusitis. The allergic mass is expanding in nature and this results in bony remodelling. It also involves the adjacent structures. Ophthalmological complications occur when the mass involves orbit. These complications include diplopia, telecanthus, proptosis, malar flattening, epiphora, asthenopia and even visual loss.

The diagnosis can be made using radiological imaging. Histopathological examination is needed to confirm the diagnosis. The treatment of AFRS includes both surgical and medical therapy. This case report demonstrates a rare presentation of the non-invasive AFRS with bilateral proptosis with hypertelorism. The patient showed a drastic improvement after endoscopic sinus surgery, oral anti fungal medication, oral steroids and nasal saline irrigation.

This is an Open Access (OA) journal, and articles are distributed under the terms of the [Creative Commons Attribution-NonCommercial-ShareAlike 4.0 License](https://creativecommons.org/licenses/by-nc-sa/4.0/), which allows others to remix, tweak, and build upon the work non-commercially, as long as appropriate credit is given and the new creations are licensed under the identical terms.

For reprints contact: reprint@ipinnovative.com

1. Introduction

Allergic fungal rhinosinusitis (AFRS) is one of the most common form of fungal sinusitis. It is due to the hypersensitivity reaction to fungal infection.^{1,2} The patients are atopic or immunocompetent. The ophthalmic manifestations are common in these patients.³ This article showed a rare complication of AFS that presented with bilateral proptosis and hypertelorism in a young immunocompetent patient.

2. Case Report

A 20-year-old male was referred to Ophthalmology OPD from ENT department in view of bilateral protrusion of eyes.

The patients chief complaints were bilateral nasal obstruction since 6 months and protrusion of eyeball since 2 months. To start with patient had intermittent nasal obstruction with watery nasal discharge. The patient started mouth breathing since 5 months and snoring since 3 months. There was decreased sense of smell since 3 months.

The patient complained of decreased/blurred vision in the Left eye since 15 days. There was no history of headache, diplopia, pain on ocular movements. The patient did not have history of atopy, asthma.

* Corresponding author.

E-mail address: dr.mandiganirupama@gmail.com (N. Damarla).

But, the patient lived in a place where there were a lot of pigeons.

2.1. There was no significant past history.

Examination done by ENT surgeon revealed that the patient was afebrile with fully intact sensorium. On performing sinonasal endoscopy there were multiple polyps bilaterally. The polyps were occluding both the nasal cavities. There was no paranasal sinus tenderness. Examination of oral cavity and oropharynx was normal.

2.2. Cranial nerve examination

Olfactory nerve: Anosmia was detected.

Optic nerve: Diminished vision in the Left Eye.

Rest of the cranial nerve functions were normal.

2.3. On ocular examination

Visual acuity in the right eye (RE) was 20/20, in the left eye(LE) it was 20/60.

Colour vision in the RE was 17/17 and in the LE it was 1/17 on Ishihara chart.

There was hypertelorism and bilateral proptosis (25 mm both eyes) with lateral flare. Figure 1

Interpupillary distance - 77mm

MRD 1 - RE- 5mm LE-5mm

MRD 2 - RE- 6.5mm. LE-7mm

Inner canthal distance was 42 mm.

Restriction of abduction was noted in both eyes (BE).

On slit lamp examination

Cornea was clear, Anterior chamber was deep, Iris normal colour and pattern, Lens was clear in both the eyes.

Pupil in the RE was normal and reacting to light while pupil in the LE had RAPD (Relative afferent pupillary defect).

Fundus examination was done using 90 D lens and slit lamp.

RE fundus was normal, LE fundus revealed hyperemic disc with obliterated optic disc cup. Rest of the fundus was normal.

Complete blood count, electrolytes, thyroid stimulating hormone, erythrocyte sedimentation rate and C-reactive protein were within normal limits.

MRI Brain with contrast was done which showed soft tissue opacification of all paranasal sinuses and bilateral nasal cavities with sinus expansion. There were mild focal areas of meningeal enhancement in the anterior frontal and temporal regions. Figures 4, 5 and 6

There was hypertelorism and bilateral proptosis secondary to expansion of ethmoid sinuses, with lateral displacement of bilateral medial recti. There was mild compression of frontals lobe by expanded frontal sinus. Thinning of all walls of paranasal sinuses with focal areas of dehiscence, predominantly involving the frontal

and ethmoid sinuses. The cerebral parenchyma appeared normal, with no obvious focal pathology. Rest of both the orbits and soft tissues of the face appeared normal.

The patient underwent bilateral endoscopic polypectomy and functional endoscopic sinus surgery (FESS) for frontal, ethmoidal and sphenoidal sinuses. All the debris was cleared from the sinuses. Nasal polyp was sent for Histopathological examination and debris was sent for culture and sensitivity. Fungal culture and sensitivity revealed *Aspergillus* species growth.

The patient improved significantly after the surgery, there was improvement in both visual acuity and colour vision in the LE. Figure 2 Proptosis also resolved, and the paranasal sinuses were clear. The patient was discharged with oral voriconazole and topical corticosteroid and saline irrigations.

Patient was asked to come for follow-up after one week.

After one week Post FESS.

Visual acuity in the LE improved from 20/60 to 20/20.

Colour vision improved to 6/17 from 17/17 on Ishihara's chart.

Pupils were normal in size and reacting to light.

Interpupillary distance: 75mm (It was 77mm preoperatively)

MRD1 in the RE and LE were 4 mm.

MRD2 in the RE and LE were 5mm and 5.5 mm.

Proptosis: RE-23mm. LE -22mm.

The patient was reviewed again after 1 month.

In that visit the patients IPD was 72 mm.

Proptosis in the 22mm in both eyes.

Then six weeks after surgery patient came for review. Figure 3

Visual acuity was 20/20 in both eyes, colour vision was 17/17 in RE and 6/17 in LE.

Proptosis was 21 mm in the RE and 22 mm in the LE.

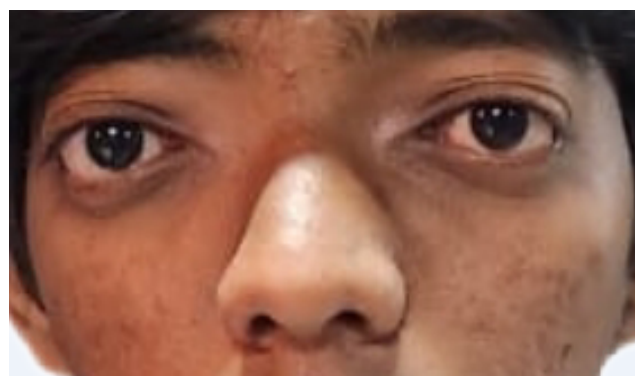


Figure 1: Showing bilateral proptosis and hypertelorism

3. Discussion

There is an increase in awareness regarding allergic fungal sinusitis (AFS) over past few years.^{4,5} AFS is

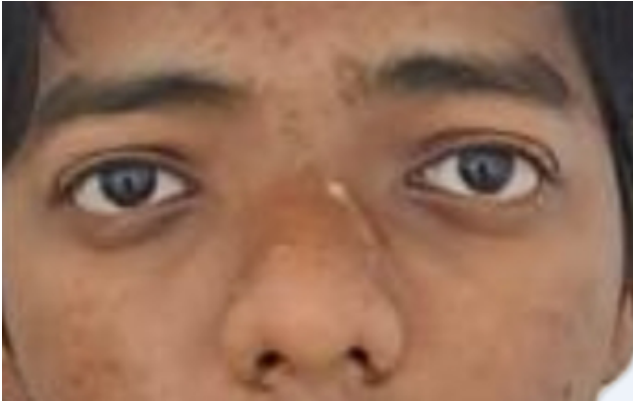


Figure 2: Showing post op day 1.



Figure 3: Showing improvement 1 month after surgery.

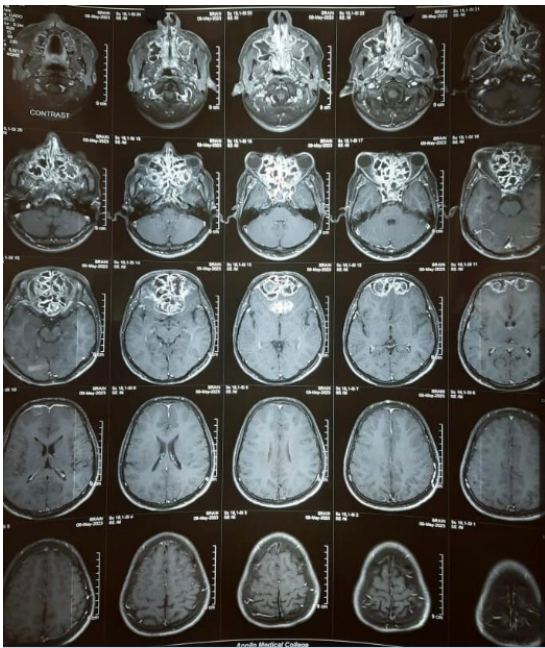


Figure 4: Showing MRI Brain with contrast which showed soft tissue opacification of all paranasal sinuses and bilateral nasal cavities with sinus expansion.

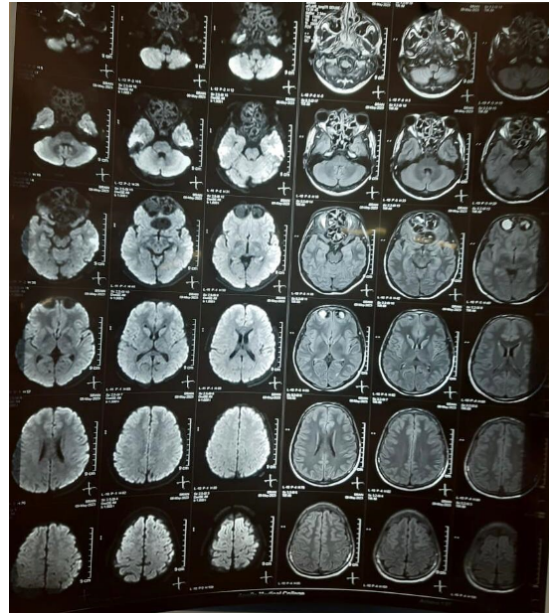


Figure 5:

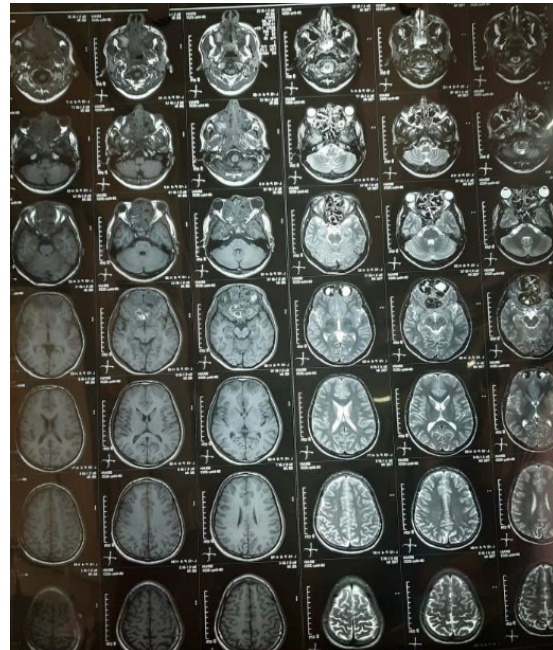


Figure 6: Showing bilateral proptosis secondary to expansion of ethmoid sinuses, with lateral displacement of bilateral medial recti.

thought to be because of an allergic reaction to fungi (dematiaceous species) present in the environment. Patients have a history of allergic rhinitis. Adolescents and young adults are commonly affected by AFS. It occurs in immunocompetent hosts whereas invasive fungal infections affects immunocompromised individuals. Thick fungal debris and mucin, develops in the sinus cavities. This debris must be surgically removed to eradicate the inciting allergen. Medical management includes anti-inflammatory therapy and immunotherapy. They help prevent the recurrence.^{6,7} The genus of dematiaceous fungi which cause allergic fungal sinusitis (AFS) includes *Bipolaris*, *Curvularia*, *Alternaria*, *Fusarium*, *Aspergillus*.

AFRS usually presents with progressive nasal obstruction and multiple nasal polyps. These patients have chronic signs and symptoms of rhinosinusitis which sometimes have been lasting for months or even years. They do not visit the hospital until they develop symptoms of complete nasal obstruction, visual loss or gross facial disfiguration.^{3,8,9} The accumulation of mucin has relatively unique and predictable characteristics. The involvement of adjacent structures is due to the expanding mucin. This causes ischemia and weakness of bone, making it susceptible to mechanical stress and necrosis, by exerting pressure that compromising the bone blood supply.¹⁰

The expansion takes place in the direction of the least resistance and the location of the disease. The lamina papyracea is the most common location of bone erosion, and the orbit is the most common location for extra-sinus disease spread.^{11,12} The presence of orbital periosteum is a deterrent to spread of these lesions into the orbit. The spread of infection takes place through pre-existing anatomical channels present in the orbit.

These pre-existing channels include:

1. Valveless ethmoidal veins
2. Foramina through which ethmoidal arteries pass through
3. Dehiscences in the lamina papyracea
4. Very thin floor of frontal sinus.

When this allergic mucin involves the orbit, bony remodeling and decalcification will occur. This causes signs and symptoms such as visual loss or facial disfiguration. Complications of orbital invasion includes proptosis, telecanthus, vision loss, diplopia. The most manifestation being unilateral proptosis.^{2,3,12,13}

Diminished vision or loss of vision can occur due to the inflammatory reaction of the adjacent structures affecting the optic nerve. This results in infarction of the optic nerve caused by increased intra-orbital pressure which may also lead to thrombophlebitis within the valveless orbital veins or even occlusion of the central retinal artery which is an ocular emergency.^{2,10,12} Facial disfiguration is more common in young patients. This is because the facial skeleton growth

is at its highest rate at this age. During this age, the growing bony structures are more susceptible to dysmorphic changes by the external forces. In AFRS the allergic mass causes bony erosion as well as skeletal changes in the sinus walls. The mass also invades adjacent structures such as intracranial or intra-orbital cavities. The intra orbital invasion causes proptosis as the most common result.¹¹

In cases where base of the skull is involved, there can be intracranial extension which may give rise to frontal lobe compression leading to change in personality and behavior, or even an intracranial abscess.¹⁰

CT scan of paranasal sinus is the preferred investigation of choice for the diagnosis of AFRS. Findings on CT scan usually show irregular hyper dense masses involving multiple sinuses. The most common sinus affected is ethmoid sinus, followed by the maxillary, frontal and sphenoid sinuses, respectively. MRI scan reveals enhanced sinus mucosa and masses with markedly decreased intensities resembling air on T2 images. The radiological findings obtained from CT and MRI are characteristic of dense extra-mucosal mucin. The definitive diagnosis is reached by histopathological examination of mucosa and mucin.^{12,13} Histopathological findings of mucus are the presence of fungal elements, Charcot–Leyden crystals and eosinophils. Cultures of the mucin show dematiaceous fungi species growth most of the time.^{11,12}

The treatment of AFRS should be combined with surgical and medical therapy, which consists of sinuses surgical decompression, corticosteroid and nasal saline irrigation. Adjuvant medical therapy aims to decrease inflammation, atopy and antigen exposure, therefore, the immunoreactions. In the absence of this combination, the recurrence rates of AFRS reach up to 100%.^{10–12,14}

Timely intervention can save the patient from complications. In our case there was a drastic improvement in visual acuity and the amount of proptosis immediately after the surgery.

Also in our case the patient was residing in a place which also had a pigeons habitation. Several studies have shown that pigeon breeding is associated with hypersensitivity pneumonitis, pigeon breeder's disease, bronchiolitis, allergic asthma, and nasal symptoms as obstruction and hyper-secretion, sinusitis.¹⁵

4. Conclusion

Ophthalmic manifestations are fairly common in patients with AFR. Patients with orbital involvement will always seek the help of ophthalmologist in the first place. Ophthalmologists should be aware of this potential problem and refer the patient to the Otorhinologist for timely treatment.

This case report demonstrates a rare presentation of AFRS with bilateral proptosis and hypertelorism. The patient had a drastic improvement of vision and resolution

of the proptosis and hypertelorism after it was managed with Endoscopic sinus surgery, oral antifungals and nasal irrigation with saline.

This case also reinforces that further studies are needed to understand factors behind allergies, asthma and sinusitis which are directly related to pigeon droppings as it gives us clues for better diagnosis.

5. Source of Funding

None.


6. Conflict of Interest

None.

References

1. Almomen A, Al-Enzi O, Alshammari R, Molani F, Alshakhs AA, Ameer A, et al. Bilateral proptosis-an unusual presentation of extensive allergic fungal sinusitis. *J Surg Case Rep.* 2022;2022(10):rjaa564. doi:10.1093/jscr/rjaa564.
2. Alsagoob AA, Taguri AH, Al-Ahmary AY, Sari LM. Asthenopia as the presenting symptom in advance allergic fungal sinusitis. *Saudi J Ophthalmol.* 2012;26(3):339–41.
3. Ramamoorthy BT. Ophthalmic manifestations of allergic fungal sinusitis a retrospective study. *Otolaryngology Online Journal.* 2013;3. Available from: <https://www.alliedacademies.org/articles/ophthalmic-manifestations-of-allergic-fungal-sinusitis-a-retrospective-study.pdf>.
4. Glass D, Amedee RG. Allergic fungal rhinosinusitis: a review. *Ochsner J.* 2011;11(3):271–5.
5. Akhondi H, Woldemariam B, Rajasurya V. Fungal Sinusitis. StatPearls [Internet]. Treasure Island (FL): StatPearls Publishing; 2022.
6. Montone KT. Pathology of Fungal Rhinosinusitis: A Review. *Head Neck Pathol.* 2016;10(1):40–46.
7. Eckhoff A, Cox D, Luk L, Maidman S, Wise SK, Delgaudio JM, et al. Unilateral versus bilateral sinonasal disease: Considerations in differential diagnosis and workup. *Laryngoscope.* 2020;130(4):116–21.
8. Bent JP, Kuhn FA. Diagnosis of allergic fungal sinusitis. *Otolaryngol Head Neck Surg.* 1994;111(5):580–8.
9. Ferguson BJ. Eosinophilic mucin rhinosinusitis: a distinct clinicopathological entity. *Laryngoscope.* 2000;110(5 Pt 1):799–813.
10. Marple BF, Gibbs SR, Newcomer MT, Mabry RL. Allergic fungal sinusitis-induced visual loss. *Am J Rhinol.* 1999;13(3):191–5.
11. Ghegan MD, Lee FS, Schlosser RJ. Incidence of skull base and orbital erosion in allergic fungal rhinosinusitis (AFRS) and non-AFRS. *Otolaryngol Head Neck Surg.* 2006;134(4):592–5.
12. Ikram M, Akhtar S, Ghaffar S, Enam SA. Management of allergic fungal sinusitis with intracranial spread. *Eur Arch Otorhinolaryngol.* 2008;265(2):179–84.
13. Taylor MJ, Ponikau JU, Sherris DA, Kern EB, Gaffey TA, Kephart G, et al. Detection of fungal organisms in eosinophilic mucin using a fluorescein labeled chitin specific binding protein. *Otolaryngol Head Neck Surg.* 2002;127(5):377–8.
14. Marple BF. Allergic fungal rhinosinusitis: current theories and management strategies. *Laryngoscope.* 2001;111(6):1006–19.
15. Madsen AM, White JK, Nielsen JL. Margit Wagtberg Frederiksen. A cross sectional study on airborne inhalable microorganisms, endotoxin, and particles in pigeon coops - Risk assessment of exposure. *Environmental Research.* 2022;204(Pt D):112404. doi:10.1016/j.envres.2021.112404.

Author biography

Nirupama Damarla, Assistant Professor  <https://orcid.org/0000-0001-5557-1124>

Madhavi Chevuturu, Professor

Hymavathi Bommiseti, Associate Professor

Sanjay Reddy Tadisina, Professor and HOD

Satyanarayana Reddy G, Professor

Sridhar Reddy Dandala, Professor and HOD

Vinod Kumar Gonuru, Professor

Likhita Reddy P, Post Graduate

Alekya Santoshi M, Post Graduate

Usha Rani Eslavath, Post Graduate

Cite this article: Damarla N, Chevuturu M, Bommiseti H, Tadisina SR, Satyanarayana Reddy G, Dandala SR, Gonuru VK, Likhita Reddy P, Alekya Santoshi M, Eslavath UR. Bilateral proptosis with hypertelorism - An unusual presentation of extensive allergic fungal sinusitis. *IP Int J Ocul Oncol Oculoplasty* 2023;9(4):214-218.