

Content available at: <https://www.ipinnovative.com/open-access-journals>

IP International Journal of Ocular Oncology and Oculoplasty

Journal homepage: <https://ijooo.org/>

Original Research Article

OSSN: An underrated neoplasia of the eye

Ram Kumar Jaiswal¹, Vanshika Khanna^{1*}, Dipti Wahi¹

¹Dept. of Ophthalmology, Baba Raghav Das Medical College, Gorakhpur, Uttar Pradesh, India



ARTICLE INFO

Article history:

Received 09-11-2023

Accepted 24-12-2023

Available online 01-02-2024

Keywords:

OSSN

CIN

SCC

Squamous neoplasia

ABSTRACT

Background: Ocular surface squamous cell carcinoma (OSSN) is a general term for various conjunctival tumors, including conjunctival intraepithelial neoplasia (CIN) and squamous cell carcinoma (SCC).

Objective: To evaluate the clinico-demographic characteristics and histopathological findings of ocular surface squamous cell carcinoma.

Materials and Methods: eyes of 47 patients aged 21 to 80 years with conjunctival tumors were included in the study and underwent excisional biopsy and subsequent histopathological examination.

Results: Statistically significant associations were found with age, symptom duration, and lesion size ($p < 0.05$).

Conclusion: Benign and preinvasive lesions are more common than invasive lesions.

This is an Open Access (OA) journal, and articles are distributed under the terms of the [Creative Commons Attribution-NonCommercial-ShareAlike 4.0 License](https://creativecommons.org/licenses/by-nc-sa/4.0/), which allows others to remix, tweak, and build upon the work non-commercially, as long as appropriate credit is given and the new creations are licensed under the identical terms.

For reprints contact: reprint@ipinnovative.com

1. Introduction

Ocular surface squamous cell carcinoma (OSSN) is a general term for a group of conjunctival tumors that includes conjunctival intraepithelial neoplasia (CIN) and squamous cell carcinoma (SCC).¹ OSSN can be classified as mild, moderate, or severe depending on the degree of dysplastic epithelial involvement. Histopathological invasive OSSN or SCC shows foci of infiltrating cells that penetrate the epithelial basement membrane and spread into the conjunctival stroma. OSSN presents with nonspecific symptoms (eye redness and inflammation), but larger lesions can cause visual impairment that obstructs the visual axis and causes astigmatism.^{1,2} Clinically, this disease is suspected in patients who have a conjunctival mass that is elevated, increases in size, and enlarges the feeding vessels.¹ The gold standard for confirming the diagnosis and histological classification is biopsy with histological evaluation.³ Because these tumors are relatively rare and

there is relatively little data regarding these lesions, this study was designed to evaluate the clinico-demographic characteristics and histopathological findings of OSSN.

2. Objectives of the Study

To evaluate clinico-demographic characteristics, and histopathology finding of ocular surface squamous neoplasia.

3. Materials and Methods

This was a 24-month prospective observational study of the eyes of 47 conjunctival tumor patients aged 21 to 80 who visited our outpatient clinic. Institutional research and ethics committee approval was obtained before starting this study. The study was conducted in accordance with the principles of the Declaration of Helsinki .

* Corresponding author.

E-mail address: ramkumarjaiswal35@yahoo.com (V. Khanna).

3.1. Inclusion criteria

All patients presenting with conjunctival masses suspicious of OSSN or symptomatic conjunctival growths, of basal diameter <15mm, between the age 21-80 years and willing to give written informed consent and for at least 2 months of follow-up.

3.2. Exclusion criteria

Patients <16 years of age, pregnant or lactating females; history of previous surgery or topical chemotherapy in the presenting eye; masses greater than 15mm in basal diameter or invading adjacent structures (other than cornea or sclera); neurological conditions that prevented study investigations; heritable conditions that predispose to OSSN (xeroderma pigmentosum, oculocutaneous albinism); and primary acquired melanosis and patients refusing to give consent or follow up were excluded from the study.

Slit-lamp examination was performed to determine the clinical features, dimensions, and morphology of the mass. Dimensions were recorded as the largest vertical dimension, from which surface area was calculated. Limbal clock time involvement was recorded. Photographs of the anterior segment were taken to document the clinical features and pigmentation [Figure 1]. Routine blood tests included HIV testing including complete blood count, RBS, CD4 count and if reactive, viral load, HbsAg, and HCV. Blood pressure measurements and CXR were performed on all subjects.

All patients underwent excisional biopsy with 2 mm clear margin followed by histopathologic examination to determine the diagnosis [Figure 2].

3.3. Data analysis

Data analysis was performed using SPSS software (Statistical Package for Social Sciences, version 22, SPSS Inc, Chicago, IL). Statistical data were expressed as mean ± standard deviation (mean ± SD). Frequencies and percentages were expressed as descriptive statistics. Comparisons of data were performed using Pearson’s chi-square test (Fisher’s exact test). A P value < 0.05 was considered statistically significant.

4. Observation and Results

During the study period, a total of 47 subjects were submitted to our department, of which 26 (55.32%) were male and 21 (44.68%) were female. The mean age at onset was 46.67±16.25 years, with a range of 24 to 78 years. By occupation, most of the patients were farmers (20 people) (42.55%), followed by housewives (19 people) (40.43%), students (5 people) (10.64%), and soldiers (3 people) (6.38%). The mean duration of onset was 6.24 ± 4.17 months, ranging from a minimum of 1 month to a maximum of 30 months. In this study, systemic

diseases were identified in 5 (10.64%) patients, including hypertension in 2 (4.26%), diabetes in 1 (2.13%), HIV in 1 (2.13%), and tuberculosis in 1. Lesions were most commonly found in the right eye in 27 patients (57.45%), followed by the left eye in 20 patients (42.55%). Lesions were most commonly found on the temporal side of the limbus in 26 cases (55.32%), followed by the nasal side in 18 cases (38.29%), the inferior side in 2 cases (4.26%), and the upper part in 1 case (2.13%). [Table 1]

Histopathological examination found benign lesions in 15 eyes (31.92%), preinvasive lesions in 23 eyes (48.94%), and invasive lesions in 9 eyes (19.14%). Among the benign lesions, 9 were squamous papillomas (19.15%), 3 were epidermoid cysts (6.38%), 2 were conjunctival nevi (4.26%), and 1 was corneal acanthosis (2.13%). There were. The preinvasive lesions were CIN I in 5 eyes (10.64%), CIN II in 3 eyes (6.38%), and CIN III in 15 eyes (31.92%). Invasive squamous cell carcinoma was found in the patient’s 6 eyes (12.77%) and malignant melanoma was found in 3 eyes (6.38%). We compared 4,444 histopathological findings from these patients with various parameters [Table 2]. A statistically significant association was found with age, symptom duration, and lesion size, with p values of 0.006, 0.007, and 0.047, respectively.

Table 1: Demographic characteristic of study population

		No. of Subjects (n=47)	Percentage (%)
Age	21 - 40yr	16	34.04
	41 - 60yr	21	44.68
	61 -80yr	10	21.28
Gender	Male	26	55.32
	Female	21	44.68
Affected eye	Right	27	57.45
	Left	20	42.55
Occupation	Farmer	20	42.55
	Housewife	19	40.43
	Student	8	17.02
Duration of illness	<3 months	18	38.30
	≥3 months	29	61.70
Site	Temporal	26	55.32
	Nasal	14	29.79
	Inferior	7	14.89
Symptom at presentation	Superior	0	0.00
	Foreign body sensation	19	40.43
	Reduced vision	12	25.53
	Other	16	34.04

5. Discussion

OSSN is more common in young adults. The mean age of our patients was 46.67 ± 16.25 years, ranging from 24

Table 2: Association of histopathological findings in OSSN with various parameters

Variables	Histopathologic findings			p-value
	Benign	Pre invasive	Invasive	
Age(years)				
21-40	9	6	1	0.006
41-60	5	12	2	
61-80	1	3	6	
Occupation				
Farmer	5	11	4	0.86
Housewife	7	9	3	
Other	3	3	2	
Site of lesion				
Temporal	8	13	5	0.96
Nasal	5	7	2	
Inferior	2	3	2	
Superior	0	0	0	
Symptoms				
Foreign body sensation	7	10	2	0.36
Reduced Vision	3	4	5	
Others	5	9	2	
Duration of symptoms				
<3 Months	2	9	7	0.007
≥3 Months	13	14	2	
Size of lesion				
≤1.5 mm	11	10	2	0.047
>1.5 mm	4	13	7	

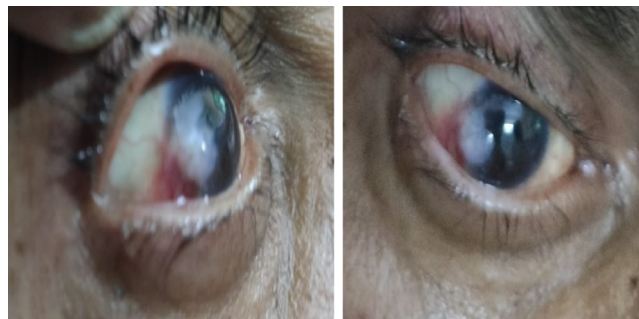


Figure 1: Pre-operative image of a patient with ocular surface squamous neoplasia

years to 78 years, which was consistent with the study by Dandala PP et al.⁴ In this case the mean age was 45.20 years and he ranged from 18 to 78 years, while in Patel et al⁵ the mean age was 48.9 ± 17.95 years and he ranged from 17 to 85 years. This study shows a statistically significant association with the age of the study population ($p < 0.05$) with invasive lesions being more common in older age group. In our study, a male predominance was found (55.32%). This has also been found in many other studies.⁶⁻⁹ The higher incidence of OSSN in men and young adults may be due to increased exposure to UV radiation during outdoor work. By occupation, most of the patients

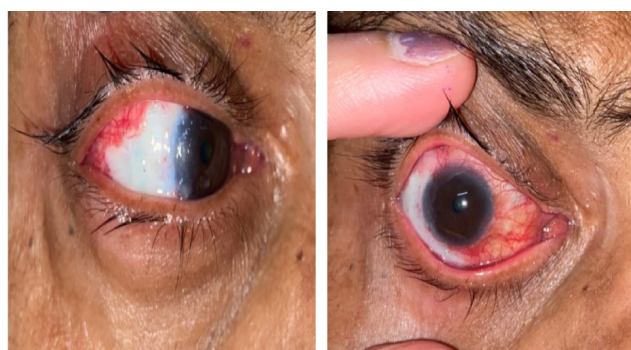


Figure 2: Post-operative image of a patient with ocular surface squamous neoplasia

(42.55%) were farmers, as most of the population in this region earns their living from agriculture and is therefore often exposed to UV radiation during outdoor agricultural activities. It is clear. The mean duration of onset was 6.24 ± 4.17 months, ranging from a minimum of 1 month to a maximum of 30 months. In a study conducted in Delhi, the average duration of symptoms was 1.03 years.⁹ Our study showed a statistically significant association with duration of symptom onset ($p < 0.05$) with a shorter duration of symptom being more prone to invasion.

Although the pathogenesis of OSSN is multifactorial, it is not clear how these factors interact to lead to the development of OSSN. Sun exposure, HPV types 16 and 18 infection, HIV infection, ocular surface damage, chemicals such as trifluridine, arsenic, beryllium or petroleum products, vitamin A deficiency xeroderma pigmentosum, age, heavy smoking, Male gender, immunocompromised status, and mild hair and eye pigmentation are the most common associated factors. All these factors cause genetic damage to proliferating cells, causing basic cellular functions such as cell division and differentiation to become uncontrolled, causing cells to become tumors. The degree of risk depends on the type of UV radiation, the intensity of exposure, the duration of exposure, and the amount of the light-absorbing protective substance melanin in a person's body. UV-B causes the formation of pyrimidine dimers within DNA and also damages the nucleotide excision repair pathway, which plays an important role in DNA repair, contributing to the development of various skin and ocular surface cancers. It is believed that this is the cause.

HPV (types 16 and 18), a DNA virus, has been shown to be responsible for the development of several types of cancer, particularly squamous cell carcinoma of the cervix, anogenital area, oropharynx, and ocular surface. In our study, we found that 2.13% of patients had a history of her HIV infection. This is similar to the Delhi study where she was the only patient found to be infected with HIV.^{10,11} In a study by Dandala et al,⁴ approximately 23% of patients in Hyderabad tested positive for HIV, and the median age

of onset was only 34 years. Studies in Africa in particular have shown high rates of HIV and HPV. In these countries, OSSN is also more common in younger age groups. OSSN lesions are more common in the interpalpebral region of the periribular conjunctiva and may extend beyond the limbus to the cornea. Isolated corneal involvement by OSSN is extremely rare. A study in Uganda showed that tumors most often occur in areas of the eye that are exposed to sunlight.¹² The temporal region of the interpalpebral region is more exposed to sunlight and therefore becomes a large collection zone for UV radiation. Showed similar evidence. His OSSN lesions in our study were most commonly found on the temporal side (55.32%), followed by the nasal side (38.29%). This is consistent with another study where 50.44% had nasal lesions and 49.56% had temporal lesions.⁴ A statistically significant association was observed with lesion size ($p < 0.05$), the larger the lesion, the more susceptible it was to invasion.

OSSN usually presents as a circumscribed, gelatinous, sessile, papillomatous lesion with varying degrees of leukoplakia and dilated conjunctival vessels that supply and drain blood to the lesion. In some cases, OSSN may be a diffuse, flat, ill-circumscribed lesion with no obvious tumor, making early diagnosis difficult. In some cases, the lesions may become large enough to cover the entire surface of the eye or, rarely, become pigmented, making them difficult to distinguish from conjunctival melanoma. Histopathological evaluation of lesions after excisional biopsy is the gold standard for OSSN diagnosis. CIN can progress to invasive squamous cell carcinoma with destruction of the epithelial basement membrane and spread to the underlying stromal tissue. Other ocular surface lesions that may clinically mimic OSSN include actinic keratoses, pterygia, echinoids, and actinic granulomas.^{13–15}

Treatments for OSSN range from complete resection of well-defined tumors to chemotherapy for diffuse unresectable disease. Medical alternatives in the form of topical applications, 5-fluorouracil (5FU), mitomycin C (MMC), and interferon (IFN α 2b), have been widely described in the literature. Although complete resection using cryotherapy provides excellent results for localized lesions, newer treatments such as immunotherapy hold promise for larger, unresectable, recurrent lesions.

6. Conclusion

OSSN is more common in young male adults. Lesions occur most often on the temporal side. Benign preinvasive lesions are more common than invasive lesions. Nodular lesions are the most common variant. On histopathological examination, the most common diagnoses were squamous papilloma for benign lesions and invasive squamous cell carcinoma for invasive lesions. CIN can progress to invasive squamous cell carcinoma with destruction of the epithelial basement membrane and spread to the underlying stromal

tissue. Therefore, all OSSN lesions should be carefully evaluated, histopathologically examined, and carefully treated with appropriate resection.

7. Limitation of the Study

The results of this study cannot be applied to general population as the study was limited to a single centre which catered to the population of single ethnic group belonging to a small geographical area. Also, the effect of various environmental factors of different geographical regions were not taken into account.

8. Source of Funding

None.

9. Conflict of Interest

None.

References

1. Lee GA, Hirst LW. Ocular surface squamous neoplasia. *Surv Ophthalmol.* 1995;39(6):429–50.
2. Hollhumer R, Williams S, Michelow P. Ocular surface squamous neoplasia: Population demographics, pathogenesis and risk factors Roland Hollhumer, Susan Williams, Pamela Michelow. *African Vision and Eye Health.* 2020;79(1):a553. doi:10.4102/aveh.v79i1.553.
3. Shields JA, Shields CL, Potter P. Surgical management of conjunctival tumors. The 1994 Lynn B. McMahan Lecture. *Arch Ophthalmol.* 1997;115(6):808–15.
4. Dandala PP, Malladi P, Kavitha. Ocular Surface Squamous Neoplasia (OSSN): A Retrospective Study. *J Clin Diagn Res.* 2015;9(11):NC10–3.
5. Patel S, Pokharel BB, Shah A, Goda MS, Thapa SK. Clinico-Pathological Study of Ocular Surface Squamous Neoplasia in a Tertiary Care Centre of Western Region of Nepal. *J Univ Coll Med Sci.* 1920;7(1):9–13.
6. Kim BH, Kim MK, Wee WR, Oh JY. Clinical and pathological characteristics of ocular surface squamous neoplasia in an Asian population. *Graefes Arch Clin Exp Ophthalmol.* 2013;251(11):2569–73.
7. Shields CL, Demirci H, Karatza E, Shields JA. Clinical survey of 1643 melanocytic and nonmelanocytic conjunctival tumors. *Ophthalmology.* 2004;111(9):1747–54.
8. Chauhan S, Sen S, Sharma A, Tandon R, Kashyap S, Pushker N, et al. American Joint Committee on Cancer Staging and clinicopathological high-risk predictors of ocular surface squamous neoplasia: a study from a tertiary eye center in India. *Arch Pathol Lab Med.* 2014;138(11):1488–94.
9. Meel R, Dhiman R, Vanathi M, Pushker N, Tandon R, Devi S, et al. Clinicodemographic profile and treatment outcome in patients of ocular surface squamous neoplasia. *Indian J Ophthalmol.* 2017;65(10):936–41.
10. Ateenyi-Agaba C. Conjunctival squamous-cell carcinoma associated with HIV infection in Kampala, Uganda. *Lancet.* 1995;345(8951):695–6.
11. Gichuhi S, Macharia E, Kabiru J, Zindamoyen AM, Rono H, Ollando E, et al. Clinical Presentation of Ocular Surface Squamous Neoplasia in Kenya. *JAMA Ophthalmol.* 2015;133(11):1305–13.
12. Waddell KM, Downing RG, Lucas SB, Newton R. Corneo-conjunctival carcinoma in Uganda. *Eye (Lond).* 2006;20(8):839–9.
13. Gurnani B, Kaur K. Ocular Surface Squamous Neoplasia. [Updated 2023 Jul 31]. StatPearls [Internet]. Treasure Island (FL): StatPearls

Publishing; 2023. Available from: <https://www.ncbi.nlm.nih.gov/books/NBK573082/>.


14. Cicinelli MV, Marchese A, Bandello F, Modorati G. Clinical Management of Ocular Surface Squamous Neoplasia: A Review of the Current Evidence. *Ophthalmol Ther.* 2018;7(2):247–62.
15. Alvarez OP, Zein M, Galor A. Management of ocular surface squamous neoplasia: Bowman Club Lecture 2021. *BMJ Open Ophthalmol.* 2021;6(1):e000842. doi:10.1136/bmjophth-2021-000842.

Vanshika Khanna, Senior Resident

Dipti Wahi, Senior Resident

Cite this article: Jaiswal RK, Khanna V, Wahi D. OSSN: An underrated neoplasia of the eye. *IP Int J Ocul Oncol Oculoplasty* 2023;9(4):200-204.

Author biography

Ram Kumar Jaiswal, Professor and Head  <https://orcid.org/0000-0003-1753-292X>