

Content available at: <https://www.ipinnovative.com/open-access-journals>

IP International Journal of Ocular Oncology and Oculoplasty

Journal homepage: <https://ijooo.org/>**Review Article****Pediatric ocular tumors: An overview**Pratibha Sahu¹, Anuradha Raj^{1*}¹Dept. of Ophthalmology, All India Institute of Medical Sciences, Bathinda, Punjab, India**ARTICLE INFO***Article history:*

Received 29-11-2023

Accepted 29-12-2023

Available online 01-02-2024

Keywords:

Dermoid

Proptosis

Leukocoria

Magnetic resonance imaging

ABSTRACT

The majority of ocular tumors in children are benign, but specific malignant neoplasms pose a risk to both life and vision. It's indeed crucial for pediatricians to be aware of ocular tumors in children, as early detection and proper management can significantly impact the child's health and vision. As a result, swift recognition and timely referral of patients to an ocular oncologist are imperative for effective clinical management. This article provides an overview of general concepts surrounding ocular tumors in the pediatric age group, offering brief insights into the clinical features and management of significant tumors affecting the eyelids, conjunctiva, intraocular structures, and orbit.

This is an Open Access (OA) journal, and articles are distributed under the terms of the [Creative Commons Attribution-NonCommercial-ShareAlike 4.0 License](https://creativecommons.org/licenses/by-nc-sa/4.0/), which allows others to remix, tweak, and build upon the work non-commercially, as long as appropriate credit is given and the new creations are licensed under the identical terms.

For reprints contact: reprint@ipinnovative.com**1. Introduction**

Pediatric ocular tumors can be apparent at birth or acquired later in life. They present in a variety of forms ranging from cystic to solid, involving the eye and orbit. Most of them are benign but malignancies such as retinoblastoma and rhabdomyosarcoma are vision- and life-threatening.¹ Hence, early diagnosis is the key to prognostication and successful management of these conditions. Lid and ocular surface neoplasms are easily diagnosed based on history and pattern recognition. Superficial orbital tumors present as subcutaneous or subconjunctival nodules. Larger tumors can extend beyond the globe and present with proptosis, lid retraction, ptosis, globe displacement, vascular congestion, pupil irregularities, strabismus, diplopia, loss of vision, and optic disc edema or atrophy. Erythema, heat, lid edema, pain, and tenderness suggest an inflammatory cause or rapidly growing solid malignancies. Leukocoria is an important feature of an intraocular retinoblastoma and can be associated with ocular misalignment due to sensory strabismus. Age at onset, duration, laterality and clinical

course can guide the differential diagnosis. Medical imaging with ultrasound, computed tomography (CT), magnetic resonance imaging (MRI) and magnetic resonance (MR) angiography are pursued to reach the diagnosis. Excisional biopsy is usually done for encapsulated or cystic masses. Incisional biopsy is used for debulking or confirmation of suspected solid malignancies before starting chemotherapy.

2. Classification of Ocular and Orbital Tumors

The tumors can be classified depending on their location as described in Table 1.

3. Tumors

Eyelid tumors in childhood are typically benign and easily noticeable due to their prominent location. These lesions can stem from factors such as gland blockages, viral infections, vascular malformations, or the extension of orbital tumors anterior to the orbital rim. Among these, chalazion is the most common lid tumor, resulting from a blockage of the meibomian glands. It manifests sub-acutely with surrounding inflammation, resembling preseptal cellulitis.

* Corresponding author.

E-mail address: dranuradha_sagar@yahoo.com (A. Raj).

Table 1: Shows the classification of pediatric tumors

Lid lesions	Ocular surface tumors	Intraocular tumors	Orbital tumors
Chalazion	Papilloma	Retinoblastoma	Cystic lesions 1. Developmental orbital cysts
Hordeolum	Limbal dermoid	Medulloepithelioma	• Choristoma: Dermoid, epidermoid, Teratoma, Congenital cystic eye, Colobomatous cyst 2. Acquired orbital cysts Cystic vascular lesions, Epithelial and appendage cysts, Epithelial implantation cyst, Lacrimal duct cyst, Optic nerve sheath meningocele
Benign epithelial and appendage tumors Syringoma • Porosyringoma • Myoepithelioma • Apocrine hidrocystoma (sudoriferous cyst; originating from a blocked excretory duct of Moll’s apocrine sweat gland) • Eccrine hidrocystoma (derived from lid eccrine sweat gland), • Sebaceous cyst (pilar cyst; retention cyst of the pilosebaceous structure) • Milia (cystic expansion of the pilosebaceous structure due to obstruction of the orifice) Papilloma • Epidermal inclusion cyst • Pilomatrixoma (calcifying epithelioma of Malherbe; a solid or cystic mass derived from hair matrix cells) • Conjunctival inclusion cyst.	Pyogenic granuloma	Retinal capillary hemangioma	Vascular lesions • Capillary hemangioma • Lymphangioma • Orbital varix • Arteriovenous malformation • Malignant hemangioendothelioma • Organizing hematoma (hematic cyst, cholesterol granuloma) • Sturge-Weber syndrome • Klippel-Trenaunay-Weber syndrome Histiocytic, hematopoietic and lymphoproliferative masses • Langerhans cell histiocytosis • Juvenile xanthogranuloma • Sinus histiocytosis • Leukemia Granulocytic sarcoma • Lymphoma Mesodermal tumors • Fibroma • Myofibromatosis • Lipoma • Leiomyoma • Fibrous dysplasia • Juvenile ossifying fibroma • Giant cell (reparative) granuloma of bone • Aneurysmal bone cyst • Cartilaginous hamartoma • Sarcoma - Osteogenic sarcoma, Leiomyosarcoma, Fibrosarcoma, Malignant fibrous histiocytoma • Rhabdomyosarcoma Neurogenic tumors • Glioma • Meningioma • Neurofibroma • Schwannoma • Esthesioneuroblastoma • Paraganglioma • Melanotic neuroectodermal tumor of infancy Lacrimal gland • Pleomorphic adenoma (benign mixed tumor) • Adenocarcinoma (malignant mixed tumor) Metastatic • Neuroblastoma • Ewing Sarcoma • Wilms tumor
Molluscum contagiosum	Lipodermoid/dermolipoma	Optic nerve melanocytoma	
	Conjunctival nevus	Astrocytic hemartoma	
Cutaneous horn	Ocular melanosis	Congenital hypertrophy of the retinal pigment epithelium (CHRPE)	
		Combined hamartoma of the retinal pigment epithelium	
		Teratoma	

As the inflammation subsides, a distinct, firm, intra-lid nodule forms. Sty, on the other hand, occurs due to the blockage of eccrine and apocrine glands (Zeiss and Moll's glands), presenting as a pustule on the lid margin. Treatment for both conditions involves lid cleansing with baby shampoo, warm compresses, and topical antibiotics. Large and painful chalazia may require treatment through incision and curettage.

Benign epithelial and appendage tumors of the eyelid encompass syringoma, sudoriferous cyst, eccrine hidrocystoma, sebaceous cyst, milia, epithelial inclusion cyst, and pilomatrixoma. Epithelial inclusion cysts and eccrine gland cysts have clear contents, while sebaceous gland cysts appear white. If a tumor persists or size increases, surgical excision could be considered. Papilloma and molluscum contagiosum are viral-origin lid tumors. (Figure 1a,b) Papillomas usually present as pedunculated or sessile masses with a cauliflower appearance on the lid, while molluscum is characterized by umbilication. Both typically occur as multiple lesions, with most being self-limiting. However, surgical excision may be necessary for persistent or irritating lesions.

3.1. Ocular surface tumors

The conjunctiva is the most commonly involved area for ocular surface tumors. Tumors that affect the cornea usually involve the limbus.

3.2. Papilloma

Conjunctival papilloma comprises 7% to 10% of childhood conjunctival tumors. It is benign and linked to human papillomavirus types 6, 11, and 16.² This condition is caused by the same virus responsible for genital warts and may be transmitted during passage through the birth canal or via hand-eye contact. Conjunctival papilloma can manifest unilaterally or bilaterally, typically found in the inferior fornix or at the limbus. It presents as a pink, fibrovascular frond of tissue in a sessile or pedunculated configuration. Small lesions often resolve spontaneously and are observed. However, the preferred treatments are excision and double freeze-thaw cryotherapy, despite a high recurrence rate.³

3.3. Limbal dermoid

Limbal dermoid is a benign congenital choristoma located on the ocular surface, characterized by stratified squamous epithelium overlying dermal tissue.⁴ These dermoids are present from birth and typically remain stable in size. Clinically, they manifest as a distinct yellow-white solid mass involving the bulbar conjunctiva or the corneoscleral limbus, commonly situated in the inferotemporal quadrant. (Figure 2a) Occasionally, there is an association with Goldenhar's syndrome.⁵ Vision is generally unaffected unless severe astigmatism is induced.

While excision of limbal dermoids can be considered for cosmetic improvement, it does not eliminate the persisting astigmatism.

3.4. Dermolipoma/lipodermoid

Dermolipoma is commonly situated on the temporal aspect of the eye, appearing as a smooth, yellowish, fold-like mass that extends vertically in the lateral canthus. This benign congenital solid mass is composed of dense, collagenous tissue and adipose tissue lined by stratified squamous epithelium. Dermolipomas are typically unilateral, exhibit minimal growth, do not impact vision, and may be linked to Goldenhar's syndrome. (Figure 2b) While most cases necessitate only observation, only a few may require surgical excision.

3.5. Pyogenic granuloma

The term "pyogenic granuloma" is misleading as it does not exhibit pyogenic (pus-producing) qualities nor is it a true granuloma. Instead, it is a hypertrophic scar that develops on the conjunctiva following ocular trauma or surgery. Characterized by rapid growth, it is composed of fibroblasts and capillaries, presenting clinically as a red, fleshy, pedunculated mass. Treatment options include the use of topical steroids or excision of the lesion.

3.6. Conjunctival nevus

Conjunctival nevus is a frequently encountered childhood lesion characterized by pigmentation and a brownish discoloration, often accompanied by feeder vessels.⁶ Approximately 30% of these nevi are nonpigmented and exhibit cystic characteristics, moving freely with the conjunctiva. They are commonly found at the limbus, followed by the epibulbar area, the plica, the caruncle, and the eyelid margin. (Figure 3a) Malignant transformation is exceedingly rare in childhood cases, leading to a conservative management approach.⁷

3.7. Ocular melanosis

Ocular melanosis is characterized by slate-gray colored discrete patches beneath the conjunctiva, resulting from hyperpigmentation of the episclera. (Figure 3b) This congenital lesion does not exhibit free movement with the conjunctiva. In the case of Nevus of Ota, ocular melanosis is accompanied by hyperpigmentation of the eyelid. Although it is infrequently linked to glaucoma, regular ophthalmologic examinations are essential for monitoring and early detection.⁸

3.8. Intraocular tumors

Tumors within the eye can originate from various structures such as the iris, ciliary body, neural retina, optic disc,

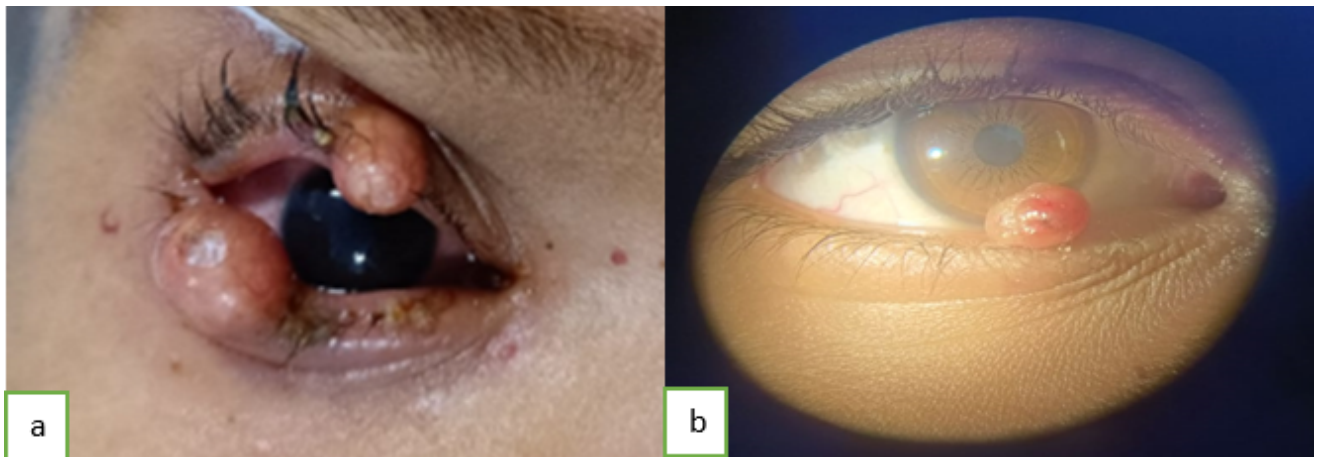


Figure 1: a: Showing multiple papillomata both upper and lower lid of right eye; **b:** An isolated sessile papilloma of right eye lower lid.

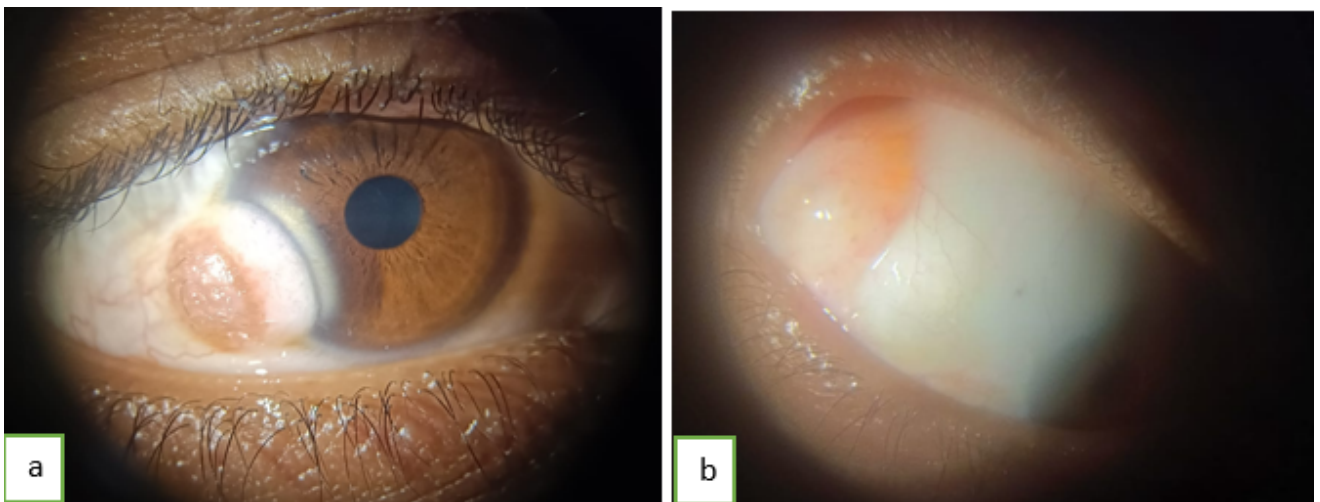


Figure 2: a: Showing limbal dermoid; **b:** Demonstrating dermo lipoma in the temporal aspect of the right eye

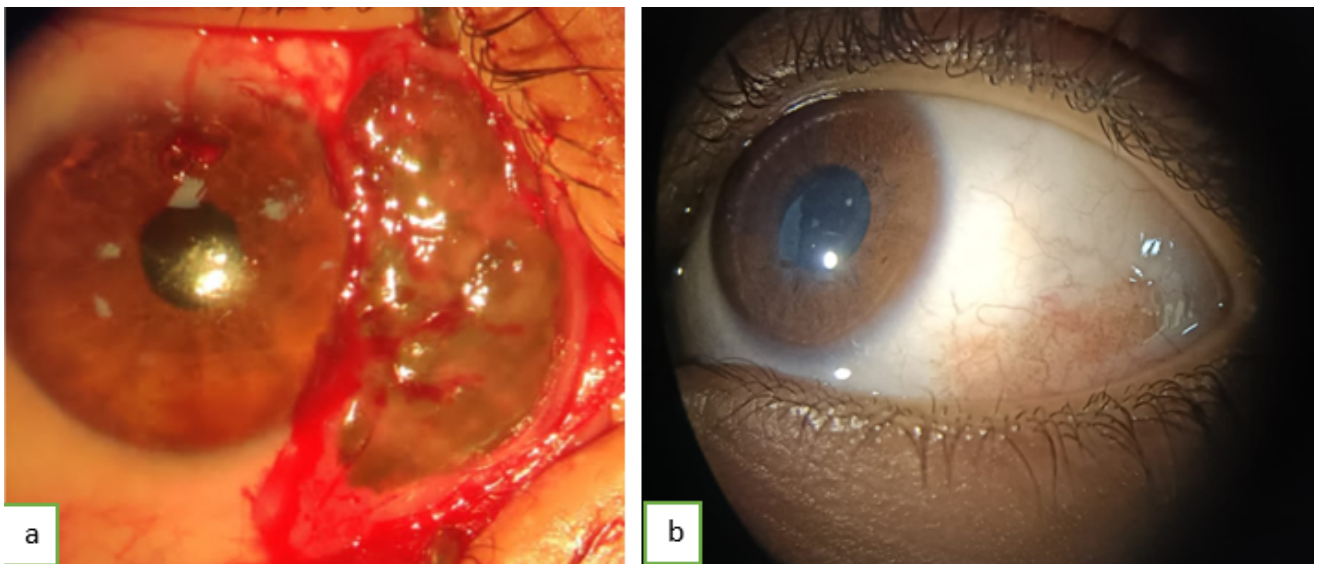


Figure 3: a: Showing naevus on medial side involving the plica and caruncle; **b:** Showing ocular melanosis of the left eye

retinal pigment epithelium, or choroid. The impact on vision depends on the location and growth rate of the lesion. In children, intraocular tumors often go unnoticed until they result in symptoms such as leukocoria, strabismus, bleeding, inflammation, or glaucoma. Prompt ophthalmological evaluation is crucial when these symptoms arise.

3.9. Retinoblastoma

The most common intraocular malignant tumor neoplasm in childhood is retinoblastoma (Rb), the incidence being 1 in 15,000 births.^{9,10} Mutation in the Rb gene (tumor suppressor gene) located at chromosome 13q14 results in its causation.¹¹ The development of retinoblastoma follows Knudson's two-hit hypothesis, where a single retinal cell undergoes a loss of function in both alleles of the Rb gene. In the nonheritable form, both alleles are lost somatically in a single retinal cell, while in the heritable form, the first allele is lost as a germline mutation, predisposing every cell in the patient's retina to lose the second allele. Familial retinoblastoma exhibits autosomal dominant transmission, with a positive family history encountered in 5% to 12% of cases.¹² Familial forms are typically bilateral and multifocal. Diagnosis is usually made at 1 year for bilateral and 2 years for unilateral retinoblastoma, with no gender or racial predilection.¹³ Genetic counselling is crucial for patients with known familial retinoblastoma. Leukocoria is the most common clinical presentation,¹⁴ and other signs include strabismus, glaucoma, apparent orbital cellulitis, spontaneous hyphema, and pseudohypopyon. Retinoblastoma appears creamy and may contain calcified areas. The tumor can grow exophytically underneath the retina, endophytically towards the vitreous, or seed the vitreous. Brain metastasis via direct extension through the optic nerve is the most common,¹⁵ while orbital invasion or hematogenous spread to bone is less frequent. Fortunately, metastatic disease is rare, and the 5-year survival rate after successful treatment exceeds 90%.¹⁶

Historically, enucleation was the primary treatment, but advancements in chemotherapy, laser treatment, focal radiation, and thermal therapies have significantly improved globe salvageability. Current chemotherapy regimens involve carboplatin, etoposide, and vincristine. Progression or regression of the disease requires frequent examinations under anesthesia, and lack of local recurrence or metastatic disease after 5 years is considered a cure.

Ten percent of children with familial retinoblastoma present in infancy with trilateral retinoblastoma, involving bilateral retinoblastoma with malignant pinealoblastoma due to the malignant transformation of retina-like cells in the pineal gland. These patients are at risk of developing second malignancies in the second decade of life, most commonly sarcomas of the head and neck.¹⁷ Therefore, lifelong screening is necessary, and any complaints of lumps or pain must be carefully considered.

3.10. Medulloepithelioma

Medulloepithelioma is an uncommon intraocular tumor that typically presents around the age of 5 years.¹⁸ Originating from the primitive medullary epithelium, it can exhibit either a benign or malignant nature depending on the presence of poorly differentiated cells. Malignant tumors tend to be locally invasive, but instances of metastatic disease are infrequent. In most cases, enucleation proves to be curative, as the tumor is typically confined within the globe.

3.11. Retinal capillary hemangioma

Retinal capillary hemangioma is a benign congenital lesion characterized by a small vascular mass that gradually enlarges due to the proliferation of capillary vessels and the occurrence of arteriovenous shunting. It presents with a red-to-orange appearance and features prominent afferent and efferent vessels. This condition is bilateral in 50% of cases and has a hereditary component in 20%.¹⁹ Retinal capillary hemangioma, when associated with a cerebellar hemangioblastoma, constitutes Von Hippel-Lindau disease. Visual loss is primarily caused by exudative retinal detachment, which can be managed with treatments such as laser therapy, cryotherapy, and scleral buckling.²⁰

3.12. Optic nerve melanocytoma

Optic nerve melanocytoma is a magnocellular nevus and appears as a densely pigmented mass over the optic nerve head. It is a benign lesion and more commonly affects darkly pigmented individuals.

3.13. Astrocytic hamartoma

Astrocytic hamartoma is a benign condition associated with tuberous sclerosis and NF-1.²¹ It is a glial tumor of the retina and optic nerve. It initially appears flat and then becomes dome-shaped with calcified nodules mimicking retinoblastoma.

3.14. Congenital hypertrophy of the retinal pigment epithelium (CHRPE)

CHRPE is a benign condition arising from the hypertrophy of retinal pigment epithelial cells. Although present at birth, it is typically diagnosed in adulthood. The lesion manifests as a hyperpigmented flat spot and can appear either as a solitary entity or in a clustered bear-track pattern. In cases where multiple and bilateral CHRPE is observed, it may be associated with Gardner's syndrome. This autosomal dominant disorder is characterized by adenomatous polyposis, with a heightened risk of progressing to adenocarcinoma of the colon.²²

4. Orbital Tumors

In the pediatric age group, most of the orbital space-occupying lesions are cystic, followed by vascular tumors and inflammatory diseases.

4.1. Cystic lesions

4.1.1. Developmental orbital cysts

Developmental orbital cysts encompass choristoma (histologically normal tissue situated in an abnormal location) and rare tumors such as teratoma, congenital cystic eye, and colobomatous cystic eye. Dermoid and epidermoid cysts, both choristomas, are positioned anterior to the orbital septum along the fronto-zygomatic suture. They originate from rest of epithelial cells entrapped in orbital bony sutures during embryonic development, constituting 30% to 46% of excised orbital tumors in children.²³ These cysts present as smooth, non-tender, firm, partially mobile masses beneath the skin. The chronic nature often results in reactive sclerosis in the surrounding bone. Distinguishing between dermoid and epidermoid cysts involves the presence of dermal components. If ruptured, the cyst's contents can incite severe inflammation, resembling orbital cellulitis. Small cysts are typically asymptomatic and observed, while larger ones are excised in their entirety.

Teratomas originate from two or more embryonic germ layers and are rarely malignant in the orbit compared to other body sites.

In congenital cystic eye, improper formation of the eye globe during embryogenesis leads to orbital cysts containing primitive ocular tissue.

Coloboma results from the failure of the eye's embryonic fissure to close during gestation.

4.2. Vascular lesions

In general, these lesions are the second most common orbital tumors²⁴ and include capillary hemangioma, lymphangioma, orbital varix, arteriovenous malformation, and malignant hemangioendothelioma.

4.2.1. Capillary hemangioma

They are the most common vascular orbital tumor in childhood,²⁵ are non-hereditary, unilateral, and more prevalent in girls than boys.²⁶ It typically becomes noticeable in the first few months of life, experiencing rapid growth in the subsequent six months before significantly diminishing in size at 2-3 years of age. If superficial or intradermal, it is referred to as a strawberry nevus due to its bright red, bumpy appearance; if subdermal, it appears as a bluish mass within the lid. Rarely, platelets may be sequestered, causing thrombocytopenia and hemorrhage (Kasabach-Merritt syndrome).²⁷ Vision may be compromised due to occlusion or anisometropic amblyopia,

and glasses or occlusion therapy may be initiated in moderate cases of amblyopia.²⁸ Close observation is usually sufficient for minimal lid involvement, as capillary hemangioma tends to resolve spontaneously. In advanced cases, administration of corticosteroids (topical, intralesional, or systemic) and systemic propranolol has been effective in reducing tumor size.²⁹ Superficial or intradermal capillary hemangiomas can be treated with carbon dioxide laser, and interferon-alfa is considered in large or refractory cases.³⁰

4.2.2. Lymphangioma

They typically appear in the first decade of life and account for 1% to 3% of all orbital tumors.³¹ A slowly progressive vascular malformation, it comprises lymphatic channels and does not regress like capillary hemangioma. The conjunctiva is frequently involved, presenting as a multilobulated mass. When the lid and orbit are affected, it manifests as a soft bluish mass usually in the superonasal quadrant.³² Bleeding frequently occurs, forming a chocolate cyst. Viral illness or spontaneous hemorrhage can cause sudden enlargement. Due to its infiltrative nature, complete surgical excision is challenging, and surgery is reserved for debulking large tumors.

4.2.3. Orbital varix

These can be congenital or acquired dilation of an ophthalmic vein and may cause intermittent proptosis of the globe. Proptosis is position-dependent and exacerbated by Valsalva's maneuver. Diagnostic CT of the orbit shows a dilated vein and the presence of phleboliths. Management is conservative, as surgical excision is associated with significant bleeding.

4.2.4. Arteriovenous malformations

They cause a high-flow state in the venous system, leading to dilatation and engorgement of veins, resulting in proptosis and increased episcleral venous pressure, causing glaucoma, disc edema, and dilated tortuous retinal veins. These malformations may be congenital (Wyburn-Mason syndrome) or acquired due to trauma or a ruptured aneurysm causing a carotid-cavernous fistula. Manifesting as slow proptosis of the globe, incomplete excision can lead to malignant transformation.

4.2.5. Sturge-Weber syndrome

This is a capillary malformation of the leptomeninges, sometimes involving the eyes or face.³³ Characteristic findings include a port-wine stain on the face following the trigeminal distribution, intraocular choroidal hemangioma, and seizures. (Figure 4) Ocular findings on the affected side include conjunctival injection, a tomato ketchup fundus due to increased choroidal vascularity, and refractory glaucoma.³⁴ Klippel-Trenaunay-Weber syndrome,

involving capillary, lymphatic, and venous channels, is a variant of Sturge-Weber syndrome.

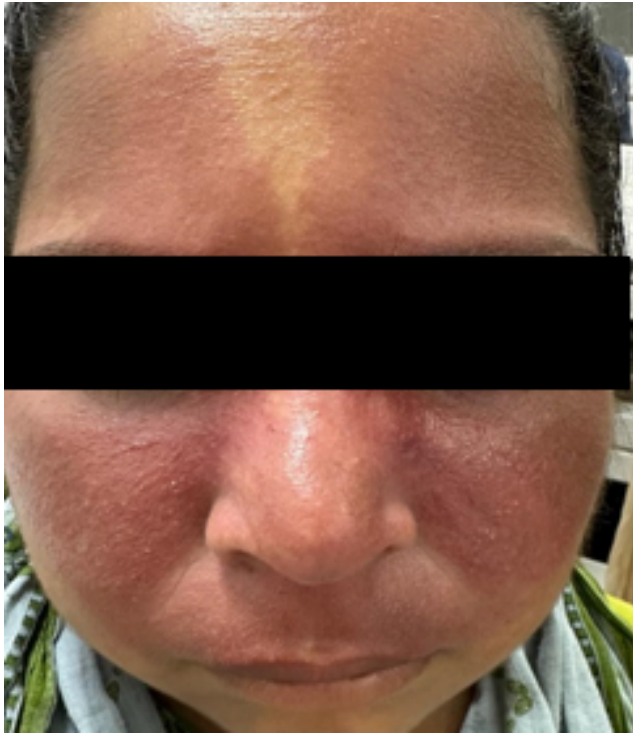

Figure 4: Shows sturge weber syndrome with typical port wine stain

4.3. Inflammatory masses

Orbital pseudotumor typically presents bilaterally in children, causing ocular pain, particularly with eye movement, along with tenderness and inflammatory signs. Diplopia and strabismus may occur due to extraocular muscle restriction or globe displacement. Slit lamp examination may reveal iritis.

A spectrum of disorders characterized by infiltration of organs by Langerhans' cell histiocytes and associated immunoreactive cells includes histiocytic, hematopoietic, and lymphoproliferative masses like Langerhans' cell histiocytosis, eosinophilic granuloma, Hand-Schuller-Christian disease, and Letterer-Siwe syndrome.³⁵ This infiltration may be unifocal, limited to bone or soft tissue, multifocal involving bone, or multifocal affecting bone and various other organ sites. Unifocal lesions in the orbit are common, representing 1% to 3% of pediatric orbital tumors.³⁶ CT scans vividly describe lesions originating within the orbital bone and causing intraosseous lytic changes. If the periosteum is penetrated, an intense inflammatory reaction ensues. Patients typically present with a painful, swollen lid mass, often with erythema, usually located superotemporally. Diagnosis is confirmed through surgical biopsy, and treatment options range

from observation to surgical excision, corticosteroids, chemotherapy, and radiation.³⁷

Juvenile xanthogranuloma (non-Langerhans' cell histiocytosis) is a histiocytic disorder with cutaneous and ocular manifestations. Distinguished from Langerhans' histiocytosis by the absence of cytoplasmic organelles (Langerhans' granules) in histiocytes and the absence of systemic disease, it primarily involves the iris. However, lesions in the eyelid, orbit, and cornea have also been reported.³⁸ Typically occurring before the age of 2, it may manifest with proptosis and involvement of extraocular muscles. Iris lesions are vascular nodules that can bleed easily, causing spontaneous hyphema and glaucoma. Treatment options include observation, corticosteroids, or radiation.

While proptosis is uncommon with leukemia, subclinical infiltration of the orbit by leukemic cells likely occurs frequently. The globe is often affected due to infiltration of leukemic cells or hematologic disturbances such as thrombocytopenia and hyperviscosity. Common retinal findings include pseudo-Roth spots, cotton-wool spots, and disc edema due to optic nerve invasion by leukemic cells. Orbital lymphoma is rare in childhood, except for the variant known as Burkitt's lymphoma, caused by the Epstein-Barr virus. Endemic in the black race, it typically presents six months after viral infection and can affect the abdomen, lymph nodes, cranium, and orbit.

4.4. Mesodermal tumors

Mesodermal tumors of the orbit originate from mesenchymal components such as extraocular muscles, fibroblasts, cartilage, fat cells, and smooth muscles. Examples of these tumors include rhabdomyosarcomas, fibromas, lipomas, leiomyomas, and sarcomas.

Rhabdomyosarcoma stands out as the most common primary malignancy of the orbit in children.³⁶ This nonfamilial condition predominantly affects boys and is typically diagnosed around the age of seven.³⁹ Often located in the superonasal quadrant of the orbit, it presents with proptosis and eyelid drooping due to a lid mass. Interestingly, a history of minor trauma to the head or orbit is an unrelated finding. Unlike its name suggests, orbital rhabdomyosarcoma arises not from the extraocular muscles but rather from undifferentiated mesenchymal cells in the orbit. The tumor can metastasize via hematogenous spread to the lungs and bones. Management involves orbital biopsy for confirmation of the diagnosis, followed by a combination of chemotherapy and irradiation. A 91% 3-year survival rate has been documented post-treatment.⁴⁰

4.5. Neurogenic tumors

Neurogenic tumors originate from the optic nerve and peripheral nerves within the orbit. These tumors encompass

benign lesions like optic nerve gliomas, meningiomas, neurofibromas, and schwannomas.

Optic pathway glioma, also known as juvenile pilocytic astrocytoma, is a slow-growing benign tumor affecting the sensory visual pathways. Accounting for 2% to 3% of orbital tumors, it is more prevalent in boys and typically begins between 2 and 6 years of age, with 90% becoming evident by the second decade.⁴¹ Optic glioma may exhibit rapid progression of signs and symptoms over a few months, especially in some infants. Its association with NF-1 is common.⁴² While gliomas may also be found in the optic chiasma and optic tract, they most commonly originate from the orbit. Tumors in the orbit present with slowly progressive proptosis, and other signs include vision loss, strabismus, nystagmus, disc edema, or optic atrophy. The management of optic pathway glioma is often conservative, with surgical removal considered when vision declines, the tumor extends toward the chiasm, or advanced proptosis occurs. Rapidly growing gliomas may require chemotherapy and radiation.

Neurofibromas are tumors affecting peripheral nerves and contain axons, Schwann's cells, and fibroblasts. The most common type in the pediatric population is plexiform neurofibroma, which is pathognomonic for NF-1. This non-encapsulated tumor may involve the extraocular muscles, lacrimal gland, and eyelid. The affected eyelid may have an S-shaped curve with a texture likened to a bag of worms, often accompanied by ptosis. Treatment typically involves surgical excision of the neurofibroma.

Inflammatory lesions, commonly observed as features of orbital pseudotumor, most frequently affect the lacrimal gland. Neoplastic lesions such as adenoma and adenocarcinoma are rare in the pediatric population.

4.6. Metastatic tumors

In children, ocular metastases predominantly impact the orbit, unlike adults where the uvea is the primary site of involvement. The primary malignancies leading to these metastases include neuroblastoma, the most common metastatic orbital tumor in the pediatric population.⁴³ Less commonly, Ewing's sarcoma and Wilms' tumor may also contribute. Typically affecting children at around 2 years of age, orbital spread is observed in 15% of cases.⁴⁴ The abdomen is the most common primary site from which orbital metastases occur via the hematogenous route. The hallmark sign is proptosis, which may be accompanied by lid ecchymosis caused by ischemia. Horner's syndrome can occur due to the interruption of sympathetic pathways in the chest. Opsoclonus myoclonus, characterized by "dancing eyes and dancing feet," is a unique paraneoplastic syndrome resulting from a remote disease affecting the cerebellum.⁴⁵

5. Conclusion

Pediatricians play a vital role in the diagnosis of pediatric ocular tumors. They are the first to recognize ocular

problems that may not be apparent to parents. It is therefore important to recognize the signs and symptoms of ocular tumors of childhood so that prompt ophthalmologic evaluation and treatment may be undertaken. Most of the pediatric ocular tumors are congenital with early presentations. Most pediatric orbital tumors are benign, and developmental cysts comprise half of orbital cases, with rhabdomyosarcoma being the most common and capillary hemangioma being the second most common orbital tumor. The most common intraocular malignant lesion is retinoblastoma. The orbit is the most common location for metastases in children. Malignant tumors may be life-threatening, but both malignant and benign tumors may be vision-threatening.

6. Conflicts of Interest

None declared.

7. Source of Funding

None.

8. Acknowledgments

We acknowledge our patients for their cooperation.

References

1. Al-Mujaini A, Maurya RP, Bosak S, Karan MK, Roy M, Singh VP, et al. Clinicopathological Analysis and Demographic Features of Ocular Malignancies. *Clin Ophthalmol*. 2015;15:357–65. doi:10.2147/OPHT.S287087.
2. Sjo NC, Heegaard S, Prause JU. Human papillomavirus in conjunctival papilloma. *Br J Ophthalmol*. 2001;85(7):785–7.
3. Shields CL, Shields JA. Tumors of the conjunctiva and cornea. *Indian J Ophthalmol*. 2019;67(12):1930–48.
4. Scott JA, Tan DT. Therapeutic lamellar keratoplasty for limbal dermoids. *Ophthalmology*. 2001;108(10):1858–67.
5. Gorlin R, Jue K, Jacobse U, Goldschmidt E. Oculoauricovertebral dysplasia. *J Pediatr*. 1963;63(5):991–9.
6. Gerner N, Norregaard JC, Jensen O, Prause JU. Conjunctival naevi in Denmark 1960-1980 A 21-year follow-up study. *Acta Ophthalmol Scand*. 1996;74(4):334–7.
7. Shields CL, Fasiuddin A, Mashayekhi A, Shields JA. Conjunctival nevi: clinical features and natural course in 410 consecutive patients. *Arch Ophthalmol*. 2003;122(2):167–75.
8. Blodi F. Ocular melanocytosis and melanoma. *Am J Ophthalmol*. 1975;80(3 Pt 1):389–95.
9. Abramson DH, Scheffer AC. Update on retinoblastoma. *Retina*. 2004;24(6):828–48.
10. Maurya R, Gupta A, Singh V, Gupta V, Singh V. Presentation pattern of Retinoblastoma in North India: A Teaching Hospital Survey. *J Sci Res*. 2022;66(1):186–92.
11. Sellers W, Kaelin W. Role of the retinoblastoma protein in the pathogenesis of human cancer. *J Clin Oncol*. 1997;15(11):3301–12.
12. Atchaneeyasakul L, Murphree AL. Retinoblastoma. In: Schachat A, Ryan S, Murphy R, editors. *Retina*, 3rd edn. vol. volume -1. Missouri: Mosby; 2001. p. 513–70.
13. Tamboli A, Podgor M, Horm J. The incidence of retinoblastoma in the United States: 1974 through 1985. *Arch Ophthalmol*. 1990;108(1):128–32.

14. Shields IA, Shields CL, Parsons HM. Differential diagnosis of retinoblastoma. *Retina*. 1991;11(2):232–43.
15. Dunkel II, Khakoo Y, Kernan NA. Intensive multimodality therapy for patients with stage 4a metastatic retinoblastoma. *Pediatr Blood Cancer*. 2010;55(1):55–9.
16. Shields C, Shields J. Recent developments in the management of retinoblastoma. *J Pediatr Ophthalmol Strabismus*. 1999;36(1):8–18.
17. Abramson D, Frank C. Second nonocular tumors in survivors of bilateral retinoblastoma: a possible age effect on radiation-related risk. *Ophthalmology*. 1998;105(4):573–9.
18. Broughton W, Zimmerman L. A clinicopathologic study of 56 cases of intraocular medulloepitheliomas. *Am J Ophthalmol*. 1978;85(3):407–18.
19. Green R, Retina. *Ophthalmic pathology: an atlas and textbook*. WB Saunders; 1996. p. 709–718.
20. Nicholson D. Retina. In: Ryan S, editor. *Capillary hemangioma of the retina and von Hippel-Lindau disease*. St. Louis: Mosby; 1994. p. 633–40.
21. Mishra C, Kannan NB, Ramasamy K, Balasubramanian DA. Retinal Astrocytic Hamartoma in Tuberous Sclerosis. *Indian Dermatol Online J*. 2019;10(6):753–54.
22. Mirchils G, Tejpar S, Thoelen R. Large deletions of the APC gene in 15 percent of mutation-negative patients with classical polyposis (FAP): a Belgian study. *Hum Mutat*. 2005;25(2):125–34.
23. Pahwa S, Sharma S, Das CJ, Dharmija E, Agrawal S. Intraorbital Cystic Lesions: An Imaging Spectrum. *Curr Probl Diagn Radiol*. 2015;44(5):437–48.
24. Bullock J. Orbital tumors in childhood. *Ophthalmol*. 1986;93:379–84.
25. Cornish KS, Reddy AR. The use of propranolol in the management of periocular capillary haemangioma—a systematic review. *Eye (Lond)*. 2011;25(10):1277–83.
26. Haik BG, Karcioğlu ZA, Gordon RA, Pechous BP. Capillary hemangioma (infantile periocular hemangioma). *Surv Ophthalmol*. 1994;38(5):399–26.
27. Osman NM. Kasabach - Merritt syndrome: A case report. *Sudan J Paediatr*. 2013;13(1):9–52.
28. Motwani M, Simon JW, Pickering JD, Catalano RA, Jenkins PL. Steroid injection versus conservative treatment of anisometropia amblyopia in juvenile adnexa hemangioma. *J Pediatr Ophthalmol Strabismus*. 1995;32(1):26–8.
29. Aletaha M, Salour H, Bagheri A, Raffati N, Amouhashemi N. Oral propranolol for treatment of pediatric capillary hemangiomas. *J Ophthalmic Vis Res*. 2012;7(2):130–3.
30. Haywood R, Monk B, Mahaffey P. The treatment of early cutaneous capillary hemangiomas (strawberry naevi) with tunable dye laser. *Br J Plast Surg*. 2000;53:302–307.
31. Nassiri N, Rootman J, Rootman DB, Goldberg RA. Orbital lymphaticovenous malformations: current and future treatments. *Surv Ophthalmol*. 2015;60(5):383–405.
32. Volpe N, Jakobiec F. Pediatric orbital tumors. *Int Ophthalmol Clin*. 1992;32(1):201–21.
33. Cohen M. Klippel-Trenaunay syndrome. *Am J Med Gen*. 2000;93(3):171–5.
34. Vivian A, Taylor D. The phakomatoses. In: Tasman W, editor. *Duane's clinical ophthalmology*. Philadelphia: Lippincott; 2001. p. 1–15.
35. Jakobiec F, Bilyk J, Font R. Orbit. In: Spencer W, editor. *Ophthalmic pathology: an atlas and textbook*. 4th edn. Philadelphia: WB Saunders; 1996. p. 2538–45.
36. Rootman J. Diseases of the orbit: a multi-disciplinary approach. Philadelphia: Lippincott; 1988.
37. Kramer T, Noecker R, Miller J. Langerhans cell histiocytosis with orbital involvement. *Am J Ophthalmol*. 1997;124(6):814–24.
38. Patel KH, El-Yassir M, Erzurum SA. Juvenile xanthogranuloma—a rare cause of unilateral orbital swelling in an elderly patient. *Orbit*. 2015;34(2):106–8.
39. Dai XZ, Wang LY, Shan Y, Qian J, Xue K, Ye J, et al. Clinicopathological analysis of 719 pediatric and adolescents' ocular tumors and tumor-like lesions: A retrospective study from (2000) (2018) in China. *Int J Ophthalmol*. 2020;13(12):1961–7.
40. Zloto O, Minard-Colin V, Boutroux H, Brisse HJ, Levy C, Kolb F, et al. Second-line therapy in young patients with relapsed or refractory orbital rhabdomyosarcoma. *Acta Ophthalmol*. 2021;99(3):334–41.
41. Dolecek TA, Propp JM, Stroup NE, Kruchko C. CBTRUS statistical report: primary brain and central nervous system tumors diagnosed in the United States in. *Neuro Oncol*. 2005;14(Suppl 5):1–49.
42. Beres SJ, Avery RA. Optic Pathway Gliomas Secondary to Neurofibromatosis Type 1. *Semin Pediatr Neurol*. 2017;24(2):92–9.
43. Watkins LM, Rubin PA. Metastatic tumors of the eye and orbit. *Int Ophthalmol Clin*. 1998;38:117–128.
44. Musarella M, Chan H, Deboer G. Ocular involvement in neuroblastoma: prognostic implications. *Ophthalmology*. 1984;91(8):936–40.
45. Castillo BV, Kaufman L. Pediatric tumors of the eye and orbit. *Pediatr Clin North Am*. 2003;50(1):149–72.

Author biography

Pratibha Sahu, Junior Resident

Anuradha Raj, Additional Professor and Head

Cite this article: Sahu P, Raj A. Pediatric ocular tumors: An overview. *IP Int J Ocul Oncol Oculoplasty* 2023;9(4):157-165.