

Content available at: <https://www.ipinnovative.com/open-access-journals>

IP International Journal of Ocular Oncology and Oculoplasty

Journal homepage: <https://ijooo.org/>**Case Report****Double whammy – High voltage optic neuropathy and compressive optic neuropathy****Malarvizhi Raman<sup>1</sup>, Sheela Rajan<sup>2</sup>, Keerthana Athiaman<sup>1,\*</sup>, Prashanth Ravi<sup>2</sup>**<sup>1</sup>Sri Muthukumaran Medical College Hospital and Research Institute, Chennai, Tamil Nadu, India<sup>2</sup>Regional Institute of Ophthalmology and Government Ophthalmic Hospital, Chennai, Tamil Nadu, India**ARTICLE INFO***Article history:*

Received 25-06-2023

Accepted 20-07-2023

Available online 06-11-2023

*Keywords:*

Electric shock

Optic neuropathy

Pituitary adenoma

**ABSTRACT**

Electric current flows in the body between two contact points. The degree of damage caused by the current is dependent on voltage intensity, tissue resistance, type of current, duration and area of contact and the route the current traveled within the body. Ophthalmic injuries are common with electrical damage to the body. Blepharospasm, keratopathy, uveitis, corneal opacities, cataracts, vitreous hemorrhage, retinal edema, macular hole and vascular occlusions are the frequently encountered ones. Here in this case, we report a very rare coincidence of optic neuropathy triggered by high voltage electrical injury (electrocution) and an occult pituitary macroadenoma which coexisted in the same individual causing compressive optic neuropathy. The patient was treated initially as optic neuropathy with steroids and later the macroadenoma was excised under neuro-surgical guidance. This case necessitates the importance of investigating temporal pallor in young individuals and arrival at a proper diagnosis which otherwise could be vision as well as life threatening.

This is an Open Access (OA) journal, and articles are distributed under the terms of the [Creative Commons Attribution-NonCommercial-ShareAlike 4.0 License](https://creativecommons.org/licenses/by-nc-sa/4.0/), which allows others to remix, tweak, and build upon the work non-commercially, as long as appropriate credit is given and the new creations are licensed under the identical terms.

For reprints contact: [reprint@ipinnovative.com](mailto:reprint@ipinnovative.com)**1. Introduction**

Electrical injuries to the human body range from damage to various organs to even death. Electrocution is common in developing countries like India, where overhead high tension lines hang precariously.<sup>1</sup> Ocular complications due to high-voltage electrical current were first described as cataracts that occurred due to lightning strike in 1722. High-voltage electric burns can cause various ocular injuries and may manifest in the form of conjunctival hyperemia, corneal opacities, uveitis, miosis, spasm of accommodation, cataract, retinal edema, papilledema, choroidal rupture, chorioretinal necrosis/atrophy, retinal detachment, and optic atrophy.<sup>2</sup> The severity of the injury is closely related to the voltage power, electrical current intensity, polarization and contact duration.<sup>3</sup> The proposed mechanisms of insult

include thermal damage and vascular insult to the ocular structures. Ischemia resulting from coagulation and necrosis of the vasculature are the proposed pathogenesis of retinal complications after electric shock injury.<sup>4</sup>

**2. Case Report**

A 37 year old male presented with a history of accidental electrocution [AC CURRENT] and sudden onset visual loss in left eye for one day. The patient was kept under observation at the emergency department and referred for ophthalmological evaluation. The patient was not a smoker or alcoholic. There was no history of chronic drug intake or substance abuse. The cardiovascular, respiratory and nervous system examination did not reveal any significant abnormalities.

A provisional diagnosis of electric shock induced optic neuropathy in the left eye was made and the patient was

\* Corresponding author.

E-mail address: [keerthanaathiaman@gmail.com](mailto:keerthanaathiaman@gmail.com) (K. Athiaman).

**Table 1:** Ophthalmic findings at presentation

RE		LE
6\6	Best corrected vision	PL+
12 mmHg	Intraocular pressure by GAT	14 mmHg
WNL	Slit lamp biomicroscopy	WNL
Reacting to light	PUPIL	Grade 3 relative afferent pupillary defect
Normal	Color vision	Not possible
Not able to perceive on the temporal side	Fields by confrontation	Not possible
Media clear CDR 0.3	Fundus	Media clear CDR 0.3
Temporal pallor +		Temporal pallor +
Vessels normal		Vessels normal
Macula foveal reflex+		Macula foveal reflex+

started on Inj. methylprednisolone 500 mg IV BD for 3 days, Inj. Vitamin B12 IM on alternate days, Inj ranitidine 50 mg IV BD. The patient was planned for an MRI brain and Optical coherence tomography Retinal nerve fiber layer. After 3 days the patient was discharged and was advised to take oral prednisolone 1mg/kg per day for 11 days and asked to review on an outpatient basis on alternate days. On discharge the patient had the following findings.

**Table 2:** Ophthalmic findings at discharge

RE		LE
6\6	Vision	PL+
RTL	Pupil	G3 RAPD

One week later the patient presented with sudden onset vision loss in the right eye. At presentation,

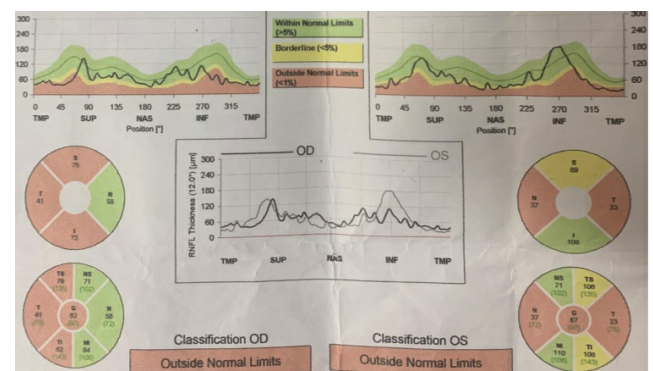
**Table 3:** Ophthalmic findings a week after discharge

RE		LE
PL+	Vision	6\60
Ill sustained	Pupil	Ill sustained
Full	EOM	Full
Not possible	Color vision	9/14
	Ishihara	
Poor vision	Fields by Bjerrum	Temporal hemianopia

The patient's vision had improved in the left eye, but had unfortunately deteriorated in the other eye. Field by Automated Perimetry (AP) was done but was unreliable. In fields by Bjerrum, the patient had a hemianopic defect in the left eye. Considering the previous fundus exam findings of bilateral temporal

pallor and temporal field defect, the patient was urgently advised an MRI brain and neurosurgery opinion. MRI brain revealed a large well defined T2 isointense to hyperintense lesion noted in the pituitary region causing expansion of the sella and extending to the suprasellar region measuring 2.9cm (anteroposterior) and 2.5 cm (transverse) causing compression of the optic chiasma and posteriorly extending to the sphenoid sinus suggestive of a pituitary macroadenoma. Blood investigations were within normal limits. Hormonal panel [triiodothyronine (T3), thyroxine (T4), thyroid stimulating hormone(TSH), follicular stimulating hormone(FSH),luteinizing hormone (LH), prolactin, human growth hormone(HGH), cortisol, adrenocorticotrophic hormone(ACTH)] was also within normal limits, not suggestive of apoplexy.

A diagnosis of non-functioning pituitary macroadenoma with possible right cavernous sinus extension and suprasellar extension impinging on the optic chiasm was made. There were no signs of raised intracranial tension. The patient was planned for transnasal, trans-sphenoidal endoscopic excision of the tumor with lumbar drain. The patient was also explained about the risk of poor visual outcome post procedure. The intra-op and post-op period were uneventful. The patient was on Inj Cefotaxime 1g IV TDS, Inj Metronidazole 500 mg TDS Inj Dexamethasone 8 mg IV BD. Patient was stable in the post-op period, however the vision in the right eye was still PL+ and 6/60 in the left eye. At present the patient is under regular follow up at ophthalmology and neurosurgery departments.

**Fig. 1:** OCT RNFL of patient showing temporal pallor in both eyes.

### 3. Discussion

Posterior segment injuries following high voltage electrical shock include vitreous hemorrhage, retinal edema, retinal hemorrhage, retinal detachment, cystoid macular edema, chorioretinal rupture, lightning maculopathy, macular hole, central retinal vein occlusion, and central retinal artery occlusion. Neurological injuries include thermal papillitis, optic neuropathy, loss of pupillary reflex, anisocoria,

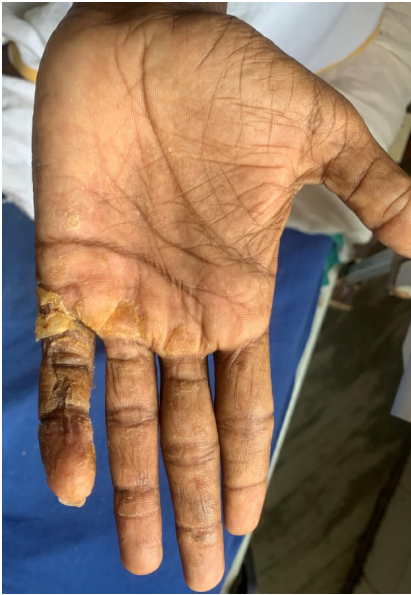

Fig. 2: Entry wound site.

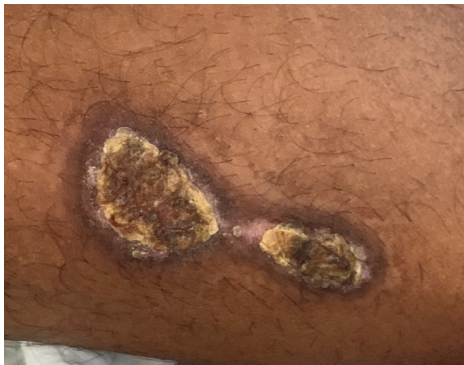

Fig. 3: Exit wound site.

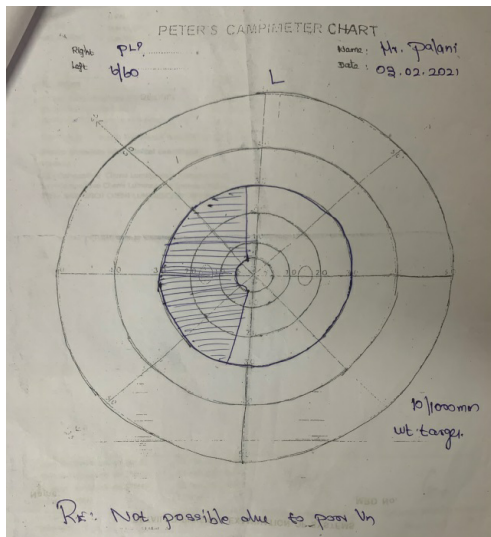


Fig. 4: Field- left eye showing a hemianopic defect.

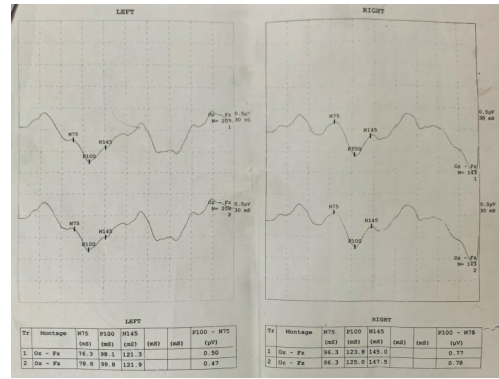


Fig. 5: Visually evoked potential showing prolonged p100 latency in right eye.

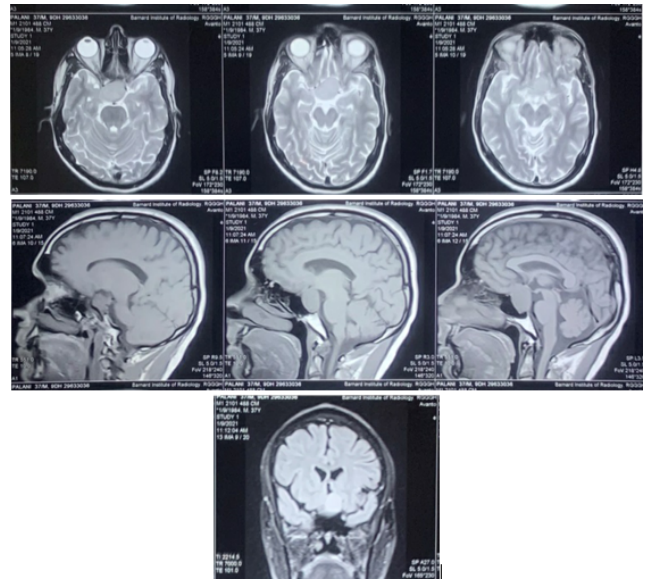


Fig. 6: MRI brain showing a large well defined T2 isointense to hyperintense lesion noted in the pituitary region causing expansion of the sella and extending to the suprasellar region measuring 2.9 cm (anteroposterior) and 2.5 cm (transverse) causing compression of the optic chiasma and posteriorly extending to the sphenoid sinus suggestive of a pituitary macroadenoma

Horner's syndrome, multiple cranial nerve palsies, and nystagmus.<sup>5,6</sup> The retina and optic nerve are less susceptible to direct electrical injury as they have lower electrical resistance but are more prone to indirect injury secondary to vascular injury.<sup>7</sup> Prolonged depolarization and primary (direct trauma) and secondary tissue damage (oedema, ischemia and reperfusion injury) have been proposed as mechanisms for the neuronal damage.<sup>8</sup> Whether the electric shock triggered the vision loss or was it the macroadenoma is unclear. Electrocutation triggering the vision loss cannot be ruled out due to the consecutive involvement of both eyes within a short span after electrocution and the pituitary adenoma could have been an incidental finding.<sup>9</sup>

#### 4. Conclusion

Electrical injuries are very common in developing nations. They can cause life threatening complications as well as vision impairment. This case shows the importance of careful evaluation and investigation of temporal pallor of unknown etiology in young individuals which otherwise could be life threatening .

#### 5. Source of Funding

None.

#### 6. Conflict of Interest

There is no conflict of interest


#### References

1. Yadav A, Katiyar V, Phadikar P, Gupta SK. A case of isolated bilateral cataract following high-voltage electrical injury. *Oman J Ophthalmol.* 2020;13(1):34–6. doi:10.4103/ojo.OJO\_129\_2016.
2. Archer DM. Injuries of posterior segment of eye. *Trans Ophthalmol Soc UK.* 1985;104(Pt 6):597–615.
3. Loftus JJ. Electrical injuries. *J Ir Med Assoc.* 1957;41(243):94–6.
4. Alamri O, Alturkistani D, Saifaldeen A, Talatt K. Bilateral Impending Macular Hole, Cataract and Uveitis following Electrical Injury. *Case Rep Ophthalmol.* 2020;11(3):647–51.
5. Norman ME, Albertson D, Younge BR. Ophthalmic manifestations of lightning strike. *Surv Ophthalmol.* 2001;46(1):19–24. doi:10.1016/s0039-6257(01)00232-6.
6. Lee MS, Gunton KB, Fischer DH, Brucker AJ. Ocular manifestations of remote lightning strike. *Retina.* 2002;22(6):808–10. doi:10.1097/00006982-200212000-00023.
7. Grover S, Goodwin J. Lightning and electric injury: neuro-ophthalmologic aspects. *Semin Neurol.* 1995;15(4):335–41.
8. Norman ME, Albertson D, Younge BR. Ophthalmic manifestations of lightning strike. *Surv Ophthalmol.* 2001;46(1):19–24.
9. Sharma A, Reddy Y, Shetty AP, Kader SMA. Electric shock induced Purtscher-like retinopathy. *Indian J Ophthalmol.* 2019;67(9):1497–500.

#### Author biography

**Malarvizhi Raman**, Professor and HOD

**Sheela Rajan**, Assistant Professor

**Keerthana Athiaman**, Post Graduate  <https://orcid.org/0000-0003-3757-1942>

**Prashanth Ravi**, Post Graduate

**Cite this article:** Raman M, Rajan S, Athiaman K, Ravi P. Double whammy – High voltage optic neuropathy and compressive optic neuropathy. *IP Int J Ocul Oncol Oculoplasty* 2023;9(3):146-149.