

Content available at: <https://www.ipinnovative.com/open-access-journals>

IP International Journal of Ocular Oncology and Oculoplasty

Journal homepage: <https://ijooo.org/>

## Case Report

# Screening saves sight: An unusual case of type-1 neurofibromatosis

Kale Satya Geethika<sup>1</sup>, Hannah Ranjee Prasanth<sup>1</sup>, Karthik Kumar Arumugam<sup>1</sup>,  
Karthiga I<sup>1,\*</sup>, Rohitha Kuppusamy<sup>1</sup>

<sup>1</sup>Dept. of Ophthalmology, Pondicherry Institute of Medical Sciences, Puducherry, India



### ARTICLE INFO

#### Article history:

Received 10-08-2023

Accepted 18-09-2023

Available online 06-11-2023

#### Keywords:

Neurofibromatosis

Retinal detachment

### ABSTRACT

Neurofibromatosis (NF), described by von Recklinghausen in 1882, consists of at least two distinct disorders: NF1 (von Recklinghausen's or peripheral neurofibromatosis) and NF2, formerly known as 'central neurofibromatosis.' The prevalence of NF is approximately 1 in 4,000, and of NF2, 1 in 50,000. Neurofibromatosis type 1 is a multisystemic neurocutaneous disorder with an autosomal dominant hereditary pattern. Ocular manifestations include plexiform neurofibroma of eyelid, Lisch nodules in iris, optic nerve glioma, glaucoma, sphenoid wing dysplasia. Retinal and choroidal involvement are encountered less frequently. Unusual ocular findings include multiple choroidal nevi, combined hamartoma, choroidal Schwannoma, choroidal melanoma and vaso proliferative retinal tumors.

Here we report a case of an 18 year old girl diagnosed with neurofibromatosis type 1 who on routine ocular examination was found to have high myopia in both eyes and on fundus examination had a macula 'on' inferior retinal detachment with retinal hole in right eye. Inferior retinal detachment is rarely reported in neurofibromatosis type 1. This case emphasizes the importance of conducting ocular examination even in asymptomatic patients with neurofibromatosis, so that early detection and treatment can prevent vision loss secondary to retinal detachment.

This is an Open Access (OA) journal, and articles are distributed under the terms of the [Creative Commons Attribution-NonCommercial-ShareAlike 4.0 License](https://creativecommons.org/licenses/by-nc-sa/4.0/), which allows others to remix, tweak, and build upon the work non-commercially, as long as appropriate credit is given and the new creations are licensed under the identical terms.

For reprints contact: [reprint@ipinnovative.com](mailto:reprint@ipinnovative.com)

## 1. Introduction

Neurofibromatosis, an oculo- neurocutaneous syndrome is characterized by multi system involvement. Neurofibromatosis type 1(NF 1) affects about 1 in 4000 individuals with autosomal dominant mode of inheritance.<sup>1-4</sup> Ocular manifestations of NF1 include Lisch nodules on the iris, optic nerve gliomas, myopia, eyelid or orbit plexiform neurofibroma, glaucoma, choroidal granuloma and rarely, retinal hamartomas. Here we report a case of neurofibromatosis who had developed an asymptomatic inferior retinal detachment which is a rare ocular presentation.

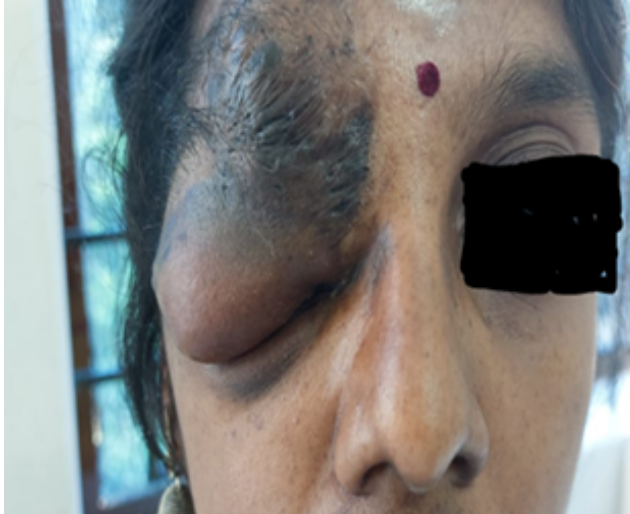## 2. Case Report

We describe the case of a 18-year-old girl diagnosed with neurofibromatosis type 1 who was referred to the Ophthalmology Out patient department for routine ocular examination. It was noted that she had a large plexiform neurofibromatosis of right upper lid for which she had undergone reduction surgeries thrice in Plastic Surgery. The last surgery was done three years prior. She gave history of frequently changing her glasses. There was no history of ocular trauma. The patient had no ocular symptoms, and her best corrected visual acuity (BCVA) was 6/18 in right eye and 6/12 in left eye. The autorefractor (AR) reading under cycloplegia was -7.50 DS in the right eye and -7.00DS/-2.00DC in the left eye. Slit-lamp examination revealed multiple characteristic Lisch nodules on the iris

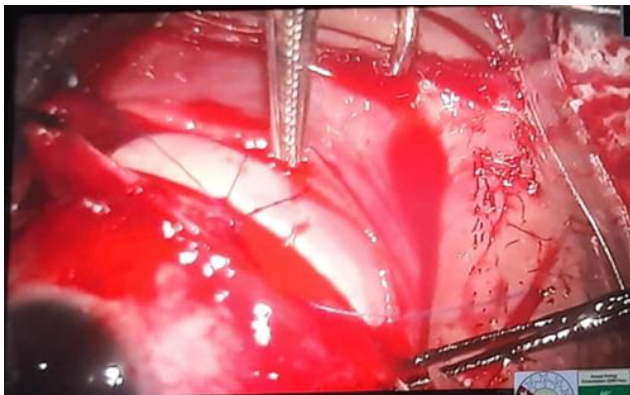
\* Corresponding author.

E-mail address: [geethikakale94@gmail.com](mailto:geethikakale94@gmail.com) (Karthiga I).

of both eyes. Dilated fundus examination showed inferior retinal detachment, not involving the fovea, with 2-3 retinal holes seen, left eye had white without pressure. The patient underwent RE scleral buckling, with 276 buckle with peripheral cryotherapy. Scleral buckling is preferred in these young patients as it reduces the risk of complications of PPV like cataract formation.



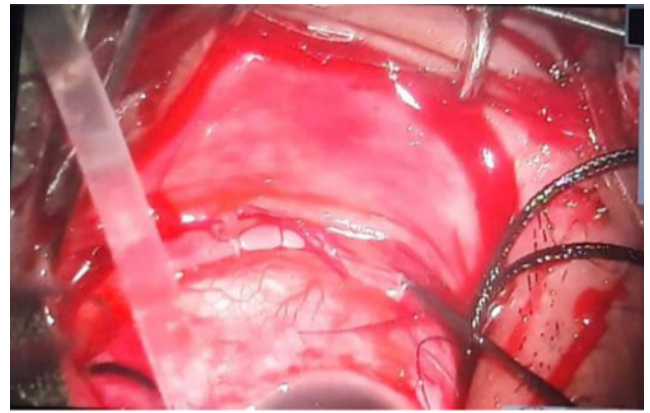
**Fig. 1:**



**Fig. 2:**

### 3. Discussion

Neurofibromatosis type 1, also known as Von Recklinghausen's disease, can present a great variety of ophthalmic manifestations although retinal and choroid lesions are less frequent. Unusual ocular findings include multiple choroid nevi, combined hamartoma, etc. Rarely, retinal astrocytic hamartomas may extend to the peripheral retina and cause devastating complications such as neovascular glaucoma and retinal detachment.<sup>5</sup>



**Fig. 3:**

Rodrigo et al described an interesting case of a 13-year-old child diagnosed with neurofibromatosis type 1 who with a 'macula on' rhegmatogenous retinal detachment associated with dialysis of the ora serrata in the left eye. There was no history of trauma, possibly the mechanism of retinal detachment in that case was by alteration in fibroblasts of the cortex of the vitreous base.<sup>6</sup> This leads to avulsion and in turn maybe related to dialysis of the ora serrata.<sup>7</sup>

Hong-Uyen Hua et al reported a case unusual presentation of NF-1 in pediatric patient with neovascular glaucoma, inflammation and total retinal detachment in whom a multispecialty examination under anaesthesia led to the diagnosis. Additionally, NF-1 patients should have diligent monitoring with fluorescein angiographic assessing the possibility of peripheral ischemia and/or neovascularization for the prevention of retinal detachments.<sup>8</sup>

Oudbib et al described a 15-year-old patient who presented with diminution of vision. There was no history of trauma. Dilated fundus examination revealed a superior retinal detachment due to disinsertion of ora serrata. The exact mechanism of this disinsertion was unknown.<sup>9</sup>

In our case the patient presented with a large plexiform neurofibroma on right upper lid. She did not have any other ocular complaints. On routine fundus examination, we detected an inferior retinal detachment. In this patient the retinal detachment was not only because of neurofibromatosis as she also had high myopia, another risk factor for retinal detachment. However in myopia the RD is usually present superiorly, but in this case we noted inferior RD.

### 4. Conclusion

Neurofibromatosis affects the eyes and is potentially blinding. Routine screening of asymptomatic patients may lead to the early detection of sight threatening conditions like retinal detachment.

Our case emphasizes that importance of performing routine dilated fundus examination in all NF-1 cases. Some potentially sight threatening conditions such as retinal detachment can be detected early and prompt treatment prevented visual loss in our patient.

## 5. Conflict of Interest

Author has no conflict of interest to declare.

## 6. Source of Funding

No funding source.

## References

1. Meyers SM, Gutman FA, Kaye LD, Rothner AD. Retinal changes associated with neurofibromatosis 2. *Trans Am Ophthalmol Soc.* 1995;93:245–52.
2. Martin K, Rossi V, Ferrucci S, Pian D. Retinal astrocytic hamartoma. *Optometry.* 2010;81(5):221–33.
3. Divya D, Kumar NS, Hanumanthappa, Priya V, Jayasimha. A study on ocular manifestations of neurofibromatosis type-1 in rural population of Chittoor district. *MedPulse Int J Ophthalmol.* 2020;13(2):33–7.
4. Maurya RP, Bhushan PB, Singh VP, Singh MK, Kumar M. Recurrent solitary orbital neurofibroma: A rare presentation. *World J Surg Medical Radio Oncol.* 2012;1(8):37–41.
5. Alkatan HM, Bakry SS, Alabduljabbar MA. Ocular Findings in Neurofibromatosis [Internet]. In: Neurofibromatosis - Current Trends and Future Directions. IntechOpen; 2019. [cited 2022 Dec 21]. Available from: <https://www.intechopen.com/state.item.id>.
6. Gärtner J. The fine structure of the vitreous base of the human eye and pathogenesis of pars planitis. *Am J Ophthalmol.* 1971;71(6):1317–27.
7. Clemente-Tomas R, Río NRD, Gargallo-Benedicto A, García-Ibor F, Hervas-Hernández JM, Duch-Samper AM, et al. Retinal detachment with spontaneous dialysis of the ora serrata in a 13-year-old child with neurofibromatosis type 1: A case report. *Indian J Ophthalmol.* 2020;68(7):1473–5.
8. Hua HU, Martens R, Read SP, Cernichiaro-Espinosa LA, Fallas B, Oliver AL, et al. Neurofibromatosis type 1 presenting with retinal detachment and laryngeal plexiform neurofibroma in a toddler. *Am J Ophthalmol Case Rep.* 2021;23:101170. doi:10.1016/j.ajoc.2021.101170.
9. Oudbib M, Ibrahim F, Hajji Z, Boulanouar A, Berraho A. Neurofibromatosis Type 1 Revealed By A Retinal Detachment Caused By A Spontaneous Desinsertion At The Oraserrata. *IOSR J Dent Med Sci (IOSR-JDMS).* 2018;17(6):82–4.

## Author biography

**Kale Satya Geethika**, Junior Resident

**Hannah Ranjee Prasanth**, Professor and HOD

**Karthik Kumar Arumugam**, Vitreoretinal Surgeon

**Karthiga I**, Assistant Professor

**Rohitha Kuppasamy**, Junior Resident

**Cite this article:** Geethika KS, Prasanth HR, Arumugam KK, Karthiga I, Kuppasamy R. Screening saves sight: An unusual case of type-1 neurofibromatosis. *IP Int J Ocul Oncol Oculoplasty* 2023;9(3):137-139.