

Content available at: <https://www.ipinnovative.com/open-access-journals>

IP International Journal of Ocular Oncology and Oculoplasty

Journal homepage: <https://ijooo.org/>

Case Report

Vascular occlusion in a patient with posteriorly dislocated double IOL

Kritika¹, Brij K Gupta¹, Vimal Vashistha¹, Kanav Gupta^{1,*}

¹Dept. of Ophthalmology, NC Medical College and Hospital, Israna, Panipat, Haryana, India



ARTICLE INFO

Article history:

Received 12-05-2023

Accepted 27-06-2023

Available online 08-08-2023

Keywords:

Branch retinal vein occlusion

Vascular occlusion

Posteriorly dislocated IOL

Mobile IOL

Secondary IOL

ABSTRACT

Age and uncontrolled hypertension are well established risk factors for retinal vascular occlusion. IOL (intraocular lens) implantation following intraoperative posterior capsule rupture has an increased risk of IOL dislocation in the posterior segment. We came across a case of infero-temporal branched retinal vein occlusion followed by a direct injury by a mobile IOL which was posteriorly dislocated. The patient also had one another posteriorly dislocated IOL which was stuck in the anterior vitreous. This case highlights the need for the urgent removal of a posteriorly dislocated mobile IOL, which should precede the placement of a secondary IOL to avoid ocular complications.

This is an Open Access (OA) journal, and articles are distributed under the terms of the [Creative Commons Attribution-NonCommercial-ShareAlike 4.0 License](https://creativecommons.org/licenses/by-nc-sa/4.0/), which allows others to remix, tweak, and build upon the work non-commercially, as long as appropriate credit is given and the new creations are licensed under the identical terms.

For reprints contact: reprint@ipinnovative.com

1. Case Report

A 71-year-old male patient came to our Ophthalmology department at N.C Medical college and hospital, Israna with chief complaint of no gain of vision post-cataract surgery which was followed by IOL placement 2 weeks back. A thorough history was taken and the patient told that on the first postoperative day he had posteriorly dislocated IOL. He then underwent a secondary IOL placement after 4 days of first surgery. The patient had no history of any trauma postoperatively.

After taking history patient was thoroughly examined. Best-corrected visual acuity (BCVA) was 20/200 in the right eye and 20/60 in left eye. Intra-ocular pressure of both eyes was within normal limits. Slit lamp examination of right eye revealed vitreous strands superiorly at iris margin, which were not touching the endothelium. An ‘out of the bag’ posteriorly dislocated single-piece intraocular lens (IOL) was noted to be present in anterior vitreous with a large posterior capsular defect. The left eye was having immature

senile cataract on slit lamp examination.

On fundus evaluation using indirect ophthalmoscope of the right eye, fresh intra-retinal hemorrhages were noted in the macular area and hemorrhages were also present along the infero-temporal arcade with sclerosis of branch of inferior arcade. Another single-piece IOL was also visible in the inferior vitreous cavity, which was found to be mobile on supine positioning (Figure 1). Posterior vitreous detachment was also present in the right eye. Left eye fundus examination was within normal limits.

Swept-source OCT of right eye showed sparing of fovea. On Fluorescein Angiography of the right eye, there was delayed filling of infero-temporal arcade and blocked fluorescence due to intra-retinal hemorrhage.

The patient was planned to be managed surgically with pars plana vitrectomy with explantation of both IOLs. Following pars plana vitrectomy due to inadequate sulcus, a secondary IOL could not be placed. Patient was followed up for 2 months. Patient gained postoperative vision of 20/60 with aphakic correction in the right eye at 2 months.

Figure 1 is a Slit lamp image showing an ‘out of the bag’ posteriorly dislocated single piece IOL with one haptic

* Corresponding author.

E-mail address: kanavg@hotmail.com (K. Gupta).

Table 1: Depicts examination finding of patient.

	OD	OS
BCVA	20/200	20/60
IOP	13mm Hg	14mm Hg
Cornea	Oedema+, Descemet membrane folds with Arcus senilis	Transparent Arcus senilis+
Anterior chamber	Vitreous strands superiorly at iris margin, not touching the endothelium	Within normal limits
Lens	Dislocated single-piece IOL was noted in anterior vitreous with a large posterior capsular defect	Immature senile cataract (NS-III)
Fundus	CDR-0.3:1, Posterior vitreous detachment+, FR-dull, IOL resting over inferior retina, Intra-retinal hemorrhages along the infero-temporal arcade with sclerosed vessels.	CDR-0.3:1, FR- dull, background normal.

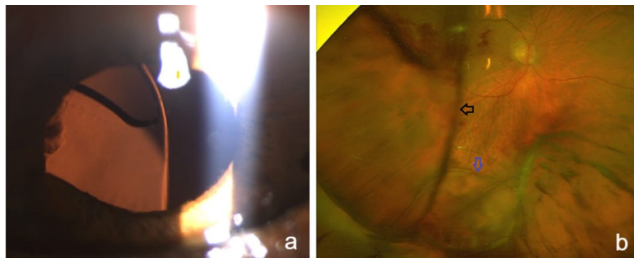


Fig. 1: Slit lamp and Fundus photo showing dislocated IOL

being stuck in the iris tissue and the other haptic placed inside anterior vitreous with a posterior capsular defect.

Figure 1b is the Fundus image taken on OCT showing an IOL along-with one haptic in anterior vitreous (black arrow) and another IOL resting over the inferior retina (blue arrow).

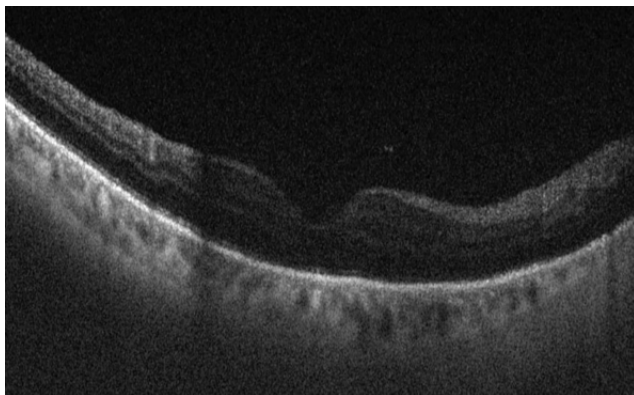


Fig. 2: SD-OCT of macular area.

Figure 2 depicts a SD-OCT image which shows sparing of fovea as no abnormality seen with no edema of macular

area.

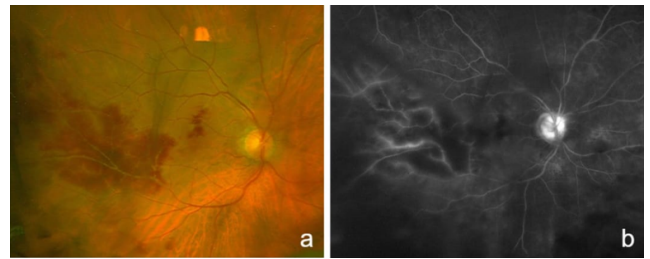


Fig. 3: Fundus image showing branch retinal vein occlusion.

Figure 3a is a Fundus image taken on OCT which shows a magnified view of fundus showing branch retinal vein occlusion in infero-temporal quadrant with area of hemorrhage.

Figure 3b is the image of Fundus Fluorescein angiography showing delayed filling in the infero-temporal arcade and blocked fluorescence due to intra-retinal hemorrhage. The hemorrhage blocks the fluorescein dye to stain the infero-temporal arcade.

2. Discussion

Dislocated IOL is a serious complication following cataract surgery. IOL dislocation has an incidence of 0.2% to 3%.¹ The prevalence of dislocated IOL is increasing.¹ The most common causes for IOL dislocation were previous vitrectomy, myopia and recurrent intra-vitreous injections.¹ The reason for IOL dislocation in this patient is supposed to be posterior capsular rupture. The second IOL placed was also dislocated posteriorly into anterior vitreous with one haptic in iris. IOL dislocation may cause several complications such as vitreous hemorrhage, retinal tears, retinal detachment,² bullous keratopathy, cystoid macular edema and secondary glaucoma.^{3,4}

Our patient presented with dislocated IOL leading to branch retinal vein occlusion. This patient had a possible yet uncommon presentation. Vascular occlusion in this patient has developed most likely due to direct injury to the retinal vein caused by a mobile IOL as there is no history of trauma. As posterior vitreous detachment was also evident clinically, presence of this liquefied vitreous can allow the IOL to freely graze over retina and cause a direct injury to the retinal vessels.

While managing such a case, a pars plana vitrectomy for removal of mobile IOL should always take precedence.⁵ Secondary IOL placement should follow only later, after evaluating adequacy of sulcus otherwise IOL drop can occur again.

3. Conclusion

This case highlights the need for the urgent removal of a posteriorly dislocated mobile IOL, which should

precede the placement of a secondary IOL to avoid ocular complications.

4. Declaration of Patient Consent

The authors certify that they have obtained all appropriate patient consent forms. In the form the patient(s) has/have given his/her/their consent for his/her/their images and other clinical information to be reported in the journal. The patients understand that their names and initials will not be published and due efforts will be made to conceal their identity, but anonymity cannot be guaranteed.

5. Conflict of Interest

None.

6. Source of Funding

None.

References

1. Sella S, Rubowitz A, Sheen-Ophir S. Pars plana vitrectomy for posteriorly dislocated intraocular lenses: risk factors and surgical approach. *Int Ophthalmol*. 2020;41(1):221–9. doi:10.1007/s10792-020-01570-7.
2. Connolly BP, Namara JM, Shah GK, Bauman CR. Retinal Detachment with a Dislocated Posterior Chamber Intraocular Lens. *Arch Ophthalmol*. 2001;119(6):909–11.
3. Davis D, Brubaker J, Espandar L, Stringham J, Crandall A, Werner L, et al. Late in-the-bag spontaneous intraocular lens dislocation; evaluation of 86 consecutive cases. *Ophthalmology*. 2009;116(6):664–70.
4. Ascaso FJ, Huerva V, Grzybowski A. Epidemiology, etiology, and prevention of late IOL-capsular bag complex dislocation: review of the literature. *J Ophthalmology*. 2015;p. 805706. doi:10.1155/2015/805706.
5. Stark WJ, Michels RG, Bruner WE. Management of posteriorly dislocated intraocular lenses. *Ophthalmic Surg*. 1980;11(8):495–7.

Author biography

Kritika, Post Graduate Resident  <https://orcid.org/0000-0002-1973-7948>

Brij K Gupta, Professor and Head  <https://orcid.org/0000-0002-4067-9252>

Vimal Vashistha, Senior Resident

Kanav Gupta, Associate Professor  <https://orcid.org/0000-0003-4119-4756>

Cite this article: Kritika, Gupta BK, Vashistha V, Gupta K. Vascular occlusion in a patient with posteriorly dislocated double IOL. *IP Int J Ocul Oncol Oculoplasty* 2023;9(2):108-110.