

Content available at: <https://www.ipinnovative.com/open-access-journals>

IP International Journal of Ocular Oncology and Oculoplasty

Journal homepage: <https://ijooo.org/>

Original Research Article

Conjunctival autograft with fibrin glue in primary pterygium: Demographic profile, visual, refractive and surgical outcome

Soma Rani Roy^{1,*}, Sujit Kumar Biswas², Fahmida Huque¹, Md. Sazzad Kader¹¹Dept. of Oculoplastic & Ocular Oncology, Chittagong Eye Infirmary, Chattogram, Bangladesh²Dept. of Cornea, Chittagong Eye Infirmary, Chattogram, Bangladesh

ARTICLE INFO

Article history:

Received 19-04-2023

Accepted 19-05-2023

Available online 08-08-2023

Keywords:

Pterygium

Fibrin glue

Spherical equivalent

Free conjunctival autograft

Recurrence

ABSTRACT

Aim: To compare the pre and post-operative visual, refractive and surgical outcome.**Materials and Methods:** It was a prospective interventional study of 56 primary pterygium patients with 12 months follow up. All patients underwent surgery with pterygium excision and conjunctival autograft fixation with fibrin glue without any fixating suture and adjuvant. Pre and post-operative visual acuity, spherical equivalent was compared and surgical outcome were evaluated. All patients were followed up to 12 months.**Result:** The mean age was 42.43 ±13.38 years with male predominance. Seventy five percent (n=42) patients with normal vision (6/5 to 6/12, according to WHO) became 96% (n=54), 4 week post-operatively. Preoperatively, 42.8% (n=24) patients had spherical equivalent up to 1 D followed by 25% (n=14) Plano, 17.9% (n=10) up to 2 D, 5.4% (n=3) up to 3 D, 3.6% (n=2) had more than 3D which post operatively became 57.1% (n=32) up to 1D, 26.8% (n=15) Plano, 12.5% (n=7) up to 2D and there was no patients more than 2D with pre and post-operative comparison, p value of 0.000. There were no recurrence in 12 months follow up.**Conclusion:** Fibrin glue is very much effective in reducing recurrence rate and minimizes the complication with a very good visual outcome within 4 week postoperatively if surgery done carefully.This is an Open Access (OA) journal, and articles are distributed under the terms of the [Creative Commons Attribution-NonCommercial-ShareAlike 4.0 License](https://creativecommons.org/licenses/by-nc-sa/4.0/), which allows others to remix, tweak, and build upon the work non-commercially, as long as appropriate credit is given and the new creations are licensed under the identical terms.For reprints contact: reprint@ipinnovative.com

1. Introduction

Pterygium or surfer's eye is a common ocular surface disorder that appear as wing shaped growth on to the cornea from conjunctiva over the limbus. This is basically fibrovascular tissue occur at the level of palpebral aperture either nasally or temporally or from both sides. This lesion was first described by Sushruta in 1000 BC who is the first recorded ophthalmic surgeon in literature.¹ Pterygium is mostly found in geographic latitude 40° around the equator with a 10 times higher rate than outside it indicating that UV irradiation is responsible for this disease.^{2,3} Though it is presumed that ultraviolet light and inflammation are the

causative factors in the development of pterygium, recent study showed the association of human papilloma virus 16 and 18 in the pathogenesis.^{4,5} Such findings has changed the previous thought of simple degenerative procedure to un regulated cell proliferation as causative factor.⁶ Pterygium may cause visual impairment due to tear film instability and induced astigmatism, cosmetic deformity as well as diplopia due to restricted motility. Though observation is enough for small and non - progressive pterygium, several surgical options with or without adjunct has been developed for successful outcome and to prevent recurrence. Here we studied the demographic profile, visual, refractive and surgical outcome of primary pterygium treated with conjunctival autograft with fibrin glue.⁷

* Corresponding author.

E-mail address: dr.somaroy2020@gmail.com (S. R. Roy).

2. Materials and Methods

This was a prospective interventional study of 56 patients from July 2016 to December 2016. Patients of 20 years or more who had primary pterygium were included in the study. Patient with ocular trauma, other ocular surface disorders, recurrent pterygium, blepharitis were excluded from the study. The study was approved by the local institutional review board (IRB) and conducted according to the principles of the 2013 revision of the Declaration of Helsinki.

Pre-operative visual acuity, refraction, slit lamp examination, intraocular pressure and fundus examination were done in all patients. Post operatively visual acuity, slit lamp examination and fundus examination done in 1st pod, 7th pod and after four weeks. Post-operative refraction done four weeks after surgery. All patients were followed up to 12 months. All surgeries were done by single surgeon. To compare pre-operative and post-operative unaided visual acuity, Chi square test was done. Paired sample t-test was also done to compare pre and post-operative spherical equivalent. The p value of < 0.05 was considered as statistically significant. SPSS software was used for statistical analysis.

2.1. Surgical procedure

Written informed consent for the surgical management of the pterygium was obtained from each patient after discussing the disease process, surgical procedure and chance of recurrence. All surgeries were performed by the same surgeon (SR). Topical tropicamide and phnylephrine combination was installed 10 minutes prior to surgery to minimize per-operative bleeding in non-hypertensive patients

After peribulbar anesthesia with 2% lignocaine and 0.5% bupivacaine, patient's eye was prepared and draped in the usual sterile fashion. Universal lid speculum was used for proper exposure. Westcott Tenotomy scissors was used to cut the head of pterygium near the limbus and to proceed dissect the head of the pterygium from the corneal surface in the direction of the central cornea. The pterygium tissue remaining on the cornea was smoothed by scraping with a crescent knife but some were smoothly removed only by limb forcep with a tangential force. After lifting the free edge of the pterygium, Tenon's capsule tissue was separated from the overlying conjunctiva and pterygium tissue was excised carefully without any injury to medial or lateral rectus muscle and caruncle. Minimal cautery was used to control bleeding. After pterygium excision, the eyeball was rotated downward, and free conjunctival tissue was harvested from the supero-temporal portion of the same eye. The size of the donor conjunctival tissue was 1mm bigger than the wound gap. During collection of the recipient conjunctiva blunt dissection performed to exclude Tenon's

capsule. After application of fibrin glue (commercially available) to the bare sclera, the donor conjunctival tissue was placed to the recipient site without any sutures and left a of 2 mm gap from the sclerocorneal limbus. To stick the graft one minute was the waiting time.(Figure 1)

2.2. Post-operative care

Post operatively patients were followed up at 1st pod, 7th pod, one monthly, 3 monthly, 6 monthly and at 12 months. All patients were treated with topical Homatropine 2% eye drops three times daily for 7 days, topical steroid mixed antibiotic eye drop for one month with a tapering dose, topical artificial eye drop for 3 months and paracetamol as a pain killer for 3 days. Visual acuity, intraocular pressure measurement, slit-lamp biomicroscopy and posterior segment evaluation were done during each visit. Any recurrence of the pterygium or abnormalities in healing and complications such as graft edema, donor site scarring, pyogenic granuloma, or formation of a conjunctival inclusion cyst were carefully screened. Post-operative refraction was done after four weeks (one month). Recurrence of the pterygium was defined as invasion of fibrovascular tissue beyond the corneal limbus.

3. Result

The mean age of study population was 42.43 ±13.38 years and range was 20 to 78 years. Fifty percent patients (n=28) presented between 20 to 40 years. Forty three percent patients were within 41 to 60 years age group and only 7% were above 60 years. There were male predominance and was about 86% (n=48). Pre-operatively 75%(n=42) patients presented with normal vision (6/5 to 6/12) according to WHO guideline and 4 week post-operatively normal vision was 96%(n=54). Nine percent (n=5) in mild and 16% (n=9) patients were in moderate category of visual impairment which become zero and 4% (n=2) respectively after four week of surgery. The post-operative visual outcome was statistically significant (p =0.000) [Table 1]

Regarding grading of pterygium, grade 2 was the most frequent presentation and was 64.3% (n=36), followed by grade 3(21.4%) and Grade 1(14.3%) Left eye (59%, n=33) pterygium was more than the right eye. Thirty four (60.7%) patients presented with nasal sided pterygium, 18 patients (32.1%) with temporal sided and 4 patients (7.1%) with both sided pterygium.

Preoperative spherical equivalent of 25% (n=14) patients had Plano, 42.8% (n=24) had up to 1 D, 17.9% (n=10) had up to 2 D, 5.4% (n=3) had up to 3 D, 3.6% (n=2) had more than 3D. Post operatively it became 26.8% (n=15) Plano, 57.1% (n=32) up to 1D, 12.5% (n=7) up to 2D and there was no patients more than 2D. Due to mature cataract, refraction cannot be done in one patient and pre operatively 2 patients (3.6%) had irregular reflex due to pterygium which resolved

Table 1: Pre and post-operative (after 4 week) unaided visual acuity

Static Visual Acuity (%)	Normal (%)	Mild (%)	Moderate (%)	Severe (%)	Total (%)	Mean \pm SD	P-Value
Pre-operative	75.0	9.0	16.0	0	100.0	0.2500 \pm 0.27765	0.000
Post-operative	96.0	0	4.0	0	100.0	0.0875 \pm 0.15732	

Chi-square test

Normal, presenting visual acuity 6/5 to 6/12; mild, presenting visual acuity worse than 6/12; moderate, presenting visual acuity worse than 6/18; severe, presenting visual acuity worse than 6/60).⁶

after pterygium surgery. The comparison of pre and post-operative spherical equivalent was statistically significant (p-value was 0.004). [Table 2]

Eighty two percent (n=46) patients presented with pterygium without other surface disorder, 14.3% (n=8) was associated with immature cataract and 3.5% (n=2) patient was pseudophakic.

There were varieties of occupation among the pterygium patients and 64.3% (n=36) were outdoor worker. Among outdoor worker, farmer were more (14.3%, n=8). The rest 35.7% were indoor worker and among them housewives were more (12.5%, n=7)

Regarding complication, two cases (3.6%) presented with graft retraction, one case (1.8%) with granuloma formation and one case (1.8%) with dellen formation. There was no recurrence in 12 months follow up.

4. Discussion

Pterygium is one of the oldest reported ocular disease in literature. Its prevalence depends on the location of the area and maximum prevalence (33%) has been reported in a Chinese study.⁸ According to Cameron, pterygium belt lies between 37° north and south of the equator and Bangladesh also lies in this belt as it is situated 23° north to the equator. India which is our nearby country, the prevalence of pterygium is 9.52 to 13% and most prevalent in rural area but there is no published data regarding Bangladeshi patients.⁹ In our study, we also studied some demographic data along with pre and post- surgical status of pterygium patients. Mean age of study population was 42.43 \pm 13.38 years and 50% (n=28) presented between 20 to 40 years. According to literature common presenting age for primary pterygium is 20 years onward and pick incidence is reported in age range of 20 to 40 years.¹⁰ According to Fekadu et al, there are diversity in gender distribution worldwide. He showed two times male predominance in studies from Ethiopia, Australia, China, Indonesia and Central India; female predominance in one study from South Korea; where's some study from Japan, China and Iran showed no sex differentiation.¹¹ Our study also showed male predominance and it was (86%).

There are different grading system for primary pterygium and recurrent pterygium. For primary pterygium grading system proposed by Verma et al, Tan et al and Maheshwari are used.² Prabhasawat et al. and Hirst proposed grading

system for recurrent pterygium. In our study we used the simplest grading system proposed by Verma et al. where the size of pterygium was measured from the limbus and grade 1 is described as length of pterygium up to 2 mm, grade 2 as 2 to 4 mm and grade 3 as more than 4 mm. In the present study 64% patients were in grade 2.¹²

The main complication of pterygium is astigmatism due to change of corneal curvature but this change cannot be evaluated properly by refraction or keratometry because this changes happen to nasal part of paracentral cornea in the horizontal meridian. According to Shahraki et al, to evaluate corneal topographic changes in pterygium patients computerized videokeratography may be the best option.² In our study we did pre and four weeks postsurgical refraction to see the surgical outcome. The preoperative mean spherical equivalent was 0.1487 \pm 1.05147 and postoperative mean was 0.4221 \pm 1.23505. The p-value was 0.004, which was statistically significant. According to literature, corneal topographic changes that occur due to pterygium is reversible after pterygium surgery.¹³ The paired t-test showed that current study indirectly support this statement. One recent study from Ghana, showed significant decrease of postoperative astigmatism after 2 weeks and 4 weeks of pterygium surgery and p value was < 0.001 which was measured by keratometry.¹⁴

According to WHO guideline, pre operatively our 75% patients were within normal range of visual acuity (6/5 to 6/12). Four weeks after pterygium surgery 96% patients were with in normal range. Sixteen percent patients were in moderate group (worse than 6/18) which became 4% in post operatively. The mean of preoperative visual acuity was 0. 0.2500 \pm 0.27765 and four weeks after surgery was 0.0875 \pm 0.15732. The chi square test showed the p value is 0.000 which is statistically significant. In one study the p value of pre and postoperative visual acuity was found 0.009, six week after pterygium surgery which was done in 100 patients.¹⁴

Different studies has proved that person who exposed to sunlight and dust are vulnerable for occurrence of pterygium¹¹ and our study showed the same thing. Among different occupations, outdoor workers were 64% and among them farmers (14%) were more. The present study also showed about 38% patients were indoor worker and interestingly most were house wives (12.5%). The probable causes may be, house wives are exposed to heat during

Table 2: Comparison of Pre & Post - operative Spherical equivalent

Content	Mean \pm SD	P Value of T Test
Pre & Postoperative Spherical Equivalent		
Pre-surgical Spherical Equivalent	0.1487 \pm 1.05147	.004
Post-surgical Spherical Equivalent	0.4221 \pm 1.23505	
Pre & Postoperative Minus Correction		
Without Minus Pre	0.5868 \pm .88157	.029
Without Minus Post	0.7851 \pm 1.03860	

Paired sample t- test.

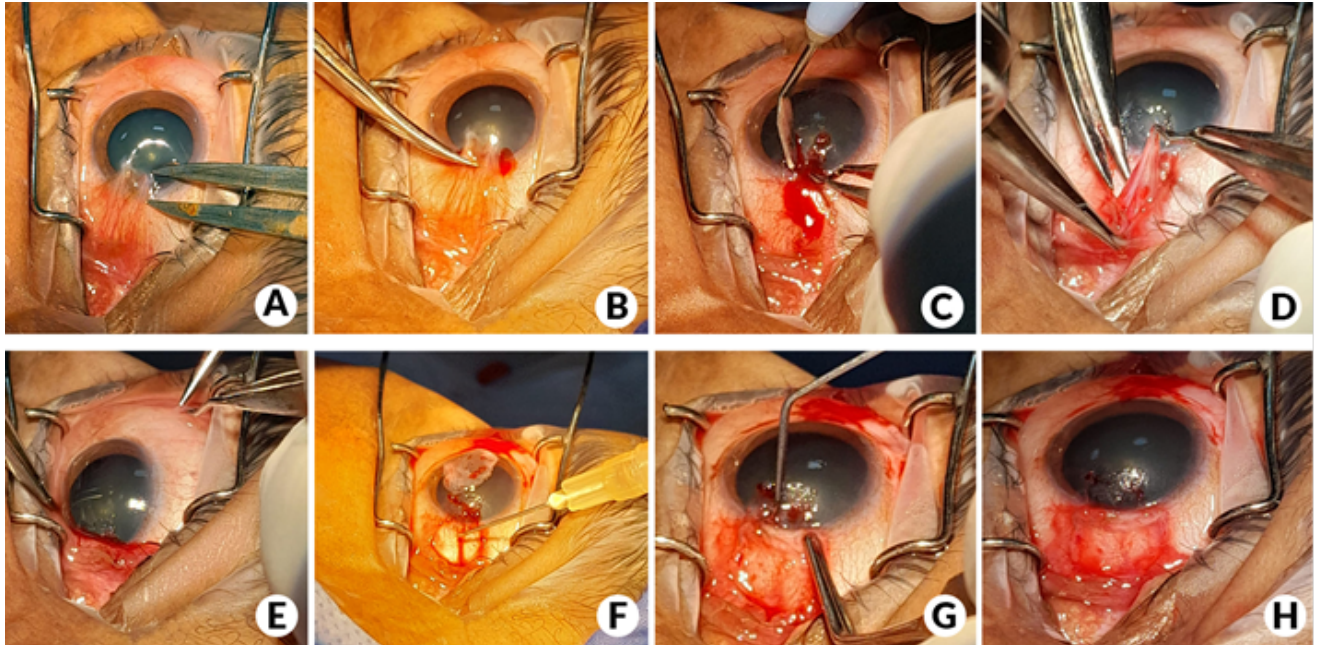


Fig. 1: **A:** Measuring of size of pterygium; **B:** Cutting the head of pterygium near the limbus to proceed dissection; **C:** Remaining pterygium tissue on the cornea was smoothed by scraping with a crescent knife; **D:** After separating from Tenon's capsule, pterygium tissue was excised carefully without any injury to medial rectus and caruncle; **E:** Free conjunctival tissue was harvested from the supero-temporal portion of the same eye; **F:** Application of fibrin glue to the graft site; **G:** The donor conjunctival tissue was placed to the recipient site without any sutures and left a of 2 mm gap from the sclerocorneal limbus; **H:** Graft – after one minute.

cooking and some are also involved during harvesting season.

All cases of current study was done by single surgeon, with commercially available fibrin glue and without any adjuvant. The main complication of pterygium surgery is recurrence. In the literature the recurrence rate of pterygium excision with autograft for primary pterygium is lower than 15%, though the overall rate is 1 to 40%. This rate with adjuvants like MMC, 5 FU, bevacizumab, cyclosporin is 0%- 16.7 % after 3 months and 3.3% - 16.7% after 6 months of surgery.² In our study there was no recurrence up to 12 months follow up and success rate is 100%. One Cochrane database systemic review showed the success rate of 93.8% in patients with conjunctival limbal autograft group and 93.3% with amniotic membrane transplant group after 3 months of pterygium surgery.¹⁵ Though there are various techniques for conjunctival fixation in pterygium

surgery, recently many surgeons are using fibrin glue as an alternative of suture material and autologous blood for graft secure. This glue is costly, carries chances for infection transmission, graft retraction and chance of dehiscence is more but its easy application technique, shorter time for surgery made it popular. Beside this, use of fibrin glue showed less recurrence rate in comparison to suture (5.3% vs 13.5%).¹⁶ One comparison study of conjunctival graft fixation with fibrin glue, suture and autologous blood showed recurrence rate is less in glue group. This study also showed less ocular discomfort and comparably less operation time.¹⁷ According to another meta- analysis, fibrin glue proved its prominent effectiveness in reducing recurrence without raising complication rate.¹⁸ In the current study, early postoperative complication was graft retraction in two cases (3.8%) which were managed by repeat glue application. One case of granuloma was

managed by excision and another case of dellen was healed by frequent application of artificial tear.

Our study has some limitations such as

1. Visual acuity did not measured in log MAR.
2. Dry eye was not considered while measuring visual acuity.
3. Only calipers was used to measure the extent of pterygium instead of slit lamp measurement.
4. There was single surgeon surgery might affect the outcome.

5. Conclusion

This study shows that fibrin glue is very much effective in reducing recurrence rate and minimizes the complication if surgery done carefully. The stable postoperative visual outcome is possible four weeks post operatively.

6. Conflicts of interest

Authors declared no conflicts of interest.


7. Source of Funding

None.


References

1. Rosenthal JW. Chronology of pterygium therapy. *Am J Ophthalmol.* 1953;36(11):1601–6.
2. Shahraki T, Arabi A, Feiz S. Pterygium: an update on pathophysiology, clinical features, and management. *Ther Adv Ophthalmol.* 2021;13:25158414211020152. doi:10.1177/25158414211020152.
3. Gupta A, Maurya RP, Manisha, Kadir SMU, Patel A, Devi A, et al. Recent update on pterygium. *IP Int J Ocul Oncol Oculoplasty.* 2022;8(2):95–108.
4. Lee JS, Ha SW, Lee GJ, Park YJ. Efficacy and Safety of a Large Conjunctival Autograft for Recurrent Pterygium. *Korean J Ophthalmol.* 2017;31(6):469–78.
5. Chong PP, Tung CH, Rahman NA, Yajima M, Chin FW, Yeng CLS. Prevalence and viral load of oncogenic human papillomavirus (HPV) in pterygia in multi-ethnic patients in the Malay Peninsula. *Acta Ophthalmol.* 2014;92(7):569–79. doi:10.1111/aos.12427.
6. Sarkar P, Tripathy K. Pterygium. Treasure Island (FL): StatPearls Publishing; 2022. [2022 Aug 22].
7. World Health Organization. Vision impairment and blindness. [Accessed June 28, 2019]. Available from: <https://www.who.int/news-room/factsheets/detail/blindness-and-visual-impairment>.
8. Wu K, He M, Xu J, Li S. Pterygium in aged population in Doumen County, China. *Yan Ke Xue Bao.* 2002;18(3):181–4.
9. Prasad SC, Goudinho SJ, Isaac SM, Sumangala SG. Sutureless Versus Suture Technique for Conjunctivolimbus Autografting in Primary Pterygium Excision: A Prospective Study. *Middle East Afr J Ophthalmol.* 2022;28(4):208–10.
10. Noor RA. Primary pterygium in a 7-year-old boy: a report of a rare case and dilemma of its management. *Malays J Med Sci.* 2003;10(2):91–2.
11. Fekadu SA, Assem AS, Adimassu NF. Prevalence of pterygium and its associated factors among adults aged 18 years and above in Gambella town. *PLoS One.* 2019;15(9):237891. doi:10.1371/journal.pone.0237891.
12. Sarkar P, Tripathy K, Pterygium, Statpearls. 2023. Available from: https://www.ncbi.nlm.nih.gov/books/NBK558907/#_ncbi_dlg_citbx_NBK558907. Accessed.
13. Wu PL, Kuo CN, Hsu HL, Lai CH. Effect of pterygium surgery on refractive spherocylinder power and corneal topography. *Ophthalmic Surg Lasers Imaging.* 2009;40(1):32–7. doi:10.3928/15428877-20090101-20.
14. Amoah K, Lartey SY, Mohammed AK, Ahmed AS, Arthur KAN, Kyei EN, et al. Changes in Astigmatism and Visual Acuity after Pterygium Excision in the Ashanti Region of Ghana. *The Annals of African Surgery.* 2022;19(2):86–93.
15. Clearfield E, Muthappan V, Wang X, Kuo IC. Conjunctival autograft for pterygium. *Cochrane Database Syst Rev.* 2016;2:CD011349. doi:10.1002/14651858.CD011349.pub2.
16. Koranyi G, Seregard S, Kopp ED. Cut and paste: a no suture, small incision approach to pterygium surgery. *Br J Ophthalmol.* 2004;88(7):911–914. doi:10.1136/bjo.2003.032854.
17. Kumar S, Singh R. Pterygium excision and conjunctival autograft: a comparative study of techniques. *Oman J Ophthalmol.* 2018;11(2):124–8. doi:10.4103/ojo.OJO_6_2017.
18. Lan A, Xiao F, Wang Y, Luo Z, Cao Q. Efficacy of fibrin glue versus sutures for attaching conjunctival autografts in pterygium surgery: a systematic review with meta-analysis and trial sequential analysis of evidence. *Oncotarget.* 2017;8(25):41487–97.

Author biography

Soma Rani Roy, Consultant and Head of of Oculoplastic & Ocular Oncology  <https://orcid.org/0000-0002-7095-4489>

Sujit Kumar Biswas, Consultant and Head of Cornea  <https://orcid.org/0000-0002-7006-5788>

Fahmida Huque, Senior Assistant Surgeon  <https://orcid.org/0000-0001-8777-6765>

Md. Sazzad Kader, Senior Assistant Surgeon

Cite this article: Roy SR, Biswas SK, Huque F, Kader MS. Conjunctival autograft with fibrin glue in primary pterygium: Demographic profile, visual, refractive and surgical outcome. *IP Int J Ocul Oncol Oculoplasty* 2023;9(2):77-81.