

Content available at: <https://www.ipinnovative.com/open-access-journals>

IP International Journal of Ocular Oncology and Oculoplasty

Journal homepage: <https://ijooo.org/>

Original Research Article

Optical biopsy – Optical coherence tomography guided excision of ocular surface squamous neoplasia

Dhivya Ashok Kumar^{1,*}, Amar Agarwal²¹Dept. of Oculoplasty, Ocular Oncology and Uvea, Dr. Agarwal's Eye Hospital and Eye Research Centre, Chennai, Tamil Nadu, India²Dr. Agarwal Eye Hospital and Eye Research Centre, Chennai, Tamil Nadu, India

ARTICLE INFO

Article history:

Received 07-12-2022

Accepted 21-12-2022

Available online 20-02-2023

Keywords:

Histopathologically

Conjunctival

Ocular surface neoplasia

Optical biopsy

OCT features

Conjunctival margin

ABSTRACT

Purpose: To report the role of optical biopsy where the preoperative spectral domain optical coherence tomography (SD OCT) features were used for surgical margin clearance in ocular surface squamous neoplasia (OSSN) excision.

Materials and Methods: In this prospective interventional study patients with clinically diagnosed OSSN undergo preoperative SD OCT and mass was excised with 3mm clearance with respect to the extent on OCT. Corneal, conjunctival margins and lamellar sclera was evaluated histopathologically.

Results: Twelve eyes of 11 patients with mean age of 59.2 ± 12.2 were studied. Hyper reflective epithelium, increased thickness, abrupt transition of corneal epithelium and increase back shadow were the features of OSSN noted. The mean functional epithelial thickness and epithelial thickness were $137.5 \pm 60.6 \mu\text{m}$ and $58.5 \pm 10.8 \mu\text{m}$ respectively. The histopathology confirmed as squamous cell carcinoma (SCC) (n=4, 33.3%), carcinoma in situ (CIN) (n=8, 66.6%). In CIN 2 eyes were severe dysplasia and 6 were moderate dysplasia. Corneal clearance was noted as 100 %. Of 36 conjunctival margins, the positive margin noted in 6 eyes (50%). Nasal margin (n=3) and temporal (n=3) were the common margins. There was no difference in clearance between CIN (50%) or SCC (50%) on conjunctival side. Two eyes with recurrence required and revision excision with subsequent chemotherapy.

Conclusion: Optical biopsy by SD OCT though is an effective method for OSSN removal. Corneal margins showed better margin clearance than conjunctival.

This is an Open Access (OA) journal, and articles are distributed under the terms of the [Creative Commons Attribution-NonCommercial-ShareAlike 4.0 License](https://creativecommons.org/licenses/by-nc-sa/4.0/), which allows others to remix, tweak, and build upon the work non-commercially, as long as appropriate credit is given and the new creations are licensed under the identical terms.

For reprints contact: reprint@ipinnovative.com

1. Introduction

Ocular surface tumours are one of the ocular surface disorders noted in routine ocular oncology practice. Ocular surface squamous neoplasia (OSSN) forms the main component of ocular surface tumours. It encompasses a spectrum of pathological lesions ranging from the pre-invasive dysplasia to an invasive squamous cell carcinoma (SCC).^{1,2} There have been many advances in the evaluation and management of OSSN in the recent past.³⁻⁹ Though,

there are several newer modalities of management like immunotherapy and chemotherapy, the gold standard is still the surgical excision. Optical coherence tomography (OCT) has been used for numerous indications in the diagnosis and management of ophthalmic disorders.¹⁰⁻¹³ The advantage of OCT is the non-invasive and user friendly method. However, there are limited studies on their use in OSSN excision. We have used preoperative spectral domain Optical coherence tomographic (SD-OCT) to measure the amount of surgical clearance required and compared the operative outcomes and termed it as 'optical biopsy'. Determination of nature of lesion by identifying the features

* Corresponding author.

E-mail address: susruta2002@gmail.com (D. A. Kumar).

on OCT is the optical biopsy and using the same for planning for removal has been performed.

2. Materials and Methods

The prospective study was initiated after the approval by the Institutional review board (IRB). Informed consent was obtained and the study followed the Tenets of Declaration of Helinski. Patients undergoing surgical excision for clinically diagnosed OSSN from January 2012 to January 2018 were included. The preoperative assessment included slit lamp biomicroscopy, OCT of the mass lesion, visual acuity (Snellen distant visual acuity in decimal equivalent), intraocular pressure (non-contact tonometer in mmHg), digital slit lamp photography (Topcon, Japan), fundus examination and lymph node examination.

2.1. Optical biopsy

Determination of nature of lesion by identifying few changes on OCT has been termed as optical biopsy (by D.A.K). The reflections texture, thickness and configuration can be used to differentiate a benign and a malignant lesion.

2.2. Determination by OCT

The SD OCT (Ivue, Optovue, Fremont, USA) we utilized has 840 nm wavelength light with a pupil exposure of 750 μ W and had acquired 26,000 A scans per second with a frame rate of 256 to 1024 frames per second. The depth resolution in tissue was 5 μ and transverse resolution was 15 μ . The line scan in the anterior segment module was performed in both longitudinal (on the mass) and cross-sectional (vertical line scan across the mass) axes within 24-72 hours from surgery (Figure 1A,B). Line scan was taken on the corneal side at every 0.2mm for extent of epithelial involvement (FIG 2). Surgical clearance was executed with respect to the extent of lesion on OCT. Epithelial thickness (ET μ m) on the cornea, Junctional epithelial thickness (JET μ m) at the junction of limbus and lesion, Height of lesion (μ m), length (mm) and subepithelial infiltration (mm) were quantified. Tear film presence and the tear meniscus height (μ m) were evaluated. All SD OCT scans and subsequent surgery were performed by single investigator (D.A.K). Preoperative clinical grading of tumour was done according to American joint committee on cancer.¹⁴

2.3. Features of malignancy

Abnormal hyper-reflective epithelium, encroachment on cornea, snout sign at the limbus and surface infiltration with abrupt transition of epithelium were considered for suspicious signs of malignancy (Figure 2).

2.4. Excision of the mass by no touch technique

With sterile precautions in operating room, under peribulbar anesthesia, the 3mm surgical clearance mark surrounding the mass was marked with gentian violet with respect to the measurements obtained from the SD OCT. Corneal epithelium was peeled by applying alcohol. Cotton gauze soaked in 20% ethyl alcohol was placed in the rim of the exposed corneal epithelium adjacent to the limbal mass for 30 sec, and then corneal epithelial debridement was performed. The mass with 3-mm margins was excised by “no-touch technique”.¹⁴ A thin lamellar scleral flap to confirm the depth of penetration was also sent for histopathology examination (HPE). A double freeze, slow thaw cryotherapy of the conjunctival margins was then executed. The raw surface was covered by preserved amniotic membrane graft (AMG) or directly closed with 6-0 polyglactil sutures. Each specimen was carefully oriented with respect to its anatomic location, mounted on a piece of cardboard and marking of margins done. Histopathology section was sent as (1) corneal margin, (2) conjunctival margins as superior, nasal or temporal (depending on the position of lesion) and inferior (3) scleral bed. All tissue was fixed in formalin and embedded in paraffin. Sections were cut in 5-mm thickness and stained with hematoxylin–eosin. Postoperatively, the patient was started on four hourly topical antibiotic steroid combination and two hourly topical lubricants for 2 weeks and tapered subsequently.

Histopathology was classified as preinvasive (carcinoma in situ-CIN) and invasive (SCC). Preoperative OCT morphology was compared with the margin clearance and the histopathological outcomes. Surgical clearance was defined as tumour free margins in all the margins, the tumour free corneal side and the tumour free deep sclera. Surgical clearance with one positive margin was considered as incomplete clearance. Recurrence was defined as any lesion appearing in the already surgically excised region. New tumour was defined as any lesion which appears in a site not surgically excised before. Postoperative uncorrected visual acuity (UCVA), best corrected visual acuity (BCVA), OCT, Slit lamp examination and IOP were recorded on follow up.

2.5. Statistical analysis

Data was entered using excel software (Microsoft corp.) and analyzed by SPSS (version 21; IBM SPSS Statistics for Windows, Version 21.0. Armonk, NY: IBM Corp.). Data normality was tested by Shapiro Wilk normality test and the data distribution was noted to be normal. Non parametric test was used for analysis. Correlation was performed by Pearson bivariate correlation test. All visual acuity data (BCVA) were converted into decimal values for analysis. A p value less than or equal to 0.05 was considered statistically significant.

3. Results

Overall 12 eyes (Table 1) of 11 patients were included. Out of 11 patients, 10 had unilateral disease and 1 had bilateral. The mean age of patients was 59.2 ± 12.2 years (8 males and 3 females). There were 2 giant OSSN and 10 non giant OSSNs. All non-giant OSSNs presented as interpalpebral mass at limbus. Clinically corneal involvement was noted in 6 eyes. Conjunctival closure was performed by amniotic membrane grafting direct conjunctival closure and AMG in 9 and 3 eyes respectively (Figure 3). The mean follow up was 21 ± 12.6 months.

3.1. Optical biopsy

The mean ET and JET were $58.5 \pm 10.8 \mu\text{m}$ (range 42-77 μm) and $137.5 \pm 60.6 \mu\text{m}$ (range 64-278 μm). The mean horizontal and the vertical dimension as measured by OCT were $3.9 \pm 2.6 \text{ mm}$ and $3.8 \pm 1.2 \text{ mm}$ respectively (Table 2). The mean height or elevation above the conjunctival surface was $517.7 \pm 333.6 \mu\text{m}$. Hyperkeratosis was visualized as hyper reflective surface in SD OCT in 12 eyes. Corneal involvement was observed in 12 eyes on OCT. The subepithelial infiltration of growth was noted as hyper-reflective extension beneath the epithelium beyond the visible mass (Fig 2) measuring about $1.4 \pm 1.2 \text{ mm}$. Surface pigmentation was noted in 3 out of 12 eyes (25%). Posterior Back-shadowing was seen in all lesions on OCT. There was significant correlation between the height and the length of the lesion ($p=0.000$, $r=0.85$). The longer the dimension, greater was the height of the mass. There was no statistical correlation between the height of the lesion and the length of subepithelial infiltration ($p=0.510$) on OCT and the length and the sub-epithelial infiltration ($p=0.417$).

Out of 12, there were 8 non-invasive and 4 invasive lesions. The histopathological classification of invasive type was well differentiated squamous cell carcinoma (SCC) ($n=2$) and moderately differentiated SCC ($n=2$). On the other hand, carcinoma in situ (CIN) with moderate dysplasia ($n=6$, 75%) and severe dysplasia ($n=2$, 25%). There was no association between the histopathology and the age of patient (Chi-square value: 12, $p=0.213$), the mass length (Chi-square value =9, $p=0.437$), the external pigmentation (Chi-square value:2, $p=0.157$) and the surface hyperkeratosis (Chi-square value:0.188, $p=0.665$). 3 out of 8 males (37.5%) had invasive type. There was no association between the Sub epithelial infiltration extent and histopathology (Chi square value 9, $p=0.342$).

The mean largest basal dimension of invasive and pre-invasive OSSN was $7.1 \pm 3.4 \text{ mm}$ and $3.6 \pm 0.6 \text{ mm}$ respectively. There was statistically significant difference in dimension between the 2 groups ($p=0.008$). The invasive lesions were larger in size than preinvasive. Even though the mean SEI was higher in invasive lesion ($2 \pm 2.1 \text{ mm}$) as compared to CIN (1.1 ± 0.5) no statistical difference was

noted ($p=0.714$).

3.2. Surgical margin

Corneal margin clearance was noted to be 100 % in all eyes. Out of 12 eyes, conjunctival margin positivity in the specimen on histopathology was noted in 6 eyes (50%). It included nasal ($n=3$) and temporal ($n=3$). Two margins positivity was seen in 3 eyes and temporal was common in all of them. Of all the 36 margins, incidence of inferior ($n=1$) and superior margin ($n=1$) positivity was less. Both CIN and SCC showed 50% clearance on the conjunctival side. Deep sclera was not involved in any of the eyes. There was no association between the positive or negative margin appearance and nature of lesion (CIN or SCC) (Chisquare, $p=1$).

3.3. Follow up

The mean follow up was 4 years. One patient required lubricants (carboxy methyl cellulose 1%) for dry eye. Mild conjunctival hyperemia was seen in one patient on topical MMC. All patients with well differentiated or invasive SCC were started on MMC 0.04% for 1 month postoperative period. Postoperative SD OCT showed regular limbal surface with absence of preoperative hyper reflective elevation and regular scarring (Figure 4).

3.4. Recurrence

Two out of 12 eyes (16.6%) in the series showed recurrence of lesion after surgery. The recurrence was 3 months in one patient and 12 months in other patient. The histopathology of the recurrent lesion was invasive SCC (2 margins showed positive) and moderate dysplasia (1margin positive). The patient with invasive SCC required resurgery with mass excision followed by topical chemotherapy eye drops mitomycin (MMC) 0.04%, 4 times daily, week on week off therapy for 3 months. The eye with moderate dysplasia recurrence was managed by topical mitomycin (MMC) 0.04% 4 times daily, week on week off therapy for 1 month. There was significant visual improvement after OSSN excision in UCVA (0.05) and BCVA (0.018). No significant increase or drop in intraocular pressure noted ($p=0.722$).

4. Discussion

The ocular surface squamous neoplasia is the common non pigmented neoplasia. Squamous neoplasia is often diagnosed clinically with characteristics like (1) surface keratin deposition (2) fast growing mass papillomatous /gelatinous/leucoplakic type (3) intrinsic vasculature and surrounding sentinel vessels. Even after clear preoperative evaluation, the surgical recurrence in OSSN has been reported upto 33%.¹⁵ There have various tests starting from

Table 1: Demographics of patients

Eye	Age	Gender	Side	UCVA Preop	UCVA Postop	BCVA Preop	BCVA Postop	Preop IOP	Postop IOP
1	67	M	OD	0.01	1	0.01	1	10	11
2	60	F	OD	0.33	0.33	0.33	0.66	10	14
3	60	F	OS	0.25	0.33	0.25	1	10	14
4	58	M	OS	0.05	0.66	0.05	1	12	14
5	52	M	OS	1	0.66	1	1	11	10
6	46	F	OD	0.5	1	0.66	1	17	18
7	88	M	OS	0.25	0.33	0.5	0.5	13	9
8	39	M	OS	0.25	0.17	1	1	15	14
9	53	M	OS	1	1	1	1	18	15
10	64	M	OS	0.5	0.5	1	1	11	14
11	57	M	OS	0.5	1	0.66	1	12	14
12	67	F	OD	0.1	0.5	0.25	0.5	19	14

UCVA: Uncorrected visual acuity, BCVA:Best corrected visual acuity, IOP:Intraocular pressure, M:Male, F:Female

Table 2: Optical biopsy details of operated eyes

Eye	ET (µm)	JET (µm)	Length (mm)	Width (mm)	Height (µm)	Histology	SEI (mm)	Pigmentation	Hyperkeratosis
1	68	153	12	4	1500	SCC	ND	no	yes
2	58	153	3	3.5	300	CIN	ND	no	no
3	45	170	2	2.67	348	CIN	ND	no	yes
4	77	104	3.35	3	484	CIN	0.999	yes	yes
5	72	162	4	5	351	CIN	1.35	no	yes
6	59	192	3.7	2.9	531	CIN	0.803	no	no
7	58	96	3.46	3	342	CIN	1.06	yes	yes
8	54	65	4	4.5	400	SCC	1.1	no	no
9	46	278	1.71	5	447	SCC	0.6	no	yes
10	65	124	2.4	3.2	750	CIN	1.97	no	yes
11	58	90	4	3	300	CIN	0.5	yes	no
12	42	64	4.29	7	460	SCC	4.48	no	yes

ET: Epithelial thickness, JET: Junctional epithelial thickness, SCC:Squamous cell carcinoma, SEI: Sub epithelial infiltration, CIN: Carcinoma in situ

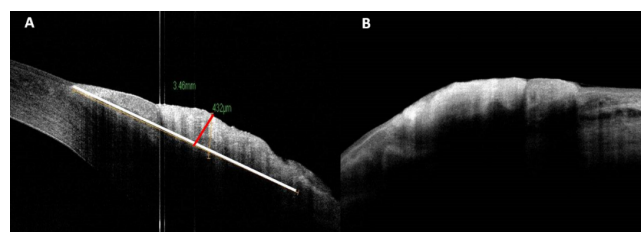


Fig. 1: The line scan in the anterior segment optical coherence tomography in both longitudinal (A) (on the mass) and cross sectional (vertical line scan across the mass) axes (B). White line: length, red line: height.

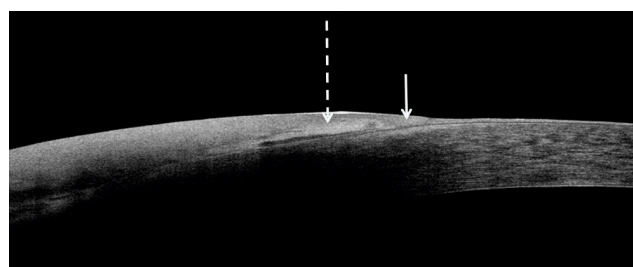


Fig. 2: Serial Line scans taken on the corneal side at every 0.2mm for extent of epithelial involvement using optical coherence tomography. Mass lesion epithelial thickness transition (arrow head) and hyperkeratosis can be seen as hyper reflective layer (dotted arrow).

vital dye staining to imaging analysis like ultrasound biomicroscopy and radiological analysis. According to the histological classification of epithelial neoplasia, change in polarity, nuclear –cytoplasmic ratio, hyperkeratosis, and mitotic changes are considered as dysplasia. Dysplasia can be mild, moderate and severe. Severe dysplasia involving all layers of the epithelium without involving the basement membrane has been described as intraepithelial

neoplasia. When the basement membrane is breached and the underlying stromal tissue is involved, it is described as invasive carcinoma. Depending upon the status of differentiation of squamous cells, it has been identified as well differentiated to poorly differentiated squamous cell carcinoma.

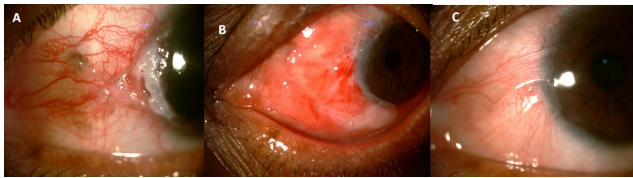


Fig. 3: Preoperative (A), day 1 postoperative (B) and 4 months postoperative clinical picture of OSSN.

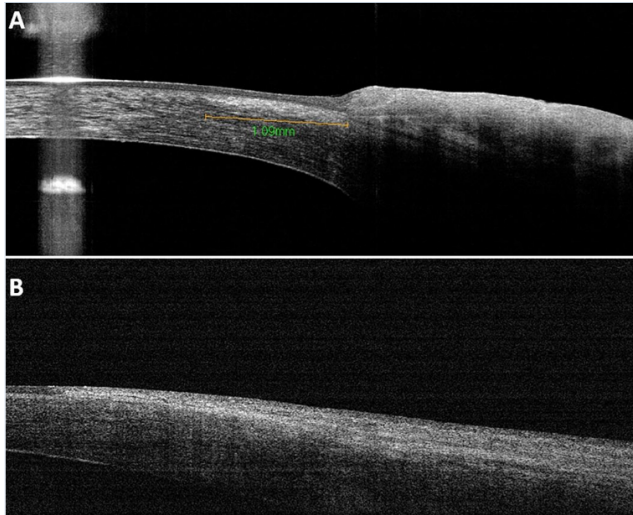


Fig. 4: Preoperative (A) and postoperative (B) SD OCT showing scar as hyperreflective surface

Optical coherence tomography is a non-invasive method of evaluation of OSSN. Karp et al has studied the use of high definition OCT in surgical management of OSSN and reported that optical identification of tumor margins could potentially decrease the incidence of residual positive margins, and minimize healthy tissue removal.¹⁵ HD OCT evaluation in OSSN has been shown as hyper reflective masses and abrupt epithelial thickening.^{15,16} Though the studies have used preoperative evaluation of OSSN for morphological assessment, there are very few reports on commercially available FD OCT guided excision. Karp et al has utilized HR OCT for guided excision and noted that it has the potential to predict histologic tumor margins in OSSN.¹⁵

Optical biopsy is the term used to assess the malignancy features by OCT before histopathology. OCT features like epithelial thickness and junctional epithelium are predominantly affected in malignancy. Hyperkeratotic reflective layer coincides with the increased epithelial thickness. The abrupt transition of epithelium named as junctional region epithelium is also thicker than normal epithelium. Though corneal side clearance was possible 100%, conjunctival side was not attained in all eyes. Only 50% clearance on conjunctival side was observed. Separate delineation of layers due to collagen texture on the corneal

side may be the reason for better clearance prediction on corneal side as compared to the conjunctival side. Though studies have taken hyper reflectivity as surrogate marker for tumour extent, comparison of corneal and conjunctival clearance has not been reported earlier.^{15–17} We observed that 3mm clearance was also not enough to give complete clearance even in small lesions like dysplasia. However, planning for larger excision of conjunctiva can lead to excess scar and limbal stem cell deficiency. Hence, it is often preferred to do Moh's surgical excision. However, in developing countries due to the non-availability for Moh's microsurgical centers, we may have to rely on conventional biopsy. Surgical excision followed by topical chemotherapy for margin positive cases has been shown to have better outcomes as against direct chemotherapy.¹⁸

A preoperative optical biopsy with the routinely available SD OCT using an anterior segment adapter with the tissue resolution upto 5 microns can aid the surgeon to prepare the extent of excision; thereby avoiding total dependency upon the clinical measurements. It has been termed as optical biopsy as it is performed using the infrared light based system before the surgical biopsy to assess the abnormal texture extent. We know it is usual for the surgeon to excise the mass in relation to his clinical impression on the extent of mass on table. However, when immediate preoperative OCT based instrumentation is used, it may be an added estimation of the extent of mass. Conversely, the Intraoperative OCT can provide better real time assessment during surgery. However, due to its high cost and non-availability in many centers it may not be accessible for all surgeons. On the other hand, high ultra-resolution OCT is a good alternative with better resolution. The limitations of SD OCT are (1) the limited penetration through the thickened epithelium and pigmented mass (2) Conjunctival lesions are difficult to assess as compared to corneal lesions due to the backscatter from sclera. SD OCT may not be absolutely reflect the extent in conjunctival side of lesions due to the histological difference (underlying thick sclera) as compared to cornea (underlying aqueous which acts as dark contrast). There are no studies utilizing optical biopsy in surgical decision making. Therefore, we believe that preoperative optical biopsy can be an adjunctive tool in the diagnosis of OSSN and could greatly assist the surgeon in the management. Nevertheless, the histopathology is the gold standard for confirmation of surgical clearance and we need further studies with varied population to assess the utility of OCT with greater resolution as optical biopsy.

5. Conflict of Interest

None.

6. Source of Funding

None.

References

- Lee GA, Hirst LW. Ocular surface squamous neoplasia. *Surv Ophthalmol.* 1995;39(6):429–50. doi:10.1016/s0039-6257(05)80054-2.
- Yousef YA, Finger PT. Squamous carcinoma and dysplasia of the conjunctiva and cornea: an analysis of 101 cases. *Ophthalmology.* 2012;119(2):233–40.
- Finger PT, Tran HV, Turbin RE. High-frequency ultrasonographic evaluation of conjunctival intraepithelial neoplasia and squamous cell carcinoma. *Arch Ophthalmol.* 2003;121(2):168–72. doi:10.1001/archophth.121.2.168.
- Tananuvat N, Lertprasertsuk N, Mahanupap P, Noppanakeepong P. Role of impression cytology in diagnosis of ocular surface neoplasia. *Cornea.* 2008;27(3):269–74. doi:10.1097/ICO.0b013e31815b9402.
- Xu Y, Zhou Z, Xu Y, Wang M, Liu F, Qu H, et al. The clinical value of in vivo confocal microscopy for diagnosis of ocular surface squamous neoplasia. *Eye.* 2012;26(6):781–7. doi:10.1038/eye.2012.15.
- Bianciotto C, Shields CL, Guzman JM. Assessment of anterior segment tumors with ultrasound biomicroscopy versus anterior segment optical coherence tomography in 200 cases. *Ophthalmology.* 2011;118(7):1297–302.
- Thomas BJ, Galor A, Nanji AA, Sayyad FE, Wang J, Dubovy SR, et al. Ultra high-resolution anterior segment optical coherence tomography in the diagnosis and management of ocular surface squamous neoplasia. *Ocular Surface.* 2014;12(1):46–58. doi:10.1016/j.jtos.2013.11.001.
- Ong SS, Vora GK, Gupta PK. Anterior Segment Imaging in Ocular Surface Squamous Neoplasia. *J Ophthalmol.* 2016;p. 5435092. doi:10.1155/2016/5435092.
- Singh V, Maurya RP, Pal K, Singh S, Singh VP, Anand K. Ocular surface squamous cell neoplasia: An overview. *IP Int J Ocul Oncol Oculoplast.* 2022;8(1):1–11. doi:10.18231/j.ijoo.2022.001.
- Patel AS, Goshe JM, Srivastava SK, Ehlers JP. Intraoperative Optical Coherence Tomography-Assisted Descemet Membrane Endothelial Keratoplasty in the DISCOVER Study: First 100 Cases. *Am J Ophthalmol.* 2019;210:167–79. doi:10.1016/j.ajo.2019.09.018.
- Chen S, Liu X, Wang N, Wang X, Xiong Q, Bo E. Visualizing Micro-anatomical Structures of the posterior Cornea with Micro-optical. *Sci Rep.* 2017;7(1):10752. doi:10.1038/s41598-017-11380-0.
- Lee HJ, Zhang L, Zhang S, Yi J. Detection of Malignancy in Ocular Surface Lesions by Inverse pectroscopic Optical Coherence Tomography and Two-Photon Autofluorescence. *Transl Vis Sci Technol.* 2019;8(3):16. doi:10.1167/tvst.8.3.16.
- Atallah M, Joag M, Galor A. Role of high resolution optical coherence tomography in diagnosing ocular surface squamous neoplasia with coexisting ocular surface diseases. *Ocul Surf.* 2017;15(4):688–95.
- Conway RM, Graue GF, Pelayes D, Pe'er J, Wilson MW, Wittekind CW, et al. Conjunctival carcinoma: Part XV. New York: Springer; 2017. p. 787–93.
- Tabin G, Levin S, Snibson G, Loughnan M, Taylor H. Late recurrences and the necessity for long-term follow-up in corneal and conjunctival intraepithelial neoplasia. *Ophthalmology.* 1997;104(3):485–92. doi:10.1016/s0161-6420(97)30287-5.
- Karp CL, Mercado C, Venkateswaran N, Ruggeri M, Anat G, Garcia A, et al. Use of High-Resolution Optical Coherence Tomography in the Surgical Management of Ocular Surface Squamous Neoplasia: A Pilot Study. *Am J Ophthalmol.* 2019;19:17–31. doi:10.1016/j.ajo.2019.05.017.
- Nanji AA, Sayyad FE, Galor A, Dubovy S, Karp CL. High-Resolution Optical Coherence Tomography as an Adjunctive Tool in the Diagnosis of Corneal and Conjunctival Pathology. *Ocul Surf.* 2015;13(3):226–35.
- Singh S, Mittal R, Ghosh A, Tripathy D, Rath S. High Resolution Anterior Segment Optical Coherence Tomography in Intraepithelial Versus Invasive Ocular Surface Squamous Neoplasia. *Cornea.* 2018;37(10):1292–8.

Author biography

Dhivya Ashok Kumar, Senior Consultant

Amar Agarwal, Chairman and Director

Cite this article: Kumar DA, Agarwal A. Optical biopsy – Optical coherence tomography guided excision of ocular surface squamous neoplasia. *IP Int J Ocul Oncol Oculoplasty* 2022;8(4):241–246.