

Content available at: <https://www.ipinnovative.com/open-access-journals>

IP International Journal of Ocular Oncology and Oculoplasty

Journal homepage: <https://ijooo.org/>

## Case Report

# Living parasite in the eyelid

Syed Mehbub Ul Kadir<sup>1,\*</sup>, Sharmin Ahmed<sup>1</sup>, Golam Haider<sup>1</sup>, Md. Ismail Hossain<sup>2</sup>,  
Tanjila Hossain<sup>3</sup>, Narayon Chandra Bhowmik<sup>4</sup>

<sup>1</sup>Bangladesh Eye Hospital and Institute, Dhaka, Bangladesh

<sup>2</sup>Dept. of Ophthalmology, Cox's Bazar Medical College and Hospital, Cox's Bazar, Bangladesh

<sup>3</sup>Dept. of Ophthalmology, Sir Sallimullah Medical College and Mitford Hospital, Dhaka, Bangladesh

<sup>4</sup>Dept. of Ophthalmology, Ibrahim Medical College and BIRDEM Hospital, Dhaka, Bangladesh



## ARTICLE INFO

### Article history:

Received 25-09-2022

Accepted 10-10-2022

Available online 08-11-2022

### Keywords:

Parasite

Cystic

Eyelid

Loa Loa

## ABSTRACT

**Purpose:** To report a rare case of living parasite in the eyelid.

**Materials and Methods:** This case report was done in a tertiary care eye hospital in Bangladesh. We evaluated the patient thoroughly. CT scan of the orbit and histopathology were helped to diagnose the case. Per operative video recording, preoperative and postoperative photograph was documented properly.

**Case Report:** A young boy presented with gradual swelling in the right upper eyelid. Clinically a firm mass was found in the right upper eyelid. CT Scan of the orbit revealed a cystic lesion in the eyelid. A live worm was extracted from the right upper eyelid.

**Conclusion:** Parasitic lesion may be occurred in the eyelid. Ophthalmologist should be aware of the atypical presentation of the eyelid.

This is an Open Access (OA) journal, and articles are distributed under the terms of the [Creative Commons Attribution-NonCommercial-ShareAlike 4.0 License](https://creativecommons.org/licenses/by-nc-sa/4.0/), which allows others to remix, tweak, and build upon the work non-commercially, as long as appropriate credit is given and the new creations are licensed under the identical terms.

For reprints contact: [reprint@ipinnovative.com](mailto:reprint@ipinnovative.com)

## 1. Introduction

Ocular parasitic infections are significant worldwide due to increased morbidity rate, if not treated on time, and it may lead to visual loss. An increasing number of sub conjunctival Loa loa cases are reported from non-endemic areas are due to increased travel and migration.<sup>1</sup> High index of clinical suspicion is required to establish the diagnosis of eyelid and adnexal parasitic infection. Occasionally the adult parasite is found in the eyelid subcutaneous tissue space and subconjunctival area of humans. Eyelid parasitic lesion often presented as like as preseptal cellulitis or diffuse or nodular swelling of the eyelid.<sup>2</sup> Subconjunctival parasite may be found in young adult with a history of swelling, redness and foreign body sensation in the conjunctiva, and mimic as subconjunctival granulomatous

lesion. Often parasite is obviously seen on slit lamp examination.<sup>3</sup> The management depends on the causative parasite, mostly require surgical removal and antiparasitic medication may be needed in some cases.<sup>1</sup> Surgery is the treatment of choice for eyelid and subconjunctival parasitic lesion.<sup>2,3</sup> The first line anti-parasitic medication like diethylcarbamazine (DEC) to kill both microfilaria and macrofilaria,<sup>4,5</sup> and the second line treatment include albendazole or ivermectin, both have limited efficacy on adult worms.<sup>6</sup> Oral steroid may be used in combination with anti-parasitic drug to reduce inflammation and allergic reaction to parasite and adverse effects of anti-parasitic medication.<sup>1,3</sup> Here, we attempt to report a rare case of atypical presentation of living parasite in the eyelid.

\* Corresponding author.

E-mail address: [mehbubkadir@gmail.com](mailto:mehbubkadir@gmail.com) (S. M. U. Kadir).

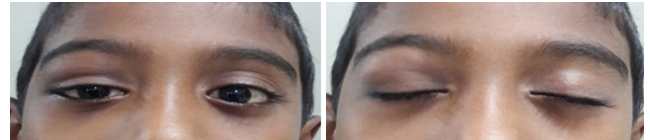## 2. Materials and Methods

This case was treated at the Department of Oculoplastic service in National Institute of Ophthalmology and Hospital, Dhaka, Bangladesh from May 2018 to April 2019. We evaluated the patient thoroughly. Meticulous ophthalmic and systemic evaluation was performed after taken a clinical history of the patient. CT scan of the orbit was helped to take decision for exploring the eyelid surgically. Parasitological and histopathological analysis were helped to diagnose the case. Per operative video recording, preoperative and postoperative photograph was documented properly. We followed up the patient up to one year at 3 weekly for 3 months, then 3 monthly for 9 months.

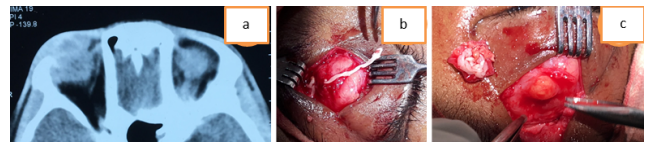
## 3. Case Report

A 8-year-old-boy presented swelling of the right upper eyelid for the last one year. Parents of the boy also gave a history of occasional pain and redness of his right eyelid which was relieved by oral anti-inflammatory medications (NSAIDs) and oral antihistamine for 3-5 days. On examination, the skin overlying of the swelling area of the eyelid was intact and showed no blister or other skin lesions. We found a non tender lesion underneath right upper eyelid skin that was 1 cm x 1cm in diameter (Figure 1). Vision was 6/6 in both eyes. Anterior and posterior segment evaluation revealed normal study. CT Scan of the orbit revealed a heterogenous ill-defined lesion within a central hypodense lesion in the right upper eyelid (Figure 2a) which is suggestive of chronic inflammatory lesion with a cystic change. So, our radiological diagnosis was a cystic lesion with thicken hazy irregular outline. Our case, the unusual location, misleading history, and atypical appearance precluded us from considering cysticercosis. We advised for the exploration and excision biopsy of the lesion under general anaesthesia. After given an eyelid crease incision, a thick wall cystic lesion was identified under the orbicularis oculi muscle in the mid-preseptal area of the right upper eyelid, and the lesion was attached to the supra-orbital margin. An iatrogenic injury to the cystic wall was occurred. Then a live worm was coming out from the injured cystic cavity. One of the crucial steps of the surgery was to remove the whole parasite and cystic wall completely. The whole cyst was opened, and a live worm was revealed and extracted from the right upper eyelid per operatively (Figure 2b). The remaining cystic wall with the cystic mass was excised (Figure 2c) and sent for histopathological analysis. The operating area was cleaned with 5% povidone iodine followed by normal saline, then the wound was closed by interrupted 6-0 Vicryl suture in layers. The measured live worm was about 10 cm in length (Figure 3a). The live worm was kept in a normal saline filled container (Figure 3b) and sent for parasitological analysis. The parasitological analysis


revealed the parasite infestation compatible with adult *Loa loa* worm, and the histopathological examination reported also for parasitic infestation (Figure 3c). Recurrence and any adverse effects were not reported in the one year follow up period.



**Fig. 1:** Showing a subcutaneous lesion in the right upper eyelid.



**Fig. 2:** **a:** Axial image of CT scan of the orbit showing a ill-defined heterogenous lesion within a hypodense area in the right upper eyelid. **b:** Extracting the live worm from the cystic cavity, and **c:** Showing the excised cystic wall away from the operating area of the right upper eyelid.



**Fig. 3:** **a:** Showing the extracted live worm which is about 10 cm in length; **b:** Showing two normal saline filled container. One containing the live worm for parasitological evaluation and other containing the excised cystic wall for histopathological analysis; **c:** showing histopathological microphotograph after wet film preparation and H&E stain which is compatible with the *Loa loa*.

## 4. Discussion

Loiasis is a filarial disease caused by the nematode *Loa loa* which is an undertreated infectious disease and restricted in Central and Western Africa.<sup>3-5</sup> It is transmitted to humans by the bites of mango flies or deerflies (*Chrysops silica* and *Chrysops dimidiata*), which introduce larvae into the subcutaneous tissues of human. *Macrofilaria* migrate in the subcutaneous and deep connective tissues, and the microfilariae are found in the blood. Development into adult worms within human subcutaneous tissues takes over six to twelve months, and they can survive up to seventeen years. The adult worm is about 30-70 millimeters in length and 0.3-0.5 mm in diameter.<sup>4,5,7</sup> The literature reported that adult worms may survive in human tissue for up to 21 years.<sup>8,9</sup> The first clinical presentation may appear as soon

as 5 months of post infection.<sup>9</sup> This case report notes a novel clinical presentation of Loa loa (Loiasis) of the eyelid in Bangladesh.

First published article on extracted Loa loa from a human eye was in 1770 (Grove 1990). In India, first published case report on periocular manifestation of Loa loa in 2011 according to PubMed search.<sup>10</sup> Literature reported two cases of Loa loa macrofilaria diagnosed in United states.<sup>4</sup> Total eight similar cases are reported in the literatures.<sup>10,11</sup> This case represents the second case of periocular subcutaneous Loa loa macrofilaria of the eyelid in Bangladesh. Clinical diagnosis is important and diagnostic criteria would include exposure to an endemic area, Calabar swelling, and subconjunctival macrofilaria.

Adult Loa loa migrate actively throughout the subcutaneous tissue of the body. It is known as African eye worm because it may frequently occur in eyelid Calabar swelling and subconjunctiva and causes irritating when crossing the conjunctiva. Calabar swellings, is a nontender swelling can occur anywhere, but are more frequently found on the forearms.<sup>12,13</sup>

The best diagnostic technique is PCR of the repeat-3 region of the gene encoding a 15-kDa protein for the detection of species-specific sequences.<sup>7,13</sup> Loiasis can be effectively managed by complete surgical removal of the worms including the cystic wall. The standard dose (150 µg/kg) of Ivermectin can be used in the cases of microfilaria.<sup>12</sup> Our patient did not exhibit microfilaremia or other side effects on follow up times. Though rarely diagnosed in developed nations, practitioners in all medical specialties must be aware of the disease which may present in immigrants and travelers up to 21 years after their initial infection. Loa loa infection should be considered in the differential diagnosis of eyelid or conjunctival swelling for patients with eosinophilia and Calabar swelling especially those who travelling from Africa.

## 5. Conclusion

Ophthalmologists should be aware of atypical parasitic presentation of the eyelid and adnexa coupled with high index of clinical suspicion, may help in early management.

## 6. Conflict of Interest

The authors declare no Conflict interests regarding the publication of this article

## 7. Source of Funding

There was no financial support in terms of grants or funds for this study from any source.

## References

1. Malla N, Goyal K. Ocular Parasitic Infections – An Overview. In: Rumelt S, editor. *Advances in Common Eye Infections* [Internet]. London: IntechOpen; 2016. Available from: <https://www.intechopen.com/chapters/51510>. doi:10.5772/64137.
2. Kadir S, Jahan F, Quadir A, Rahman MT. Filariasis of the eyelid subcutaneous manifestation in Bangladesh. *Indian J Clin Exp Ophthalmol*. 2015;1(3):184–6. doi:10.5958/2395-1451.2015.00012.
3. Rashid R, Sultana S, Kadir SMU, Haque N, Afzal F. Subconjunctival Loa loa: A case report. *IP Int J Ocul Oncol Oculoplasty*. 2021;7(3):316–9.
4. Rodriguez L, White JM, Richards NQ, You AX, Couser NL. An Adult Loa loa Worm in the Upper Eyelid: An Atypical Presentation of Loiasis in the United States. *Case Rep Ophthalmol Med*. 2021;2021:6630875. doi:10.1155/2021/6630875.
5. Kamgno J, Klion A. Loiasis. In: Endy T, Solomon T, Hill D, Ryan ET, Aronson N, editors. *Hunter's Tropical Medicine and Emerging Infectious Disease*. Philadelphia, USA: Elsevier; 2019. p. 859–63.
6. Metzger WG, Mordmüller B. Loa loa—does it deserve to be neglected? *Lancet Infect Dis*. 2014;14(4):353–7. doi:10.1016/S1473-3099(13)70263-9.
7. Boussinesq M, Gardon J. Prevalences of Loa loa microfilaraemia throughout the area endemic for the infection. *Ann Trop Med Parasitol*. 1997;91(6):573–89. doi:10.1080/00034989760671.
8. Richardson ET, Luo R, Fink D, Nutman TB, Geisse JK, Barry M, et al. Transient facial swellings in a patient with a remote African travel history. *J Travel Med*. 2012;19(3):183–5. doi:10.1111/j.1708-8305.2012.00612.x.
9. Churchill DR, Morris C, Fakoya A, Wright SG, Davidson RN. Clinical and laboratory features of patients with loiasis (Loa loa filariasis) in the U.K. *J Infect*. 1996;33(2):103–9. doi:10.1016/s0163-4453(96)93005-4.
10. Bhedasgaonkar S, Baile RB, Nadkarni S, Jakkula G, Gogri P. Loa loa macrofilaria in the eyelid: case report of the first periocular subcutaneous manifestation in India. *J Parasit Dis*. 2011;35(2):230–1. doi:10.1007/s12639-011-0043-6.
11. Chhabra RC, Bhat S, Shukla SM. Ocular loiasis in a Zambian woman. *East Afr Med J*. 1989;66(7):491–4.
12. Cho HY, Lee YJ, Shin SY, Song HO, Ahn MH, Ryu JS, et al. Subconjunctival Loa loa with Calabar swelling. *J Korean Med Sci*. 2008;23(4):731–3.
13. Toure FS, Deloron P, Egwang TG, Wahl G. Relation entre intensite de la transmission de la filaire Loa loa et prevalence des infections. *Med Trop (Mars)*. 1999;59(3):249–52.

## Author biography

**Syeed Mehbub Ul Kadir**, Assistant Professor

**Sharmin Ahmed**, Consultant

**Golam Haider**, Professor

**Md. Ismail Hossain**, Assistant Professor

**Tanjila Hossain**, Assistant Professor

**Narayan Chandra Bhowmik**, Assistant Professor

**Cite this article:** Kadir SMU, Ahmed S, Haider G, Hossain MI, Hossain T, Bhowmik NC. Living parasite in the eyelid. *IP Int J Ocul Oncol Oculoplasty* 2022;8(3):226–228.