

## Diagnostic value of three dimensional CT reconstruction in various orbital disorders

Rajendra P. Maurya<sup>1,\*</sup>, Virendra P. Singh<sup>2</sup>, Mahendra K. Singh<sup>3</sup>, Shrinkhal<sup>4</sup>, Prithvi R. Sen<sup>5</sup>, Ashish Verma<sup>6</sup>, Pradeep Jain<sup>7</sup>

<sup>1</sup>Assistant Professor, <sup>2,3</sup>Professor, <sup>4</sup>Junior Resident, Department of Ophthalmology, <sup>6</sup>Associate Professor, Department of Radiodiagnosis & Imaging, <sup>7</sup>Professor, Department of Plastic Surgery, <sup>5</sup>Chief Medical Officer, SS Hospital, Institute of Medical Sciences, Banaras Hindu University, Varanasi

**\*Corresponding Author:**

Email: mauryarp\_bhu@yahoo.com

---

### Abstract

**Background:** The diagnosis of orbital disease is an extremely challenging task. Technological advancement in computer software algorithms have allowed three dimensional (3D) reconstruction of complex orbital and craniofacial skeleton from 2D images.

This study was undertaken to assess the diagnostic value of three-dimensional computed tomography (3D CT) in evaluating various orbital disorders.

**Materials and Methods:** Over a five year period, 110 patients (69 males, 41 females) suffering from various orbital disorders were studied between January 2010 to February 2015 at our teaching hospital. After complete clinical examination, each patient was subjected to Multislice (64 slices) 2D CT. Post processing of the volume data so acquired was performed on an off-line workstation to generate multi-planner reconstructions along with maximum intensity projections (MIP) and volume rendered (VR) images wherever essential.

**Result:** Out of 110 patients, 61.82% were male and 38.18% females, ranging in age from 3 months to 79 years. 60 (54.5%) had orbital trauma, 42 (38.18%) had orbital tumor (mass lesion) while rest (7.32%) were suffering from congenital orbital/craniofacial abnormalities. Among the trauma cases, 12 (10.9%) had isolated orbital trauma, 28 cases (25.45%) had maxillofacial trauma and the rest 20 cases (18.18%) had cranio-orbital trauma. Among the neoplastic disorders, 22.73% had malignant lesions and rest 15.45% had benign lesions, out of them 4.55% were vascular lesion and 10.90% were developmental/ congenital mass. 7.27% had orbital bone dysostosis with craniofacial malformations.

In all 110 patients, the 3D CT reformatted images confirmed the findings of conventional CT and radiographs and provided additional information regarding size, shape and extension of mass lesion or any fracture or bony erosion. It also provided depth perception and volumetric assessment.

**Conclusion:** The present day multi-detector row CT scan offers the unique opportunity for evaluation of pathologies in multiple planes. The volume data generated is isotropic in nature and can generate images in any plane without anatomical distortion. The capability is of specific use in complex regions like orbit 3D where the reformatted projections not only remain a valuable problem solving tool but has become an essential pre-requisite for evidence based management. Further the 3D volume images remain of prime importance for a clinician to adequately counsel his patients and for post-operative evaluation of surgical results.

**Key Words:** Computed tomography, craniofacial abnormalities, craniofacial trauma, three- dimensional CT, two- dimensional CT, orbital fracture, orbital tumor, spiral CT.

---

### Introduction

The sophisticated and complex nature of orbital anatomy, presence of tiny and vital structures in relationship with surrounding facial bone and calvarium make the diagnosis of orbital diseases extremely challenging[1,2]. Often misdiagnosis and incomplete treatment of orbital disorders leads to recurrence, functional and cosmetic sequelae[3]. Management of orbital tumor or space occupying lesions, especially in the region of orbital apex are complex and technically challenging as it may be associated with ocular morbidity and mortality. Appropriate surgical management of such orbital lesions require accurate measurement of dimension, extent and volume of tumor and its invasion to the bony orbit and surrounding structures[4-6].

Orbital injuries are often seen in persons with polytrauma/ major trauma after road traffic accident, physical assault, fall from height and industrial or

domestic accidents. These orbital injuries are often severe and complex in nature involving skull and face[2,3,7]. Appropriate management of acute orbital and craniofacial trauma (CFT) requires intense and immediate clinical decision, which is dependent on radiological depiction of injury. Conventional 2D radiograph play an important role but has diagnostic limitation in acute CFT cases due to superimposition of surrounding bony structures, impaired visualization of underlying fine fractures due to periorbital edema, ecchymosis and hemorrhage[3,7,8,9].

Computerized tomography (CT) is a simple, safe and non-invasive diagnostic tool performed on an OPD basis. The information through CT scan can be enhanced by several special techniques like contrast enhancement, narrow density, window measurement, three dimensional CT and image reversal.

Several medical literatures establish that Resolution-CT is the imaging modality of choice in

assessing the facial and bony orbit in case of orbital tumor, craniofacial trauma and congenital anomalies[10-16]. 3D reformatted images add a new dimension to the evaluation of orbito-craniofacial abnormalities[13]. With the advent of special software, 3D CT images can be reconstructed from conventional 2D CT in axial and coronal planes which is superior to 2D images. It provides sharper bony image from the entire angle and in all the three planes at a time. 3D CT reconstruction is possible only with multislice/ spiral CT scanner. In this study, we report our experience of 3D CT evaluation in orbital trauma, tumor and congenital anomalies.

### Materials and Methods

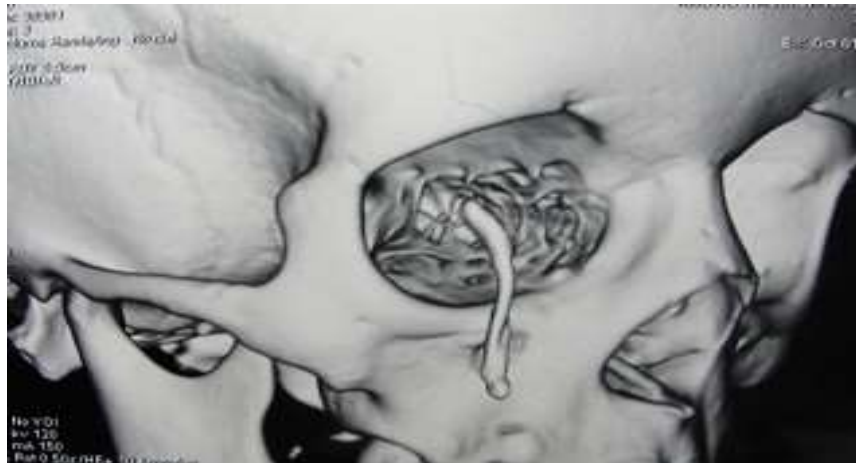A retrospective review of the CT scan data of all patients treated for various orbital diseases at Department of Ophthalmology and Emergency OPD, S.S. Hospital, Institute of Medical Sciences, Banaras Hindu University, Varanasi from January 2010 to December 2015, was conducted. 110 patients were identified with orbito-facial trauma, neoplastic and developmental craniofacial anomalies. All patients had undergone orbital CT scans on a fourth generation 64-multidetector row CT scanner (Light speed VCT machine, General electric health care). The volume data was acquired initially in the transverse plane from the vertex to the hyoid bone, this extended coverage was justified as varying pathologies had associations and extensions in the loco-regional field. A pitch<1 was used with a gantry rotation time of 1 second, kVp of 120 and mA of 200. In all cases except those with trauma intravenous iodinated contrast media was injected via the medial antecubital vein using a pressure injector. A total of 100-150 ml contrast media was injected according to the weight of the patient at a rate of 3-5 ml/sec followed by a saline chase of 20 milliliters. Scanning was done within 10 seconds of intravenous contrast media injection. Online image reconstruction in axial plane was pre-programmed using standard filter for soft tissue of head & neck and for bone. This generated images with slice thickness of 1-mm, with 0.5-mm reconstruction interval in 8 slices, a reconstruction matrix of 512 X 512 matrix was achieved with FOV (field of view) 18 cm. Further data processing was done on an off-line workstation (ADW

4.0, General electric medical systems, Milwaukee, Wisconsin, USA) to generate multi-planner reconstructions in standard anatomical planes and intermediary oblique planes. Maximum intensity projections were generated using an iodine threshold in cases of orbital tumors and a bone threshold in cases of subtle injury. Volume rendered (VR) 3D projections were also generated in all cases using a soft tissue threshold. However dynamic thresholding was done in all VR images to demonstrate the pathology adequately with alterations in transparency settings to visualize the orbital apex, skull base and pterygo-palatine region.

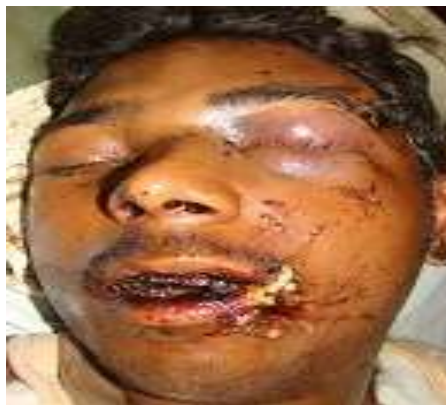### Results

Present retrospective study included 110 patients of orbital diseases, with age ranging from 3 months to 79 years, with mean age of 31.3 years. The predominant age group being 18-50 years. 69 (61.82%) study subjects were male and rest 42 (38.18%) were females with Male: Female ratio being 34:21. The working clinical diagnosis facilitating CT evaluation for 110 patients with 3D CT images are presented in Table 1. Most common clinical diagnosis was orbital trauma (54.55%) followed by orbital neoplasm (38.18%) and congenital bony anomalies (7.27%).

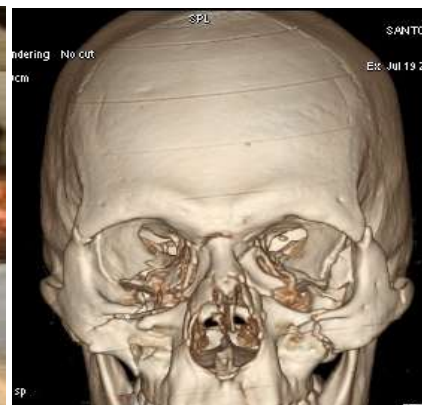
**Orbital Trauma:** Among the orbital trauma cases, 2.73% had retained foreign body [Fig. 1] and only 12 subjects (10.90%) had isolated orbital fracture, rest had associated multiple bony injuries. 28 (25.45%) had orbito-maxillofacial trauma (Fig. 2) and 20 (18.18%) had cranio-orbital (Fig. 3 & 4) or cranio-orbito-facial trauma (Fig. 5-7). 32 (29.10%) had bilateral orbital fracture (Fig. 6-8). Majority of the patients (38.18%) had acute orbital trauma where detailed clinical examination was not possible due to soft tissue swelling and hemorrhage. On CT evaluation 19.10% cases show non-displaced fracture while majority of patients (80.90%) had severely displaced fracture (Fig. 6-8). In our study on 3D CT image evaluation, clinical and conventional radiography findings were confirmed in all cases and 86 other fractures were also detected. Amongst the additional fractures, 38 fractures were related to orbital complex and the rest were related to zygomatico-maxillary complex.



**Fig. 1:** Oblique frontal 3D volume rendered projection with bone thresholding shows a retained intra-orbital foreign body (a fish-hook) projecting out through the orbit, extending into the lamina papyracea. The foreign body has a threshold equal to bone indicating similar density, hence the propensity to cause trauma and difficulty while removal

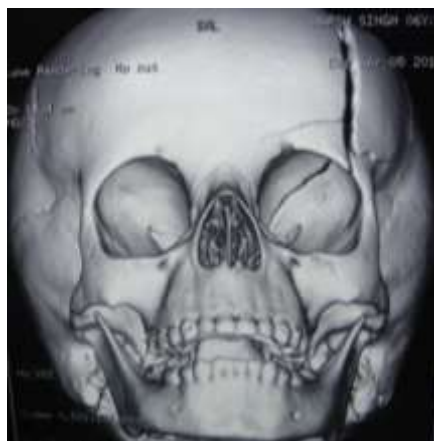

**Fig. 2 a**

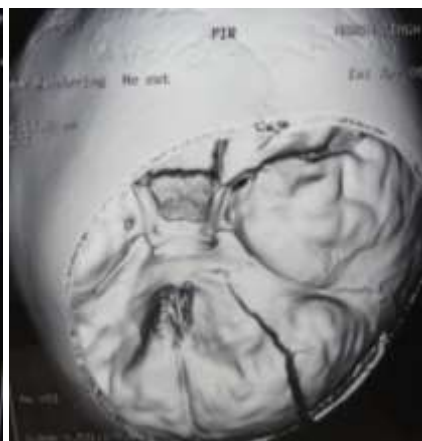


**Fig. 2 b**

**Fig. 2 (a & b):** A case of road traffic accident, frontal 3D volume rendered projection with bone thresholding showing a type II Le-forte fracture. The comminuted fracture line is extending across bilateral maxillary, zygomatic and ethmoidal bones involving the floor, lateral wall & medial wall of orbit. Such fractures remain difficult to map accurately in cross sectional images



**Fig. 3 a**



**Fig. 3 b**

**Fig. 3 (a & b):** A child with history of fall from height, frontal 3D volume rendered projection with bone thresholding showing a linear, displaced fracture of left frontal bone involving roof of left orbit. Volume

sculpting of cranial vault shows extension of fracture line up to the fronto-sphenoid suture, a feature not seen in non-sculpted images

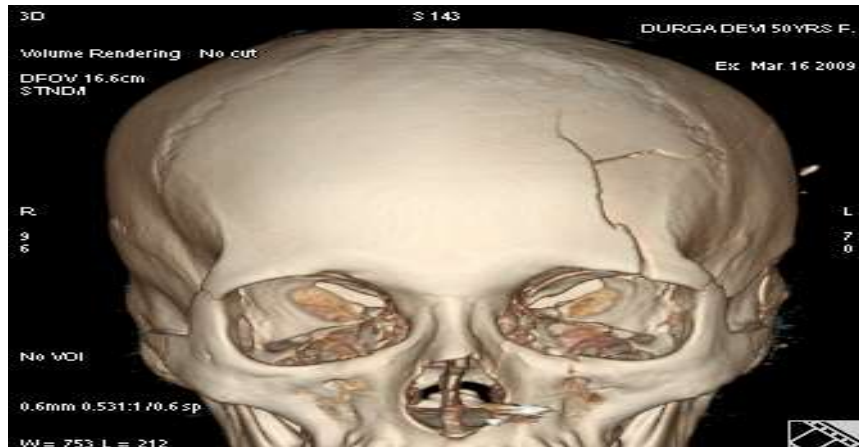

Fig. 4: A case of road traffic accident, frontal 3D volume rendered projection with bone thresholding showing an un-displaced fracture of left frontal bone involving superior orbital rim and roof of the left orbit

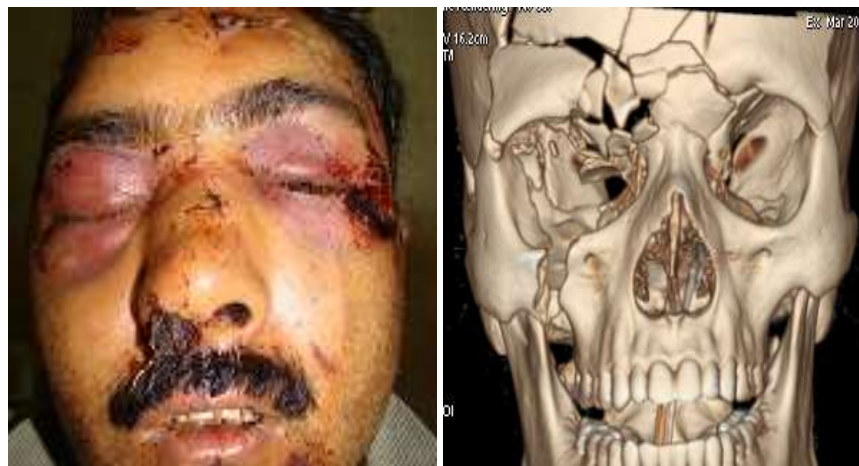
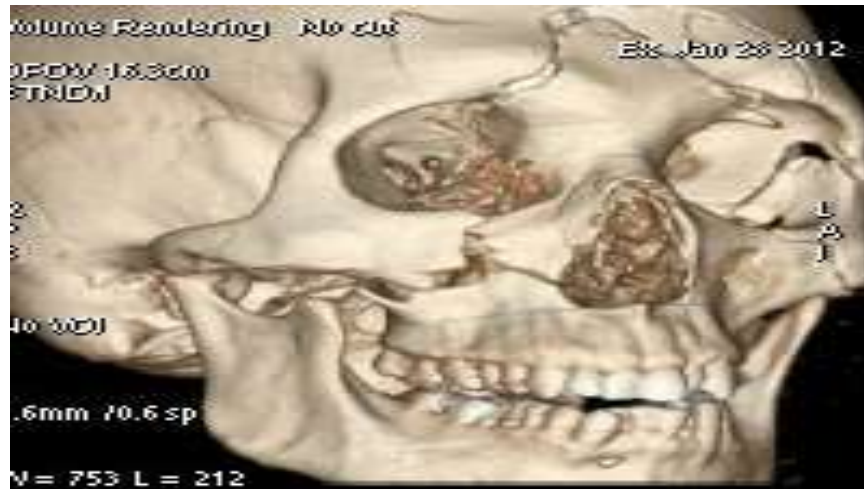
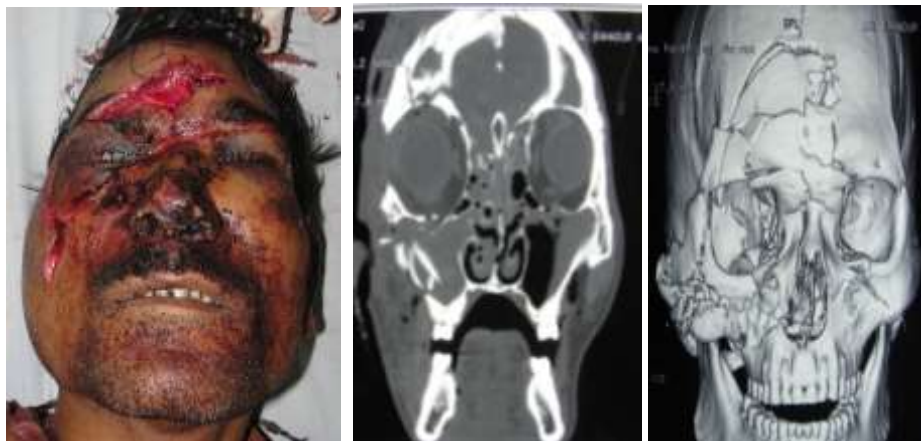
Fig. 5 a

Fig. 5 b

Fig. 5 (a, b): A case of road traffic accident, frontal 3D volume rendered projection with bone thresholding showing a complex comminuted fracture of bilateral Fronto-perital bones extending to involve the right maxillary, zygomatic and ethmoid bones. Apart from multiple displaced intra-orbital fragments seen in the axial image the displacement of mid-facial fragment in three dimensions is better seen on 3D image. The fracture line is involving the floor, lateral wall & medial wall of orbits. Such fractures remain difficult to map accurately in cross sectional images



**Fig. 6:** A case of road traffic accident, frontal 3D volume rendered projection with bone thresholding showing a complex comminuted fracture of bilateral Frontal bones extending to involve the right maxillary, zygomatic and ethmoid bones. Though the mid-facial segment remains un-displaced there is a facio-palatal dysjunction noted qualifying for a Le-forte type III injury. Complex volume sculpting proved the point in this case (not shown here) and remains most important for the purpose



**Fig. 7 a**

**Fig. 7 b**

**Fig. 7 c**

**Fig. 7 (a, b & c):** A case of physical assault, frontal 3D volume rendered projection with bone thresholding showing a complex comminuted fracture of bilateral Frontal bones extending to involve the maxillary, zygomatic, nasal and ethmoid bones. Extensive haemosinus seen in coronal image could not be seen in 3D image however the magnitude of injury is best seen on volume rendered images



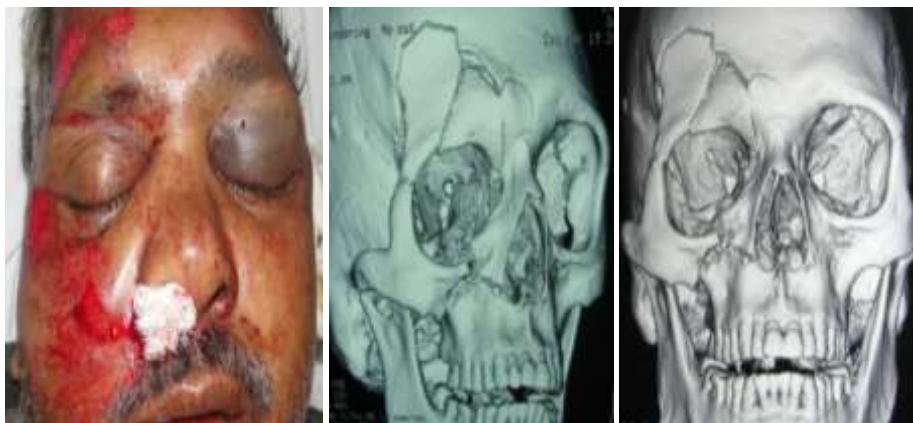

Fig. 8 a

Fig. 8 b

Fig. 8 c

**Fig. 8 (a, b & c):** A case of fall from height, oblique and direct frontal 3D volume rendered projections with bone thresholding showing a complex comminuted fracture of right frontal bone extending to involve the maxillary, zygomatic, nasal and ethmoid bones. The right floor and superior orbital rim and lateral wall of left orbit are involved with inferolateral displacement of mid-facial segment

**ORBITAL NEOPLASM:** Amongst orbital neoplastic disorders (38.18%), 22.73% were malignant tumor [Fig. 9] and the rest 15.45% were benign lesions [Fig. 10]. Out of them 4.55% were haemangioma and lymphangioma [Fig. 10, 11] and 10.90% were dermoid cyst and mucocoele [Fig. 12]. The commonest malignant lesions were rhabdomyosarcoma, lacrimal gland tumor and orbital extension of periocular carcinomas [Fig. 13, 14]. Ocular carcinoma was complicated by orbital myiasis in 2 cases [Fig. 9]. 3D CT reformatted images clearly display the relationship between mass lesion and surrounding bony structures like bony erosion/ destruction and compressive orbital

deformation such as bony thinning/ scalloping or fossa formation.

**CONGENITAL MALFORMATIONS:** Eight patients (7.27%) with congenital bony malformations were examined by us. 3 patient had Crouzen syndrome characterized by craniosynostosis, maxillary hypoplasia, shallow orbit and proptosis. One patient had Treacher Collins syndrome and in 4 patients simple microphthalmic/ anophthalmic socket (Fig. 15) was identified. 3D CT images provided information on depth perception, bony contour, orbital volume and extent of abnormality in all cases.

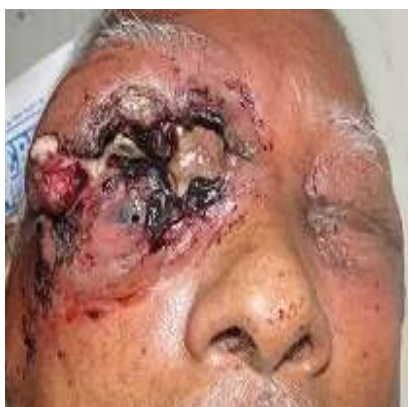

Fig. 9 a

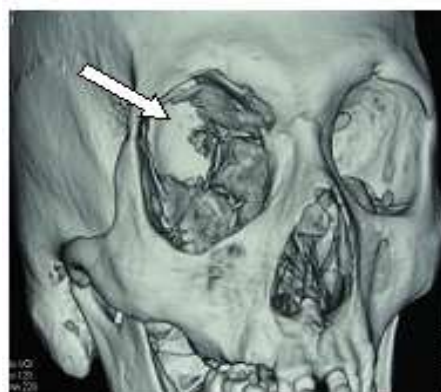

Fig. 9 b

**Fig. 9 (a, b):** A case of right orbital soft tissue carcinoma. Oblique and direct frontal 3D volume rendered projections with bone thresholding showing loss of bony landmarks in the right orbit with a large bone destruction (white arrow) at the posterior lateral aspect of orbital cone through which intracranial extension of this mass was seen. Widening of the orbital seam and rim is also seen with erosion of the floor as well. Note the loss of important features like the orbital fissures and optic canal on right side in comparison to left, these features are best seen on 3D volume rendered images

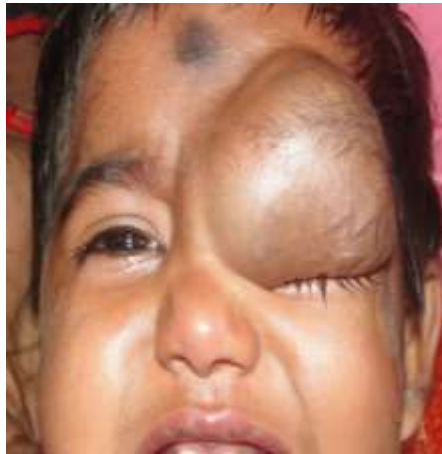

Fig. 10 a

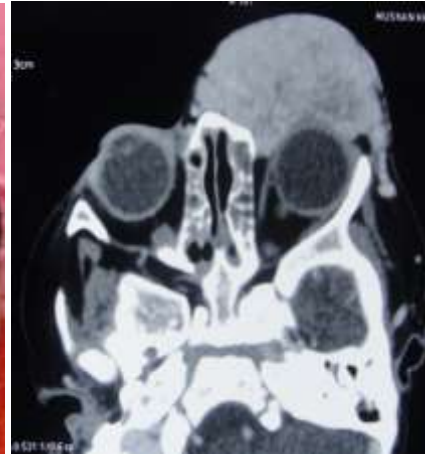

Fig. 10 b

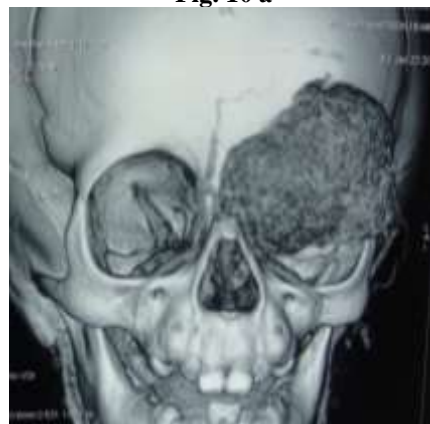

Fig. 10 c

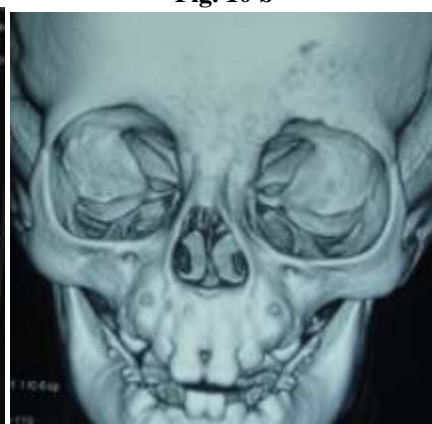

Fig. 10 d

**Fig. 10 (a, b, c & d):** An orbital preseptal lesion in a child proven to be a lacrimal malignancy. Axial post-contrast, oblique frontal 3D volume rendered image with semi-soft tissue threshold and a direct frontal 3D volume rendered projections with bone thresholding are shown. Note the strongly enhancing lesion is exclusively preseptal in location with maintained intra-orbital landmarks. Only the region of lacrimal sac fossa is scalloped and flattened. The encased left supra-orbital artery is faintly seen with compressed and displaced right sided artery

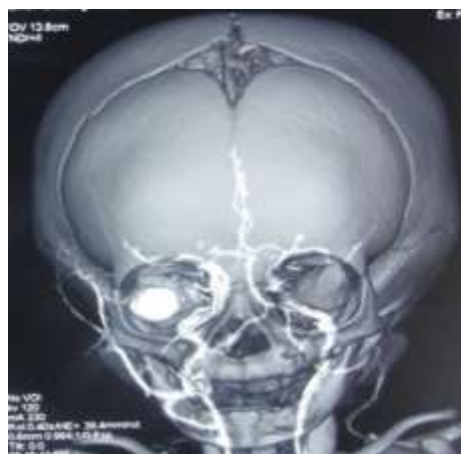

Fig. 11 a

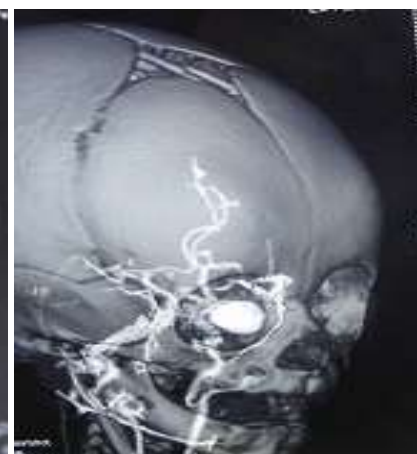

Fig. 11 b

**Fig. 11 (a, b):** Right side low flow congenital vascular malformation in a child. The direct and oblique frontal volume rendered image have been superimposed with CT angiographic 3D-reconstructions in pure arterial and arterio-venous phases respectively, to gives a good single view impression of the pathology and relation to craniofacial bony anatomy. Note the rounded enhancing soft tissue mass near the external aspect of orbit seen to be located in the eyelid on cross-sections. No feeders from internal and external carotid arteries could be

seen in arterial phase but multiple dilated veins extending towards the neck and pterygoid plexus are seen in the venous phase. This confirms the possibility of a haemangioma, the location being well depicted on 3D images and subsequent comparison after chemoradiation

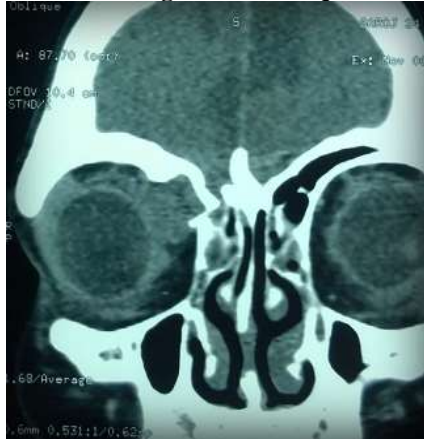

Fig. 12 a

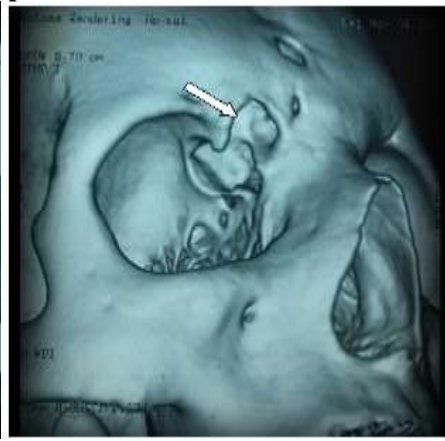

Fig. 12 b

Fig. 12 (a, b): Right frontal mucocoele with fossa formation. An oblique frontal 3D volume rendered projection with bone thresholding and a coronal post-contrast image are shown. Scalloping and eversion of bony margins is better seen on the 3D image with a wide hiatus communicating with the frontal sinus (white arrow). Note the soft tissue mass appears like a malignancy in coronal image but the relatively benign bony features on 3D image suggest otherwise (also confirmed subsequently)

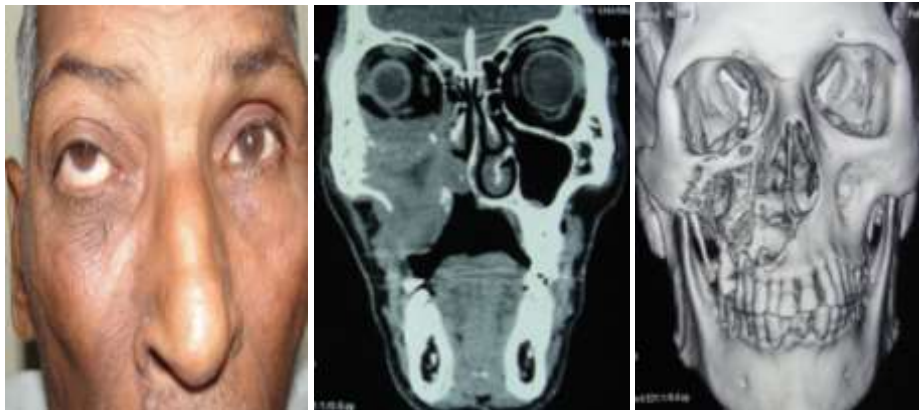

Fig. 13 a

Fig. 13 b

Fig. 13 c

Fig. 13 (a, b & c): A case of right maxillary sinus malignancy with proptosis. Coronal post-contrast and a direct frontal 3D volume rendered projections with bone thresholding are shown. The extra-conal intra-orbital extension with involvement of the right oral and nasal cavities is seen. The 3D image gives a better and single view impression of the extensions especially that of the alveolar process and parapharyngeal space without any intracanal extension, these features are critical for treatment planning



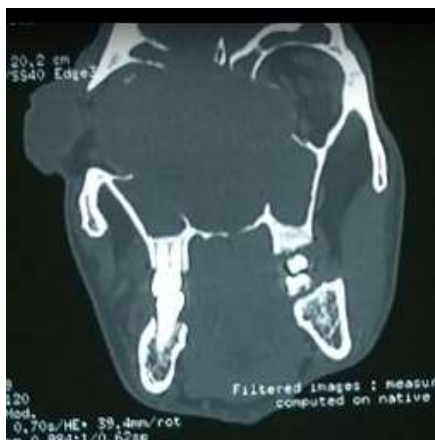

Fig. 14 a

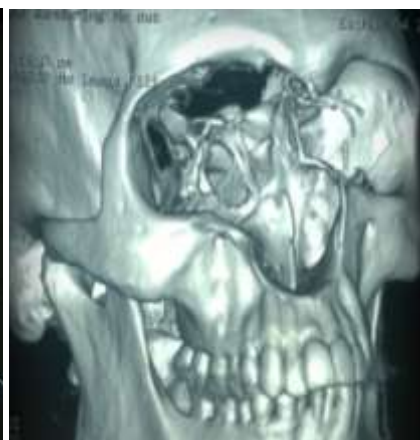

Fig. 14 b

**Fig. 14 (a & b):** Advanced ethmoid sinus malignancy with proptosis. An oblique frontal 3D volume rendered projection with bone thresholding and a coronal post-contrast image are shown. The intra-orbital extensions on both sides with involvement of the nasal cavities is well depicted on the 3D image gives a better and single view impression critical for treatment planning and subsequent comparison after chemoradiation

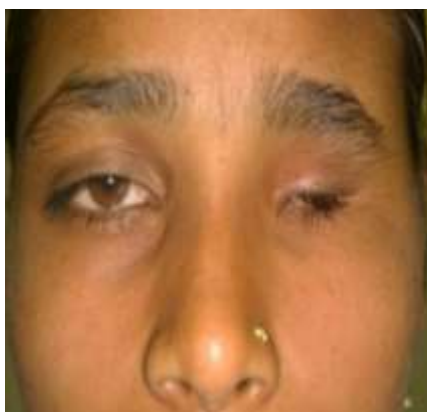

Fig. 15 a

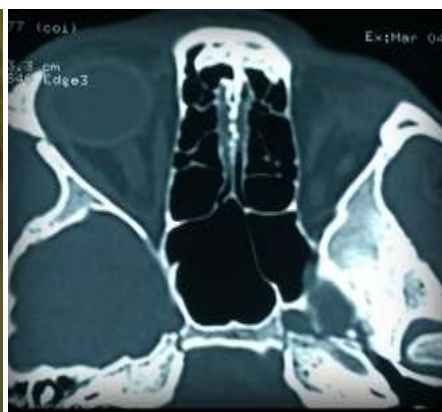

Fig. 15 b

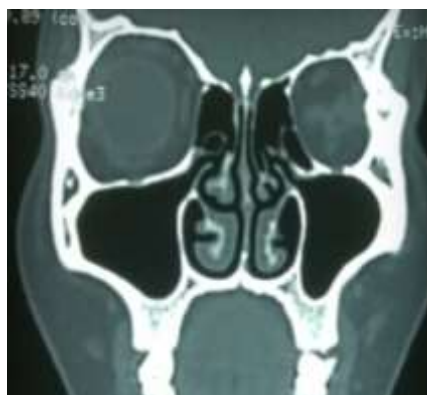

Fig. 15 c

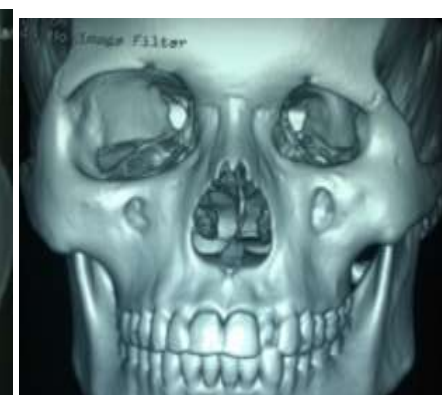

Fig. 15 d

**Fig. 15 (a, b, c & d):** Left side congenital anophthalmic socket in a young female. Axial & coronal bone window images show hypoplasia of left orbit and intraorbital soft tissue structures. The volume rendered image however gives a good single view impression of the pathology, note maintenance of all intraorbital landmarks with relative hypoplasia of each as compared to right confirms the impression. Also compensatory hypertrophy of bone is seen on the left side. Such a depiction would be very useful in a busy outpatient setup and prevent any further workup for acquired micro-ophthalmos

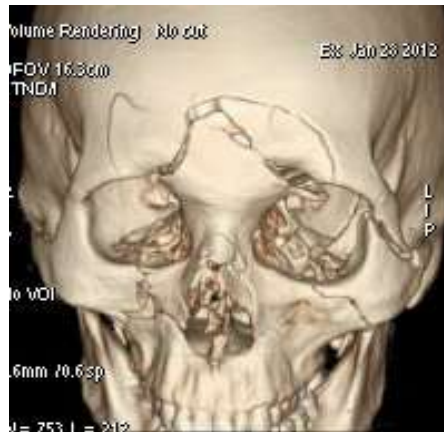

Fig. 16 a

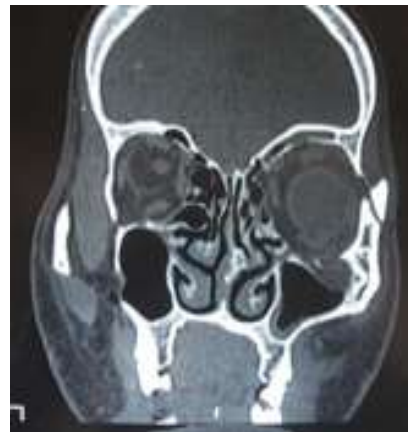

Fig. 16 c

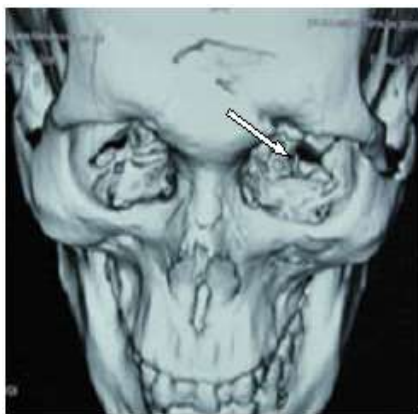

Fig. 16 b

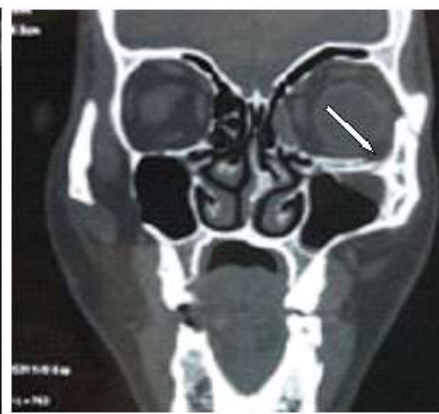

Fig. 16 d

Fig. 16 a, b (Pre-treatment) Fig. 16 c, d (Post-treatment)

Fig. 16 (a, b, c & d): A case of road traffic accident, superior oblique frontal 3D volume rendered projection with bone thresholding showing a complex comminuted fracture of bilateral Frontal bones extending to involve the maxillary, zygomatic, nasal and ethmoid bones give a good impression of the fracture being a Le-forte type III injury. (b) coronal view showing large defect in left floor of orbit with soft tissue herniation. (c & d after iliac bone graft) showing the same appears to be underestimated on coronal cross-sectional reconstructions

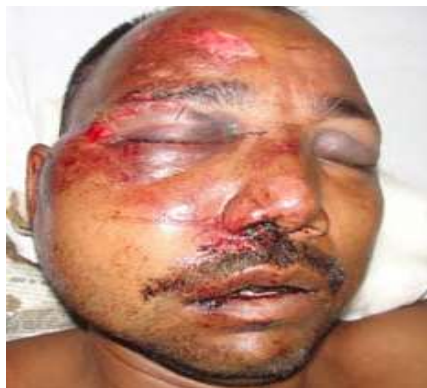

Fig. 17 a (Pre-treatment)

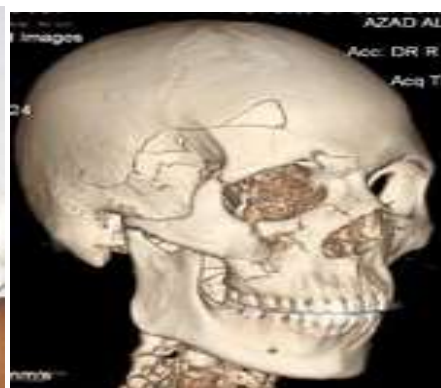

Fig. 17 b (Pre-treatment 3D)

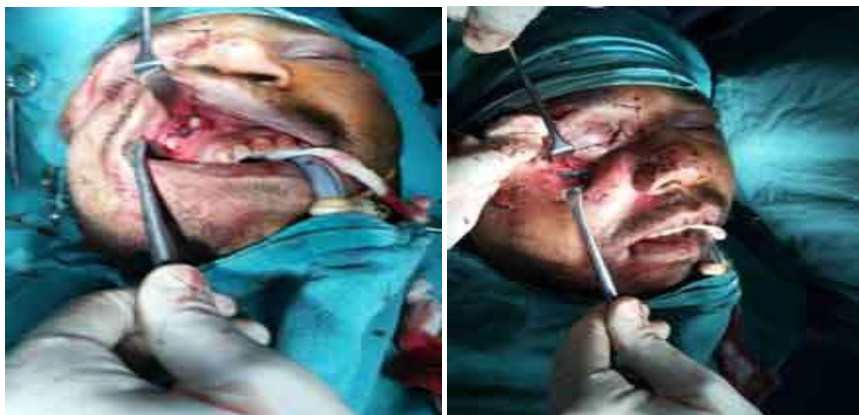

Fig. 17 c (fixation by Titenium miniplate)

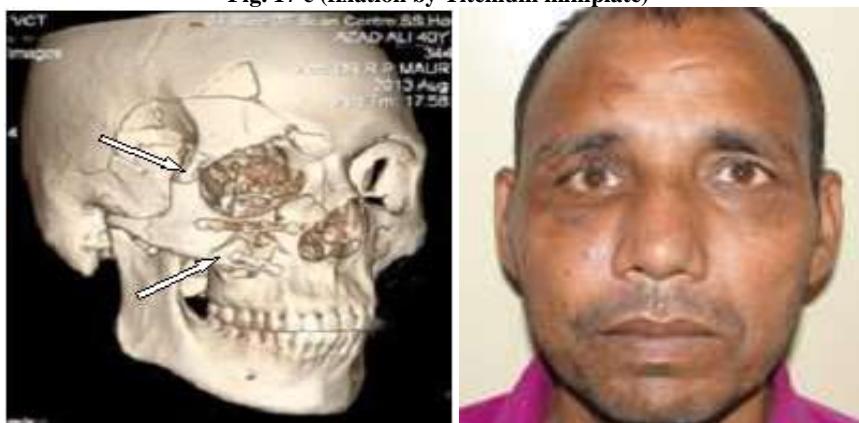

Fig. 17 d (Post-treatment 3D)

Fig. 17 e (Post-treatment)

**Fig. 17:** A case of physical assault showing Proptosis, ecchymosis & facial asymmetry (a). 3D volume rendered oblique projection with bone thresholding. Note the complex comminuted fracture of bilateral frontal bones extending to involve the maxillary, zygomatic, nasal and ethmoid bones. The mid-facial fragment shows an inferolateral displacement with another fragment at the inferior orbital rim being displaced inferiorly (b). Cosmetically adequate facial reconstruction was achieved by a repair by using titanium miniplate fixation (b & c), post-operative result are shown in the 3D whereby exact replacement with fixation of the segments/fragments is noted (white arrow). Such images remain of vital importance in patient counselling as well as for medicolegal purposes

## Discussion

Depth and thickness of structures cannot be measured by conventional radiological techniques because anatomy is depicted in two dimensions[7]. 3D CT has the ability to evaluate bony structural details, soft tissue contours and depth perception[14], it thus helps in evaluation of complex congenital bony anomalies, acute craniofacial trauma, soft tissue malformation and neoplastic disorders[18,19].

The orbit is quite a complex structure. Pyramidal cavities lie on either side of the ethmoidal sinuses and close to the cranial cavity and complex craniofacial bones. Orbital fractures can occur in isolation or in association with maxillofacial or craniofacial trauma, particularly caused by road traffic accidents, assault and sport related accidents or fall. Craniofacial or maxillofacial trauma are often complex and serious in nature[3]. Such injuries can lead to large comminuted, severely displaced and complex fractures involving multiple planes[20]. Although simple and linear orbital

fracture can be easily diagnosed by conventional radiographs, but it is very difficult to diagnose the complex mid facial fractures by the conventional radiography either due to superimposition of bony structures producing ghost artifacts or impaired visualization of underlying fine fractures by periorbital edema, ecchymosis and internal hemorrhage[7].

Various studies revealed that 3D reformatted images provide enhanced diagnostic accuracy and helps in better treatment planning as 3D imaging helps in detecting and localizing the exact number and site of orbitofacial fractures[21]. Jasbir[7] reported that pre-operative 3D CT is mandatory in case of severe maxillofacial trauma to decide the treatment modality as primary bone grafting, internal or external fixation or conservative treatment, as 3D CT demonstrates the relative size and shape of fractured fragments, degree of comminution and displacement, which is difficult to assess on the conventional radiographs. Levy[13] found that tripod fractures are better displayed in 3D CT.



In our study, additional 86 fractures were detected by 3D CT in 45 cases, which is comparable with findings of Jasbir[7] and Gillepsie[22]. A survey conducted by Alder[23] found that clinicians preferred 3D CT over conventional 2D for treatment. Rueben et al reported different levels of experience about radioimaging of trauma cases; non radiologist viewers can correctly diagnose the fractures in 75.7% of 3D CT, 71.5% of radiographs and 64.7% of conventional CT. Fox[24] also found that clinicians interpreted 3D reformatted CT more rapidly and more accurately. 3D CT reformatted images are also helpful in communicating findings to the family physicians caring the injured ones, and for educating the patient and their family members about the treatment and prognosis. 3D CT is also very helpful in post-operative evaluation [Fig. 16-17]. Gillepsie[22] explained that 3D CT is important only in cases of severe trauma with multiple fractures, has not much role in minor trauma or simple isolated orbital fracture limited to one plane and without fragment displacement. He also reported that in fractures involving the inferior or medial orbital wall, 3D CT was reliable due to presence of pseudoforamina. Studies suggested that 3D CT scans alone can give false negative results[18,25]. Thus we can conclude that 3D CT is complementary to conventional 2D CT imaging in management of severe/ complex, acute orbitofacial or craniofacial trauma by providing additional information.

3D CT reconstruction is not only helpful in management of orbital trauma, but also useful during planning and performing the orbital surgery for orbital tumor/ cystic lesions or any orbital space occupying lesion. A common problem during orbital surgery is the relationship between pathological lesions and vital adjacent neuro-muscular and vascular structures. 3D reconstructed volumetric CT imaging provides information regarding location, size of tumor and compressed/ displaced ocular/ vascular structures and the condition of underlying bone (bone scalloping, fossa formation, defect and destruction), thus enabling subtle planning of the surgical approach to orbit.

Liang Li[1] found that 3D CT has certain diagnostic value in deep orbital cystic lesions in determining the nature, localization of the cyst and compression induced sclerotic changes. CT based orbital volume assessment is required in case of orbital tumor, dysthyroid orbitopathy and congenital orbital deformity. Calculation of bony orbital volume, orbital fat volume and extraocular muscle volume is possible with help of software (image processing package with 3D reconstructor) using computer assisted segmentation and computer assisted border detection techniques[26]. 3D reformatted image of orbital CT angiography is useful in management of vascular orbital lesions like haemangioma and A-V malformations.

## Conclusions

In conclusion this study highlights the importance of 3D reformatted CT imaging in evaluation of orbital pathologies particularly in complex & severe orbital trauma, advanced ocular tumor and congenital bony malformation. 3D CT imaging is important tool for preoperative analysis & surgical planning due to ability to visualize fracture displacement, generation of the tumor contour file helps in measurement of the dimension of the tumor and volumetric assessment. The 3D CT is always complimentary to 2D CT imaging. 3D CT image is an essential pre-requisite for evidence based management. Further the 3D volume images remain of prime importance for a clinician to adequately counsel his patients and for post-operative evaluation of surgical results.

**Table 1: Profile of Diagnosis Facilitating Orbital Evaluation by Computed Tomography**

Diagnosis	No	%
Orbital Trauma:	60	54.55
-Isolated orbital trauma	12	10.90
-Orbito-maxillofacial Trauma	28	25.45
-Cranio- Orbito Facial Trauma	20	18.18
Orbital Neoplastic Disorders:	42	38.18
-Benign/ Cystic lesions	17	15.45
-Malignant lesions	25	22.73
Congenital Orbital Disorders:	8	7.27
-Craniofacial syndromes	3	2.73
-Craniosynotoses	2	1.81
-Craniofacial hypoplasia/ socket anomalies	3	2.73

## References

- Liang Li, Liang J, Liang R, Zeng B. Diagnostic value of post-processing technique of multi slice spiral CT in orbital cyst diseases. Eye Science 2012;27(2):89-93.
- Ahmad K, Ansari S, Dhungel K, Gupta MK, Raoniyar RK, Amanullah MF, Siddique MA. Radiological evaluation of Maxillofacial Trauma: Role of MDCT with MPR and 3D reconstruction. 2013;8(2):1027-1034.
- Reuben AD, Smith SRW, Dobson D, Golding SJ. A comparative study of evaluation of radiographs, CT and 3D reformatted CT in Facial trauma: What is the role of 3D? BJ Radiol 2005;78:198-201.
- Jackson IT, Bite U. Three dimensional computed tomography scanning of Major surgical reconstruction of the Head and Neck. Mayoclinproc 1986;61:546-555.
- Herman GT: Three- dimensional imaging on a CT or MR scanner. J Comput Assist to Mogr 1988;12:450-458.
- Eisen MD, Yousen DM, Loevener LA et-al. Preoperative imaging to predict orbital invasion by tumor. Head Neck 2000;22:456-62.
- Kaur J, Chopra R. Three dimensional CT Reconstruction for the evaluation and surgical planning of mid face



- fractures: A 100 cases. *J Maxillofacial oral surgery* 2010;9(4):323-328.
8. Pau CY, Barrera JE, Kwon J, Most SP. Three-dimensional analysis of Zygomatic-maxillary complex fracture patterns. *Craniofacial trauma reconstruction* 2010;3(3):167-176.
  9. Marentette, Maisel RH. Three dimensional CT Reconstruction in mid facial surgery. *Otolaryngeal Head Neck surgery* 1988;98:48-52.
  10. Marsh PL, Godo M. Surgical anatomy of Craniofacialdysostosis: insight from CT scans. *Cleft Plastcraniofac J* 1982;19:212-221.
  11. Gentry LR, Manor WF, Turski RA, Strotter CM. High resolution Ct analysis of facial struts in trauma: Normal anatomy. *AJR AM J Roentgenol.* 1983;140:523-526.
  12. Altman NR, Altman DH, Wolfe SA, Morreson G. Three dimensional CT reformation in children. *AJR AM J Roentgenol.* 1986;146:1261-1267.
  13. Levy RA, Edwards WT, Meyer JR, Rosenbaum AE. Facial trauma and 3D reconstructive imaging: insufficiencies and correctiveness. *AJNR AM J Neuroradiol.* 1992;13:885-892.
  14. Darling CF, Byrd SE, Allen ED, Radkowski MA, Wilczynski MA. Three-dimensional computed tomography imaging in the evaluation of Craniofacial abnormalities. *J Natti Med Assoc* 1994;86(9):676-680.
  15. Binaghi S, Gudinchet F, Rilliet B. Three-dimensional spiral CT of craniofacial malformation in children. *Peditr Radiol* 2000;30:856-860.
  16. Napels, Marks MP, Rubin GD et al. CT angiography with spiral CT and maximum intensity projection *Radiology* 192;185:607-610.
  17. Rigauts H, Marchal G, Baert AL et al. Initial experiences with volume CT scanning. *J. Comput Assist Tomography* 1990;14:675-682.
  18. Klenk G, Kovacs A. Do we need 3D CT in maxillofacial surgery? *J. Craniofacial surgery* 2004;15:842-850.
  19. Marchac D, Renier D. Treatment of craniosyntosis in infancy, *Clin Plast Surg* 1987;14:61-72.
  20. Saigal K, Winokur Rs, Finden S, Taub D, Pribitkin P. Use of Three Dimensional computerized tomography reconstruction in complex facial trauma. *Facial plastsurg* 2005;21(3):214-219.
  21. Mayer JS, Wainwright DJ, Yeakley JW, Lee KF, Harris JH, Kulkarni M. The role of three-dimensional computed tomography in management of maxillofacial trauma. *J Trauma* 1988;28:1043-1053.
  22. Gillespie JE, Isherwad I, Barger GR, Quayle AA. Three dimensional reformations of computed tomography in assessment of facial trauma. *Clin Radiol* 1987;38(5):523-526.
  23. Alder ME, Deahl ST, Matterson SR, Clinical usefulness of Two.
  24. FOXLA, Vannier MW, West OC, Wilson AJ, Baran GA, Pilgram TK> Diagnostic performance of CT, MPR and 3D CT imaging in maxillofacial trauma, *Comput. Med Imaging* 1995;19:220.
  25. Dos Santos DT, Costa e silva AP, Vanniar MW, Cavalcanti MG, validity of multislice computerized tomography for diagnosis of maxillofacial fractures using an independent work station. *Oral surg Oral med Oral path Radiol Endol* 2004;53:375-386.
  26. Regensburg NI, Kok PHB, Zonneveld FW, Baldeschit, Saeed P, Wiersinga WM, Mourits MP. A new and validated CT based method for calculation of orbital soft tissue volumes. *Invest Ophth Vissci* 2008;49:1758-1762.