

# Custom Ocular Prosthesis Fitting Following Evisceration: Staphyloma Vs. Non-staphyloma cases

Deepa Diddi Raizada, M.Sc.<sup>1\*</sup>, Kuldeep Raizada, PhD<sup>2</sup>

<sup>1</sup>Department of Ocular Prosthesis, L V Prasad Eye Institute, Hyderabad

<sup>2</sup>International Prosthetic Eye Centre, Hyderabad

**\*Corresponding Author:**

Email: deepaocularist@gmail.com

---

## Précis

Corneal or sclera staphylomas are shown to give rise to eyelid deformities, most commonly ptosis; which are encountered by Ocularists during fabrication of a custom ocular prosthesis following eye removal surgery.

## Abstract

**Purpose:** To assess and compare the prosthetic eye fitting in the patients undergoing evisceration with implant in staphyloma vs. non-staphyloma cases.

**Methods:** It was a retrospective, comparative and interventional study. Patients who underwent evisceration with silicone orbital implant placement, and fitted with custom ocular prosthesis between August 2006 and April 2007 were included. Based on the indication for surgery, the patients were grouped under staphyloma and other conditions. Eyelid and socket abnormalities, and additional modifications undertaken to correct these abnormalities during fabrication of custom prosthesis were assessed, and compared between the two groups. Independent samples T-test was used for statistical analysis.

**Results:** In the staphyloma group, 9 of 16 (56.3%) had ptosis (6), eyelid retraction (2), and deep superior sulcus (1) needing prosthesis modification. In contrast, the patients who underwent evisceration for other conditions, only 2 of 27 (7.4%) required modifications for lid sag. Statistical analysis showed significantly greater number of patients needed modifications in staphyloma group as compared to non-staphyloma group ( $P=0.001$ ).

Implant size, and duration between the date of surgery and the prosthesis fitting were compared between two groups, which showed no statistically significant difference ( $P=0.096$  and  $P=0.108$  respectively).

**Conclusion:** The patients with staphyloma undergoing evisceration with implant can have cosmetically concerning eyelid abnormalities, most commonly ptosis that may need attention during fabrication of the prosthetic eye. These eyelid abnormalities could be due to long standing effect of staphyloma, possibly due to levator disinsertion, dehiscence or stretching; or due to insufficient volume replacement by an orbital implant.

---

## Introduction

Ocular diseases like intraocular malignancies, traumatized globes, painful blind eyes, staphylomas, disfigured globes, etc. are the common indications for eye removal surgeries (i.e. enucleation or evisceration). These procedures can be performed along with the placement of an orbital implant wherever indicated depending on the underlying cause.<sup>1,2</sup>

Eyelid and socket abnormalities associated with anophthalmic socket include upper eyelid ptosis, lower lid laxity, lower lid sagging, entropion, ectropion, shallow fornices, contracted socket, superior sulcus deformity, enophthalmos and hypoglobus/ hypophthalmos (vertical displacement of the prosthesis).<sup>3,4</sup> These abnormalities may be seen with either

enucleation or evisceration. However, they are commonly noticed following enucleation, which are so substantially minimized following evisceration.<sup>5,6</sup>

Staphylomas, one of the clinical indications for eye removal, clinically present with a localized bulging or protrusion of globe. It is an infiltration of the uveal tissue through weak or thinned out outer coat (cornea or sclera). They can be either congenital or acquired, and also can be unilateral or bilateral. Depending on the site of lesion, staphylomas can be categorized under anterior, intercalary, ciliary, equatorial and posterior staphyloma.<sup>7</sup> Anterior staphyloma is a corneal staphyloma, others are scleral staphylomas. Evisceration with the placement of an orbital implant is the most preferred treatment modality.<sup>8</sup>

Ultimate aim of surgery is to rehabilitate the socket with a good prosthetic eye fit by an Ocularist.<sup>3</sup>

Custom ocular prosthesis fabricated using modified impression technique is the standard of care in most developed countries. This technique has feasibility to apply principles of form modification for correcting cosmetic defects such as ptosis, sulcus deformity, enophthalmos etc.<sup>9,10</sup> Ocularists come across these defects routinely in their clinical practice, when fitting an anophthalmic socket. However, it is not clear who are at risk in large.<sup>5,11</sup> There is no idea of whether any enlarged lesions of globe as in staphyloma have any impact. Literature search pertaining to any association between staphylomatous condition of eyeball and these cosmetic defects is not clearly evident.

Kim MJ *et al.*<sup>11</sup> reported a case series of 3 patients with congenital corneal staphyloma treated by evisceration followed by primary implant placement. Upper eyelid ptosis was noted in one case when the prosthetic eye was fitted. The surgery was performed by placing an 18mm porous polyethelene implant. Shreedhar A *et al.*<sup>8</sup> reported a case who was diagnosed to have severe anterior and 360° ciliary staphyloma, which was associated with a high upper eyelid crease and lower eyelid entropion. Evisceration procedure was carried out by placing a 20mm PMMA orbital implant. Post-surgery, the lower eyelid entropion resolved spontaneously; but possibility of upper eyelid ptosis was explained due to presence of a high lid crease. Apart from these two, none other studies were found on this subject.

The purpose of this study is to evaluate and compare the prosthetic eye fitting in the patients undergoing evisceration with implant for staphyloma vs. non-staphyloma indications.

## Materials and Methods

This is a retrospective, comparative and interventional study. All consecutive patients who underwent evisceration with silicone orbital implant placement, and subsequent custom ocular prosthesis fitting between August 2006 and April 2007 were included. Data collection from medical records of the patients included patient demographics, affected eye, underlying cause for the surgery, duration of the underlying condition,

implant size, duration between surgery and the prosthesis fitting in weeks, post-surgical complications, complications or cosmetic defects encountered during fabrication of custom prosthesis, additional modifications undertaken to correct the cosmetic defects and about the final aesthetic outcome.

Evisceration was performed by placing a silicone orbital implant within the scleral shell in all the patients. Prosthesis was fabricated using modified impression technique, which involved conversion of alginate impression into a wax model. The wax model was then sculpted to match for its size (horizontally, vertically and antero-posteriorly) and shape as close as possible to the normal eye; then the iris–corneal position was recorded. Final wax model was molded, and the prosthesis was fabricated using medical-grade acrylic material.<sup>9,10</sup>

Routinely wax model needs sculpting for fine adjustments to match for its size, shape and iris–corneal position. Additional modifications were undertaken over the prosthetic eye to correct any persisting cosmetic defects, which included ptosis, deep superior sulcus deformity, upper lid retraction and lower lid sagging. Ptosis was corrected by adding the ptosis crutch or shelf modification in the upper portion of the prosthesis, deep superior sulcus deformity was corrected by volume augmentation over upper portion of the prosthesis, upper lid retraction was corrected by groove modification over the prosthesis at the level of upper lid, and lower lid sag was corrected by groove modification over the prosthesis at the level of lower lid. Number of the patients who required these modifications were noted and recorded. The main outcome measure was to compare the additional modifications required to correct the eyelid and socket abnormalities between staphyloma and non-staphyloma group.

Implant size, duration between surgery and the prosthesis fitting, and additional modifications undertaken over custom prosthesis were analyzed and compared between the two groups. Independent sample T-test was used for all the statistical analysis with a significance level of  $\alpha = 0.05$ .

## Results

A total of 43 patients underwent evisceration with implant, and fitted with custom prosthesis during the study period. Group 1 (staphyloma group) included 16 (10 females and 6 males) patients. Right eye was fitted in 37.5% (6) and left eye was fitted in 62.5% (10). In group 2 (non-staphyloma group), there were 27 (5 females and 22 males) patients. Right eye involvement was present in 55.6% (15) and left eye involvement in 44.4% (12). Mean age of the patients in staphyloma group was 21.47 years (range: 3.5 – 41 years) and in non-staphyloma group was 37.15 years (range: 4 – 77 years). Underlying cause for surgery in staphyloma and non-staphyloma group was illustrated in Table 1.

**Table 1: Indications for surgery**

Staphyloma group		Non-staphyloma group	
Underlying cause	Cases	Underlying cause	Cases
Anterior staphyloma	9	Painful blind eye	10
Anterior staphyloma with buphthalmos	2	Disfigured globe	6
Anterior and ciliary staphyloma	2	Perforated corneal ulcer	5
Anterior and intercalary staphyloma	1	Endophthalmitis	3
Ciliary staphyloma	1	Microbial keratitis	3
Intercalary staphyloma	1		

**Table 2: Complications based on duration of staphyloma**

Duration of staphyloma	Cases	Complications/ Cosmetic defects			
		None	Ptosis	Retraction	Deep sup. sulcus
≤ 10 years (range: 1-10 years)	6	4(66.7%)	1(16.7%)	1(16.7%)	0
>10 years (range: 11-26 years)	10	3(30%)	5(50%)	1(10%)	1(10%)

Mean implant size placed in staphyloma group was 16.25 mm (sd=1.00 mm, range=15-19 mm); in non-staphyloma group was 15.59 mm (sd=1.34 mm, range=11-19mm). This was compared between two groups, which showed no statistically significant difference (P=0.096).

Custom ocular prosthesis was indicated after 6 weeks following the surgery. Mean duration between the surgery and the prosthesis fitting in staphyloma group was 8.16 weeks (sd=0.93 weeks, range=7-10 weeks); in non-staphyloma group was 8.94 weeks (sd=1.78 weeks, range=6-14 weeks). This was compared between two groups that showed no statistically significant difference (P=0.108).

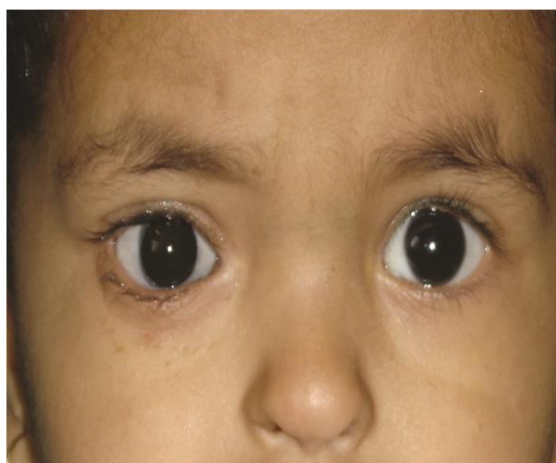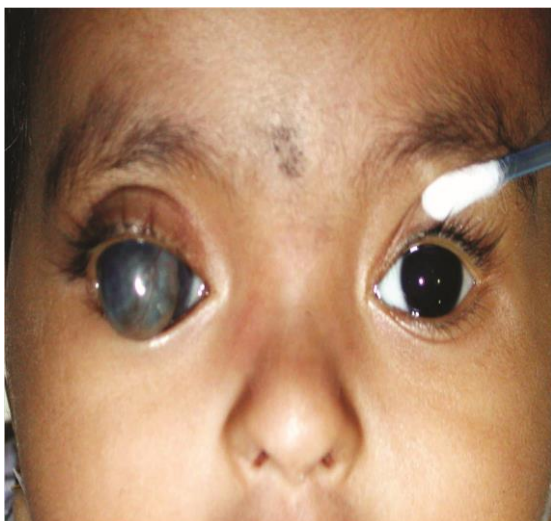Based on the history given by the patients, duration of the staphyломatous condition and complications encountered during fabrication of custom prosthesis (cosmetic defects) that required additional modifications were evaluated. These results were summarized in Table 2.

In staphyloma group, 56.25% (9 out of 16 patients) required additional modification over custom prosthesis: 6(37.5%) patients required ptosis correction, 2(12.5%) patients required correction for upper lid retraction and 1(6.25%) patient required deep superior sulcus deformity

correction. In non-staphyloma group, 7.4% (2 out of 27) patients required additional modification to correct lower lid sagging. This was compared between the two groups, which showed a statistically significant difference (P=0.001). However, none of the patients required any surgical correction.

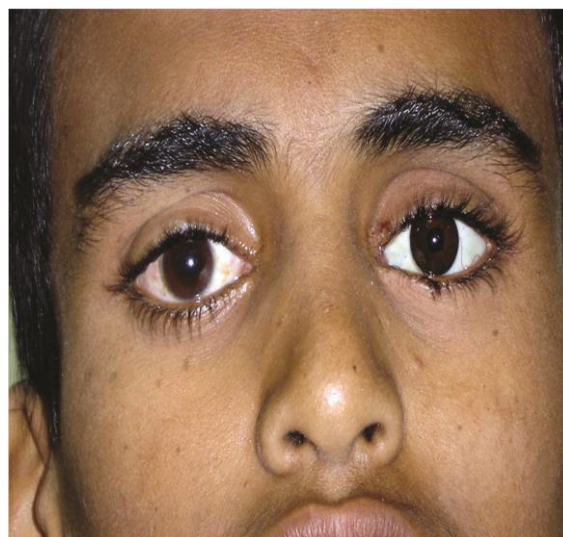
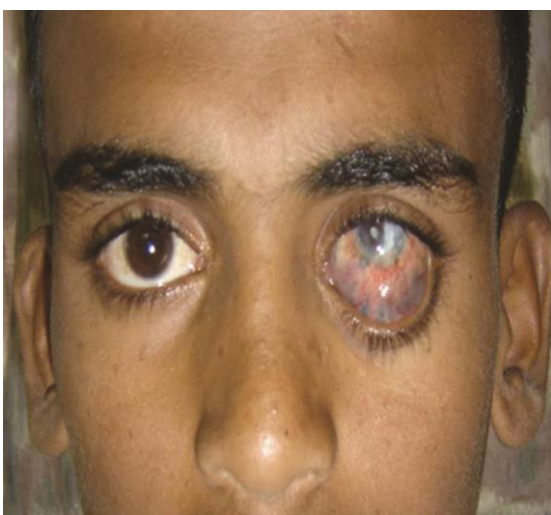## Discussion

Staphyloma are caused due to various conditions. Corneal (anterior) staphyloma can develop following small pox, corneal ulcer, trauma and keratomalacia.<sup>12</sup> Scleral staphyломas could be secondary to axial or pathological myopia, scleritis, buphthalmos, long-standing absolute glaucoma, scleromalacia, trauma; or it can be idiopathic.<sup>12,13</sup> A case of corneal and sclera staphyloma has been illustrated in Fig. 1 and Fig. 2 respectively. Most Surgeons prefer doing evisceration over enucleation, favoring final aesthetic outcome and to avoid complications of post-enucleation socket syndrome.<sup>8</sup>



**Fig. 1: A case of anterior (corneal) staphyloma of right eye**

- a) Anteriorly enlarged lesion of corneal staphyloma pre-operatively
- b) Final aesthetic outcome with custom ocular prosthesis post-operatively



**Fig. 2: A case of ciliary and intercalary staphyloma of left eye**

- a) Enlarged lesion of staphyloma causing downward displacement of the lower eyelid
- b) Final aesthetic outcome with custom ocular prosthesis

This study included only eviscerated cases. Most common cause for surgery was painful blind eye followed by anterior staphyloma. All the patients were placed with a silicone orbital implant at the time of surgery, and advised for custom ocular prosthesis fitting 6 weeks after the surgery. Mean duration between the surgery and the prosthesis fitting was 8 weeks in staphyloma group, and 9 weeks in non-staphyloma group.

Staphyloma group showed significantly greater number of problems requiring adjustment of the prosthesis at the time of its fitting, compared to non-staphyloma group ( $P=0.001$ ). These included ptosis, upper eyelid retraction and deep superior sulcus deformity; and were corrected by prosthetic modifications over custom prosthesis. It was described in the literature that poor surgical technique can sometimes give rise to eyelid malpositions.<sup>14</sup> This may not be the reason as expert surgeons performed the surgery.

In any case, when the eyeball or orbital contents are removed, socket anatomy changes. Most people don't have perfect symmetry. Setting realistic expectations with the patient is a key to having a good outcome.

Duration of the staphylomatous condition was assessed to know if this has any affect. In the patients who gave a history of 10 years or less (range: 1-10 years), only one patient (16.67%) had

ptosis; whereas in the group of more than 10 years (range: 11-26 years) duration, 5 (50%) patients had ptosis. This indicates that eyelid deformities tend to arise withstanding the staphyloma for long term. If the condition is present by birth, it can have an effect on bony orbit as well, which is evident in a study where an increased soft tissue volume (e.g. buphthalmos, a diffusely enlarged eyeball secondary to high intraocular pressure) in early childhood caused significant enlargement of bony orbital volume and growth.<sup>15</sup>

In the current study, eyelid deformities manifested in 50% (8 out of 16 patients) cases in staphyloma group, and only 7% (2 out of 27 patients) in non-staphyloma group. As this was a retrospective study, there was no idea of whether these defects were persisting pre-operatively or not; patient's history and pre-operative diagnosis in the medical record did not reveal this factor.

Underlying cause for ptosis (upper eyelid covering more than 2 mm of cornea superiorly) is suspected to be disinsertion, dehiscence or stretching of levatoraponeurosis. This could be due to trauma caused to aponeurosis by constant and long-standing pressure of locally bulged lesion. Another reason could be insufficient volume replacement by an implant for ptosis, and may be excessive volume replacement for upper lid retraction.<sup>13,16,17</sup> Also, large globe in children can cause volume expansion of the orbit or "elongated" lids, thus giving rise to ptosis.

There was one patient who had undergone prosthetic volume augmentation for deep superior sulcus deformity associated with anterior and intercalary staphyloma. The cause for sulcus deformity described in the literature was orbital volume loss, which could be due to: 1) insufficient volume replacement of the orbital contents, and 2) atrophy of the orbital fat that can occur after removal of an eyeball.<sup>18</sup>

Implant size did not differ statistically between two groups (P=0.096). However, with reference to the staphylomatous condition (enlarged eyeball), it is suspected to have some additional soft tissue volume (especially in cases with diffuse eye enlargement condition as in buphthalmos).<sup>12</sup> Deficit in the volume replaced by an implant may be suspected as one of the cause for ptosis and sulcus deformity. Implant size selection guided by A-scan measurements<sup>19</sup> would have proven to be helpful in assessing the condition objectively.

Cosmetic defects that Ocularist encounter during fabrication process, can be corrected by

form modifications of custom prosthesis.<sup>9,10,20,21</sup> Surgical correction can be undertaken if prosthetic modalities fail.<sup>14</sup> Sometimes the surgery involves correction of only the residual defect after manipulating the prosthesis. Therefore, communication between the Ocularist and the Oculoplastic Surgeon is of paramount importance prior to surgery.<sup>4,14,22,23</sup> The more specific the ocularist and surgeon are in their correspondence, the more likely the patient will come to accept their result. All the defects were adequately corrected by prosthetic modifications in this study, none required surgical intervention.

To conclude, results of this study showed that the patients with staphyloma can have eyelid or socket abnormalities most commonly ptosis, which needs attention during fabrication of the custom prosthesis. These abnormalities could be due to levator muscle disinsertion, dehiscence or stretching as an effect to enlarging lesion; or due to insufficient volume replacement by an orbital implant.

## References

1. Nunery WR, Chen WP. *Enucleation and evisceration*. Bosniak S, editor. Vol. 2. Principles and Practice of Ophthalmic Plastic and Reconstructive Surgery. Philadelphia: WB Saunders Company; 1996.
2. Baylis H, Shorr N, McCord CD Jr, Tanenbaum M: *Evisceration, enucleation and exenteration*. McCord C Jr and Tanenbaum M (eds): Oculoplastic Surgery, 2<sup>nd</sup> ed. New York, Reven Press, 1987:408-430.
3. Cluster P, Cook B. The team approach to the anophthalmic patient. *Adv Ophthalmic Plast Reconstr Surg*. 1990;8:55-7.
4. Wills J, Weyland S, McRobbie I. Orbital Anatomy for Rehabilitation: The Ocularist's Point of View. *Adv Ophthalmic Plast Reconstr Surg* 1990;8:58-68.
5. Tillman WT. Superior Cosmesis Following Evisceration. *J Am Soc Ocularists* 1980;10:14-21.
6. Lindsey RN, Soper MP. Sympathetic Ophthalmia Following Evisceration: A Review of the Literature. *J Am Soc Ocularists* 1986;17:28-30.
7. Pramod TK. *Best aid to Ophthalmology*. JP Medical Ltd; 2013:130-31.
8. Sreedhar A, Sundar G, Honavar S, et al. Managing a Cosmetic Blemish. *Kerala J Ophthalmol* 2008;20(2):192-96.
9. Allen L, Webster HE. Modified impression method of artificial eye fitting. *Am J Ophthalmol* 1969;67:189-218.
10. Allen L, Bulgarelli DM. Obtaining and understanding the Alginate Impressions. *J Am Soc Ocularists* 1988;19:4-13.
11. Kim MJ, Choung HK, Kim NJ, khwarg SI. Congenital corneal staphyloma treated by evisceration and primary implant placement: 3 cases. *Can J Ophthalmol* 2008;43(1):111-3.
12. Mukherjee PK. *Clinical Examination in Ophthalmology*. Elsevier Health Sciences; 2006:63-83.
13. Smith M, Castillo M. Imaging and differential diagnosis of the large eye. *RadioGraphics* 1994;14(4):721-8.
14. Weinstein GS. Eyelid malpositions in Anophthalmic Patients. *J Am Soc Ocularists* 1991;22:16-18.

15. Heinz GW, Clunie DA, Mullaney PB. The effect of buphthalmos on orbital growth in early childhood: increased orbital soft tissue volume strongly correlates with increased orbital volume. *J AAPOS*. 1998;2(1):39-42.
16. Workman CL. Prosthetic reduction of upper eyelid ptosis. *Adv Ophthalmic Plast Reconstr Surg* 1990;8:184-91.
17. Kaltreider SA, Shields MD, Hippeard SC, Patrie J. Anophthalmic Ptosis: Investigation of the mechanisms and Statistical Analysis. *Ophthal Plast Reconstr Surg* 2003;19(6):421-8.
18. McRobbie I. RTV Silicone Augmentation. *J Am SocOcularists* 1990;21:50-51.
19. Kaltreider SA, Lucarelli MJ. A simple algorithm for selection of implant size for enucleation and evisceration: a prospective study. *Ophthal Plast Reconstr Surg* 2002;18(5):336-41.
20. Cox CW. Prosthetic Ptosis Correction. *J Am SocOcularists* 1988;18:11-14.
21. Lewis F. Prosthetics for Complicated Eye Sockets. *J Am SocOcularists* 1979;9:6-10.
22. Johnson WJ. Fitting the Anophthalmic Socket: Achieving Cosmesis with Comfort. *Adv Ophthalmic Plast Reconstr Surg* 1990;8:126-35.
23. Jahrling KV. Ocular Prosthetic Limitations and Indications for Out Patient Surgical Referral. *J Am SocOcularists* 1991;22:34-38.