

Epidemiology and visual outcome in open globe injuries in children

Mary Esther John B^{1,*}, Deepa John², Padma Paul³, Renu S. Raju⁴

¹Department of Ophthalmology, SIH-R & LC, Karigiri, Vellore, ^{2,3}Department of Ophthalmology, Christian Medical College, Vellore, ⁴Department of Ophthalmology, SMH, Ranipet, Vellore

***Corresponding Author:**

Email: maryesther_john@rediffmail.com

Abstract

Background: Ocular trauma is one of the most important causes of unilateral vision loss in children. Children are more susceptible to eye injuries due to their increased physical activity. Visual impairment in children is of great significance due to risk of amblyopia.

Aims:

- To study proportion of open globe injuries among patients less than 18 years of age presenting to Ophthalmology department
- To study proportion of various types of penetrating ocular injuries
- To determine factors influencing visual outcome

Setting: Department of Ophthalmology, Christian Medical College, Vellore, T.N., India.

Methods: Observational study which included retrospective chart review for 4 years and prospective study for 6 months. All children at or below 18 years of age with open globe injury were included.

Results: Boys in age group 5-14 years were injured most. Wooden stick injury is the most common mode of injury. Indoor injuries were more common. Visual outcome at 6 months follow up: 44.5% had better than 6/18, 25.1% had 6/18 to 3/60 and 30.3% had poor vision of <3/60. Our study shows significant association between poor vision & blindness and corneal tear involving visual axis (50/156, $p=0.001$), presence of RAPD (42/156, $p=0.000$) and presence of IOFB (24/156, $p=0.034$).

Conclusion: Our study showed 30.3% of children with open globe injuries resulted in poor vision and blindness. Childhood ocular trauma can result in amblyopia. Good awareness about prevention should be attained by health education.

Keywords: Open globe injuries, Pediatric eye trauma, Visual outcome

Introduction

Ocular trauma has been reported as one of the leading causes of preventable unilateral vision loss in children^{1,2}. Children are prone to injuries due to their curiosity, immature motor skills and increased physical activity³. Visual impairment in childhood is of greater significance as, in addition to physical disability, it has a major impact on social and psychological development of the child.^{1,4}

The American National Society for Prevention of Blindness has estimated that 55% of ocular injuries occur before the age of 25 years and one-third of vision loss in the first decade of life is due to ocular trauma⁵. Children less than the age of 8 years are at increased risk for poor visual outcome because of the threat of amblyopia⁶. Hence, it is important to determine the magnitude of the problem, identify the major causes of trauma and factors that affect the visual prognosis. This will

help in planning effective and target preventive strategies.

There are various studies on ocular trauma in children among the developed countries, however very limited data is available from developing countries⁷. National programme for control of blindness considered ocular trauma as the fourth important cause of avoidable blindness⁸.

Materials and Methods

After obtaining approval by the Institutional Review Board, we did an observational study on open globe injuries in children. Children \leq 18 years, who sustained open globe injury to one or both eyes were included. Study had a retrospective arm of 4 years, including children who had sustained ocular injury from August 2007 to July 2011. It also had a prospective arm for 6 months including children who presented with open globe injuries to the emergency services from August 2011 to January 2012.

Vision assessment was done for all children pre and post operatively. In preverbal and verbal preschool children, vision was assessed with Cardiff cards. In school going children it was assessed with Snellen chart. Vision was classified into 5 groups : 6/6 \geq 6/12, 6/18-6/36, 6/60 to 4/60, 3/60 to 2/60, 1/60 to perception of light (PL), no PL and as un-cooperative.

Demography, mode of trauma, pre and post-operative vision, anterior and posterior segment details for the retrospective arm was noted from the medical records. For the prospective arm, the demography as well as vision and ocular examination was done by the primary investigator. Details on ocular examination specifically included factors like relative afferent pupillary defect, corneal tear involving the visual axis and status of the lens. Imaging was done for all children to rule out intraocular foreign body. Details on primary and secondary surgical interventions as well as best corrected visual acuity at 6 months post trauma were documented.

The routine statistics, including proportions, means and chi-square tests were carried out with SPSS software. Odds-ratio and 95% confidence intervals were computed to evaluate the strength of association between the various factors.

Results

Fifty thousand and seventy children attended the out-patient clinic in the department of ophthalmology at the Christian Medical College, Vellore, South India, from August 2007 to January 2012. Among them, 216 children had open globe

injuries (0.43%). Medical records of 156 children (72.22%) could be retrieved and analyzed. The mean age among boys and girls were 9.04 (SD+/-4.31) and 7.66 years (SD+/-4.60) respectively. 108 children (69.2%) belonged to 5 to 14 years age group. (Fig. 1)

In 30.76% injuries occurred indoor while in 12.82%, injury occurred outdoor. In more than 50%, the place of injury could not be elicited as there were no adult witness while sustaining the injuries.

Wooden stick is the predominant object causing open globe injuries in children (41.6%) followed by metal piece (17.3%), glass piece (7.1%) and fire crackers (6.4%) (Fig. 2). After obtaining parental ciprofloxacin, all our patients underwent primary surgical repair within 24 hours of presentation. Pre-operative vision assessment is mentioned in Table 1. Various surgical interventions done were as listed in Table 2. 56 (35.89%) children underwent secondary surgical procedures. The details are as in Table 3. Vision at 6 months after surgery is listed in Table 4. We assessed association of visual outcome with presence of relative afferent pupillary defect (RAPD) at presentation, presence of intra ocular foreign body (IOFB) on imaging, corneal tear involving visual axis, age \leq 8 years, aphakia and vegetable matter causing injury (Table 5).

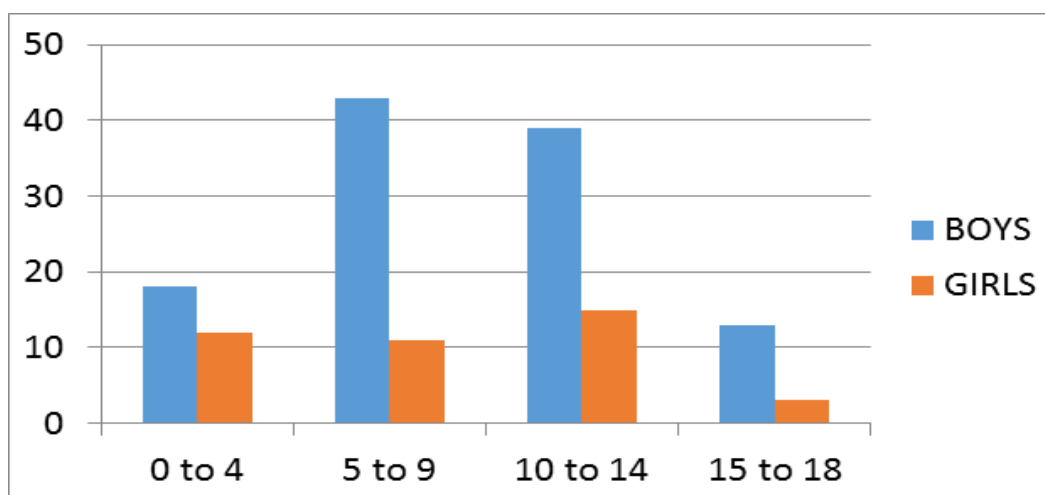


Fig. 1: Frequency of open globe injuries in boys and girls (n=156)

The mean age among boys and girls were is 9.04 (SD+/_4.31) and 7.66 years(SD+/_4.60) respectively. 108 children (69.2%) belonged to 5 to 14 years age group. (Fig. 1)

In 30.76% injuries occurred indoor while in 12.82% injury occurred outdoor.

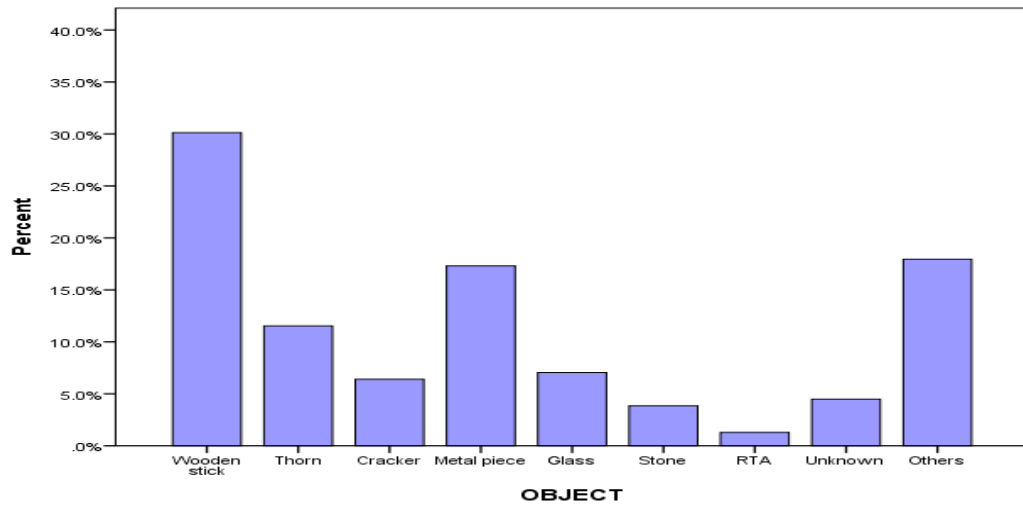


Fig. 2: Object causing injury

[Cracker- fire cracker, RTA- road traffic accident]

Wooden stick is the predominant object causing open globe injuries in children (41.6%) followed by metal piece (17.3%), glass piece (7.1%) and fire crackers (6.4%) (Fig. 2).

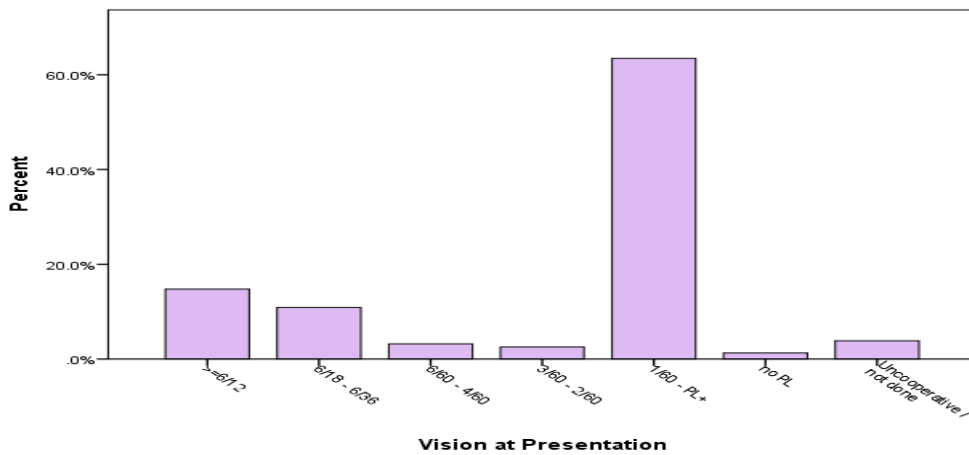


Fig. 3

Table 1: Vision at presentation (n=156)

At Presentation	Frequency	Percentage
≥6/12	23	14.7
6/18-6/36	17	10.9
6/60-4/60	5	3.2
3/60-2/60	4	2.6
1/60-PL	99	63.5
NO PL	2	1.3
Uncooperative/ not done	6	3.8

After obtaining parenteral ciprofloxacin, all our patients underwent primary surgical repair within 24 hours of presentation. Various surgical interventions done are listed in Table 2.

Table 2: Primary surgical intervention (n=156)

	Frequency	Percentage
Corneal Tear(CT) Suturing	60	38.5
Scleral Tear(ST) Suturing	11	7.1
CT & ST Suturing	16	10.3
Lens Matter Aspiration(LMA)	1	6
CT Suturing +LMA	22	14.1
CT&ST Suturing+LMA	3	1.9
ST Suturing+ LMA	1	0.6
Limbal Tear(LT) Suturing	8	5.1
CT Suturing+ Partial Anterior Vitrectomy(PAV)	5	3.2
ST Suturing+ PAV	1	0.6
CT Suturing + LMA+PAV	23	14.7
CT+ST Suturing+LMA+PAV	2	1.3
Evisceration	2	1.3
Enucleation	1	0.6

56(35.89%) children in our study underwent secondary surgical procedures. The details are as in Table 3.

Table 3: Secondary surgical interventions

Sec Surgery	Frequency	Percentage
Lens Matter Aspiration (LMA)	7	4.49
Intra Ocular Lens Implant (IOL)	17	10.9
LMA+ Primary Posterior Capsulotomy (PPC) + Partial Anterior Vitrectomy (PAV)+IOL	6	3.85
Resuturing	9	5.77
Vitreous tap	3	1.92
Vitrectomy + IntraVitreous Antibiotic	5	3.21
Evisceration	1	0.64
Others	8	5.13
Total	56	35.89

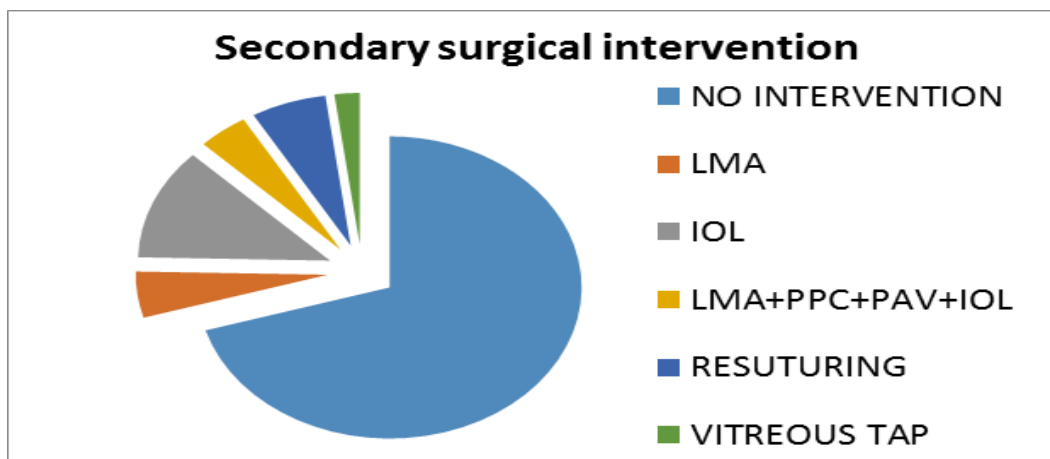


Fig. 4

LMA: Lens Matter Aspiration, **IOL:** Intra Ocular Implant, **LMA+PPC+PAV+IOL:** Lens Matter Aspiration + Primary Posterior Capsulotomy + Partial Anterior Vitrectomy+ Intra Ocular Implant

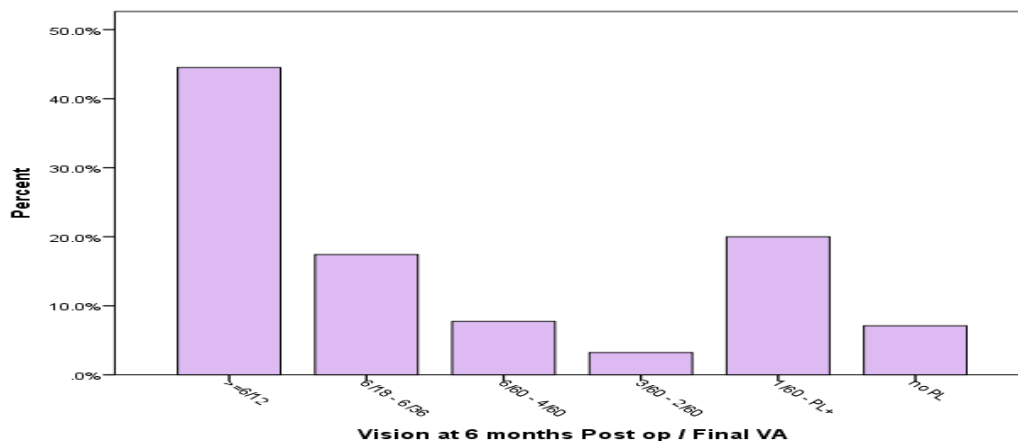


Fig. 5: Visual Outcome at 6 months

Table 4

Visual outcome at 6 Months	Frequency	Percentage
≥6/12	69	44.5
6/18-6/36	27	17.4
6/60-4/60	12	7.7
3/60-2/60	5	3.2
1/60-PL	31	20.0
NO PL	11	7.1

We assessed association of visual outcome with presence relative afferent pupillary defect at presentation, presence of intra ocular foreign body (IOFB) on imaging, corneal tear involving visual axis, age ≤ 8 years, aphakia and vegetable matter causing injury (Table 5).

Table 5: Factors effecting visual outcome (n= 156)

Baseline characteristic	n	95% CI	P
Relative afferent pupillary defect	42	2.84 to 13.31	< 0.01
Intra ocular foreign body	24	2.08 to 13.03	< 0.01
Corneal tear involving visual axis	50	1.89 to 8.45	<0.01
Age ≤ 8 years	78	0.61 to 2.38	0.601
Aphakia in ≤ 8 years	33	0.67 to 6.60	0.207
Trauma with vegetable matter	65	0.78 to 3.22	0.206

Discussion

A retrospective study done by SG Jaison et al in Northern India included 80 children below 15 years of age. These children were divided into 3 age groups: 0 to 5 years, 6 to 10 years and 11 to 15 years. 40% of the children belonged to the 6 to 10 years age group⁵. The study conducted at Birmingham included children less than 16 years of age with open globe injuries. The mean age in their study was 9 years and 4 months⁶. A retrospective study done at Wilmer Eye Institute,

The Johns Hopkins Hospital, Baltimore included 218 children aged less than or equal to 14 years. Overall mean age was 8.2 years.⁹ Another retrospective study done at National Cheng Kung University Hospital in Taiwan by Liu ML et al included children 15 years or younger. The study included 156 children with mean age of 7.1 \pm 0.3 years. Mean age for boys was 7.3 \pm 4.4 years. The mean age for girls was 6.7 \pm 4.3 years.¹ In our study; the mean age was 8.66 years. The mean age among boys was 9.04 years and among girls

was 7.66 years respectively. The majority of children were from 5 to 14 years age group. This is the age group when children try to do things on their own but they do not have adequate maturity to make right decisions on their own and are also influenced by their peer groups to do adventurous activities. They tend to play with potentially hazardous objects like wooden sticks, crackers, etc. without understanding the potential risks.

A higher incidence of trauma is seen in boys, probably because of their increased physical activity. A study done at Birmingham had boys to girls ratio of 4:1.⁶ The study done at Johns Hopkins Hospital had 5 times as many boys than girls². The study done at Taiwan had boy: girl ratio of 1.8:1 for children from 0 to 5 years, 2.3:1 for those who were 6 to 10 years, and 2.5:1 for those who were 11 to 15 years old. The overall ratio of boys to girls was 2.1:1.¹ The predominance of boys was seen in our study also with boys to girls ratio being 2.6:1.

Our study showed that wooden stick is the predominant object resulting in open globe injuries (41.6%). Wooden sticks contain organic matter and are high risk for causing ocular infection. The second most common object causing trauma in our study were metal (17.3%) followed by glass objects (7.1%) and fire crackers (6.4%). Unknown objects accounted for 4.5% of injuries. Other studies have analyzed the frequencies of objects causing open globe injuries. The study done by SG Jaison et al in Northern India showed that ocular injuries occurring during sports was the most common mechanism (52.8%) resulting in open globe injuries among children. The study also showed that the main sports resulting in trauma were playing with bow and arrow and gillidanda(47.2%). Domestic accidents resulted in 31.5% of injuries. Fire crackers caused 15.7% of injuries⁵. The study done by Rohit Saxena et al included 204 children, showed that the most common object causing injury was bow and arrow(15.2%) followed by household appliances (14.3%)¹⁰. In a study done by Liu ML et al in Taiwan unspecified sharp object caused 16.7% of injuries followed by scissors which caused 13.5% of injuries. This was followed by pencils and pens causing 12.2% of injuries.¹ In a study done in Malawi, causes for injury were fire wood 18(25.4%), blunt instruments 11(15.5%), sharp instruments 7(9.9%), fights 7(9.9%), road accidents 3(4.2%), industrial accidents 3(4.2%),

burns 2(2.8%), falls 2(2.8%) and sports accidents 2(2.8%).¹¹

Our study showed that there was significant association between poor visual acuity and the presence of IOFB (p=0.34). Similar result was seen in the study done at The Johns Hopkins Hospital.² The study done in Taiwan also showed that the presence of an IOFB was associated with poor visual outcome (P=0.01).¹ However a study done at Gulhane Military Medical Academy, Turkey, showed that the presence of intraocular foreign body was not associated with poor vision (p=0.076).¹²

Lack of adult supervision could also be responsible for this preventable cause of blindness. Vegetable matter including wooden stick and thorn were the most common causes for ocular injury. Children playing with wooden sticks is a common scenario in developing countries, which can result in blindness. Health education to parents, teachers and child care providers through media can create awareness and can reduce this preventable cause of blindness.

Conclusions

A vast majority of ocular trauma in children is preventable. Effective and targeted preventive strategies will help in reducing their incidence.

Acknowledgments

We acknowledge Mrs. Grace Rebekah, Mr. Albert, Mrs. Joy, Mr. Vishwanathan and Mrs. Jayanthi for their valuable contribution.

References

1. Liu ML, Chang YS, Tseng SH, Cheng HC, Huang FC, Shih MH, et al, Major Pediatric Ocular Trauma in Taiwan, *Journal of Pediatric ophthalmology & Strabismus*,2010;Vol 47, No 2, pg 88-95.
2. Arman K Farr, Richard J Hairston, Michael U Humayun, Marta J Marsh, Dante J Pieramici, Matthew W Mac Cumber, et al, Open globe injuries in children: A retrospective analysis, *Journal of Pediatric Ophthalmology & Strabismus*, March /April 2001;Vol 38, No. 2, pg 72-77.
3. Ching-Hsing Lee, Wan-Ya Su, Lan Lee, Meng-Ling Yang, *Pediatric Ocular Trauma in Taiwan*, *Chang Gung Med J*, 2008;Vol. 31 No. 1.
4. Serrano J C, Patricia Chalela, Juan D Arias, *Epidemiology of childhood ocular trauma in a northeastern Colombian region*, *Arch Ophthalmology*, 2003;121;1439-1445.
5. SG Jaison, SE Silas, R Daniel, SK Chopra, A review of childhood admission with perforating ocular injuries in a hospital in North -West India, *Indian Journal of Ophthalmology*, 1994; Vol 42, issue 4, pg 199-201.
6. Baxter RJ, Hodgkins PR, Calder I, Morrell AJ, Vardy S, Elkington AR, *Visual outcome of childhood anterior perforating eye injuries: prognostic indicators*, *Eye*, 1994;8,349-352.

7. JS Saini, AK Mukherjee, SM Dabral, O Moraes, A profile of penetrating eye injuries, Indian Journal of Ophthalmology, 1985,33, issue 2, pg 95- 97.
8. Strategies for the prevention of blindness in National programmes- A primary health care approach, 2nd edition, WHO, Geneva, 1997.
9. Arman K Farr, Richard J Harison, Michael U Humayun, Marta J marsh, etal, Open Globe Injuries in Children: A retrospective Analysis, Journal of Pediatric ophthalmology & Strabismus, 2001;38:72-77.
10. Rohit Saxena, Rajesh Sinha, Amitabh Purohit, Tanuj Dada, Rasik Vajpayee, Raj V Azad, Pattern of Pediatric Ocular trauma in India, Indian J of Pediatrics, 2002;69(10),863-867.
11. Michael IIsar, Moss Chirambo and Michael Belkin, Ocular injuries in Malawi, British Journal of Ophthalmology, 1982;66,145- 148.
12. F C Erdurman, V Hurmeric, G Gokce, A H Durukan, G Sobaci and HI Altinsoy, Ocular injuries from improvised explosive devices, Eye, 2011;25(11),1491- 1498.