

Content available at: <https://www.ipinnovative.com/open-access-journals>

IP International Journal of Ocular Oncology and Oculoplasty

Journal homepage: <https://ijooo.org/>

Original Research Article

Posterior segment findings in post-Covid mucormycosis: A cross-sectional study

Zainu Shams^{1,*}, C Shwetha Kumari¹, Malvika S B Mutt¹, Bharathi N¹, Madhura M Khanapur²¹Bangalore Medical College and Research Institute, Bangalore, Karnataka, India²Bowring and Lady Curzon Hospital, Bangalore, Karnataka, India

ARTICLE INFO

Article history:

Received 14-04-2022

Accepted 12-06-2022

Available online 27-07-2022

Keywords:

Mucormycosis

Fundus

Post covid

Orbit

ABSTRACT

Purpose: To assess the posterior segment findings in cases presenting with post covid mucormycosis.**Materials and Methods:** A cross-sectional observational study was conducted on patients presented with post-covid mucormycosis who were admitted in our hospital during the time period from 1/5/2021 to 1/9/2021. Our study included cases with and without orbital involvement. Anterior segment examination and fundus examination using indirect ophthalmoscopy was done. Findings were photo documented with fundus camera.**Results:** In a cohort of 248 patients, 183 (73.7%) were males and 65 (26.2%) were females. 210 (84.67%) were diabetics. The mean age was 50.00 +/-12.33 years. A total of 480 eyes were evaluated, out of which 151 (31.45%) had orbital involvement. Of these 151, 65 had normal fundus, 26 (17.21%) had diabetic retinopathy, 22 had CRAO, 12 had disc pallor, 10 had disc edema and 16 had miscellaneous changes. Out of 329 uninvolved eyes, 239 had normal fundus, 53 (16.10%) had diabetic retinopathy. There was no statistically significant difference between the prevalence of diabetic retinopathy in eyes with orbital involvement and without orbital involvement ($p=.39$).**Conclusion:** One-third of the patients with post-covid mucormycosis had retinal findings. These are related to direct disease manifestation as well as underlying co-morbidities.This is an Open Access (OA) journal, and articles are distributed under the terms of the [Creative Commons Attribution-NonCommercial-ShareAlike 4.0 License](https://creativecommons.org/licenses/by-nc-sa/4.0/), which allows others to remix, tweak, and build upon the work non-commercially, as long as appropriate credit is given and the new creations are licensed under the identical terms.For reprints contact: reprint@ipinnovative.com

1. Introduction

In December 2019, when the Chinese ophthalmologist Dr. Li Wenliang warned the world about the outbreak of a deadly virus, little did we know that this invisible enemy could take millions of human lives and put the world on standstill. Two years down the lane as the world is still struggling to contain covid-19, the scenario is being further complicated by the surge of mucormycosis.

Mucormycosis is a lethal, angio-invasive fungal disease predisposed by immunosuppressive drugs including corticosteroids, systemic diseases like diabetes mellitus,

immunodeficiency disorders, malignancies and iron overload.^{1,2} Black fungus/Mucormycosis refers to infections caused by fungi in the order of Mucorales which includes the genus mucor, rhizomucor, rhizopus and absidia.

Mucorales are ubiquitous organisms which is combated by immune competent host through the generation of defensins and oxidative metabolites by the mono nuclear and polymorphonuclear phagocytes. Profound lymphopenia in covid-19 owing to the infection per se and steroid use alters the immune response and renders the host susceptible to invasive fungal infections.³ On inhalation of the spores, mucor proliferate in the sinus and find its way to the orbit either through direct invasion or nasolacrimal duct.

* Corresponding author.

E-mail address: zainushams123@gmail.com (Z. Shams).

In this study, we aim to assess the posterior segment findings in cases presenting with post covid mucormycosis. Apart from few case reports, no comprehensive study has been published on this.

2. Materials and Methods

A cross-sectional observational study was conducted on patients presented to Bowring and Lady Curzon hospital with post covid mucormycosis during the time period from 1/5/2021 to 1/9/2021. Institutional ethical committee clearance was obtained before the initiation of the study. The study was conducted as per declaration of Helsinki. Informed written consent was taken from all the adult study subjects and assents were taken from the parents of paediatric subjects.

All patients with covid recovered status and biopsy proven mucormycosis who were admitted in our wards, and were willing to give valid consent was enrolled in the study. Patients with RT-PCR positive report within the past 14 days, patients who were never reported covid positive previously and eyes with hazy media were excluded from the study.

A detailed clinical history was taken from all the subjects enrolled. Special attention was given to the treatments given during covid-19. Anterior segment examination was done using slit-lamp. Cases were broadly divided into those with or without orbital involvement depending on the clinical features and radiological evidence. Cases with orbital involvement were further divided into involved eye and normal eye. After ruling out narrow angle, all the eyes were dilated with Tropicamide 0.8% & Phenylephrin 5% eye drops. Fundus evaluation of all patients were done with indirect ophthalmoscope and 20 diopter biconvex condensing lens. Findings were photo documented with fundus camera.

2.1. Statistics

Data were entered into the excel spread sheet and analysed statistically using descriptive statistics namely mean, standard deviation, percentage and range wherever applicable. Hypothesis testing was done to check if there exist association between variables using Chi square test. P value < 0.05 was taken as significant.

3. Results

In a cohort of 248 patients with post-covid mucormycosis, 183(73.7%) were males and 65(26.2%) were females. The mean age was 50.00 +/-12.33 (range 5-80) years. 3(1.2%) patients belonged to paediatric age group and 30(12.1%) patients belonged to old age group (>65 years). Amongst the study subjects, 210(84.67%)were diabetics, 61(24.6%) patients were hypertensives, 8(3.22%) had cardiac disease, 6(2.41%) had chronic kidney disease,

6(2.41%) were asthmatic, 4(1.61%) had malignancies and 2(0.8%) had previous cerebrovascular accidents. 17(6.85%) had no history of systemic illness. 142(57.25%) patients has undergone in-patient management for covid-19 pneumonitis, 112(45.16%) patient had oxygen therapy, 120(48.38%) patients had systemic steroid therapy. Mean number of days between the declaration of being covid negative or completion of home isolation and onset of symptoms is 18.50 +/- 13.15 days(range:3-90 days).

A total of 480 eyes were evaluated, out of which 151(31.45%) had orbital involvement. 135(54.43%) patients had unilateral involvement, while 8(3.22%) had bilateral involvement. Out of the eyes with orbital involvement, 65 (43.04%) had normal fundus, 26(17.21%) had diabetic retinopathy, 24(15.89%) had CRAO, 12(7.94%) had disc pallor, 10(6.62%) had disc edema, 2(1.32%) eyes had serous retinal detachment, 2(1.32%) had CRVO, 1(0.06%) had cilioretinal artery occlusion and 9(5.96%) eyes had miscellaneous changes. Out of 329 uninvolved eyes, 239(72.64%) had normal fundus, 53(16.10%) had diabetic retinopathy. There was no statistically significant difference between the prevalence of diabetic retinopathy in eyes with orbital involvement and without orbital involvement (p=.39).

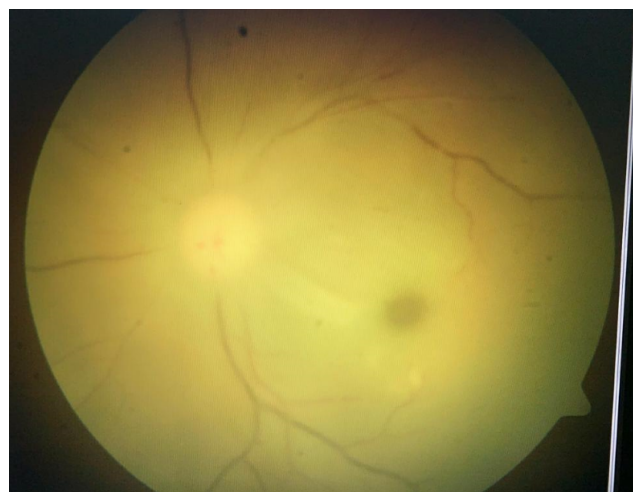


Fig. 1: CRAO in a case of orino-orbital mucormycosis

Out of the eyes with orbital involvement, 65(43.04%) had normal fundus, 26(17.21%) had diabetic retinopathy, 24(15.89%) had CRAO, 12(7.94%) had disc pallor, 10(6.62%) had disc edema, 2(1.32%) eyes had serous retinal detachment, 2(1.32%) had CRVO, 1(0.06%) had cilioretinal artery occlusion and 9(5.96%) eyes had miscellaneous changes.

4. Discussion

In the setting of Covid-19 pandemic, ROCM in India and elsewhere is becoming a matter of immediate concern. The

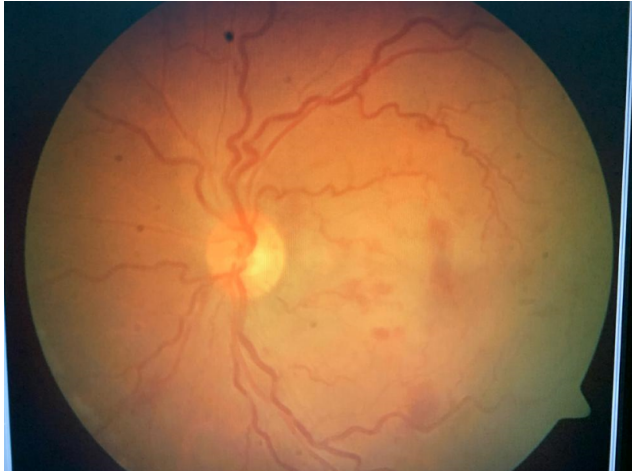

Fig. 2: CRVO in a case of orino-orbital mucormycosis (2)

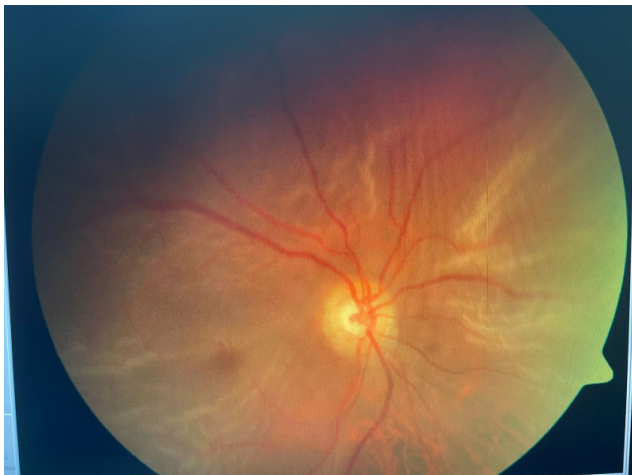


Fig. 3: Serous retinal detachment in a case of rino-orbital mucormycosis

Table 2: Posterior segment findings in the patients with rhinocerebral mucormycosis

Fundus findings	Number of eyes	Percentage
Normal fundus	65	43.04%
Diabetic retinopathy	26	17.21%
CRAO	24	15.89%
Disc pallor	12	7.94%
Disc edema	10	6.62%
Serous retinal detachment	2	1.32%
CRVO	2	1.32%
Cilioretinal artery occlusion	1	0.06%
Miscellaneous	9	5.96%

use of corticosteroid for preventing immune related lung injury and the need of prolonged hospitalisation for oxygen supplementation and respiratory support are presumed to be the main reasons for this. Covid-19 is also known to cause neutropenia adding to the susceptibility of these patients to mucormycosis. Along with this, comorbidities like diabetes mellitus and immunosuppression further worsens the condition.⁴ Millette et al⁵ and Steenblock et al⁶ has reported the effect of Covid-19 in beta cells of pancreas, and this may add to the deterioration of systemic status, making it all the more easier for the fungi to flourish.

Mucormycosis of the orbit is a vision-threatening and potentially fatal infection resulting in angioinvasion, mycotic thrombosis, and ischemic necrosis of tissues. The factors predisposing to the development of the infection are uncontrolled diabetes mellitus, neutropenia, elevated free iron levels, deferoxamine, haematological malignancies, stem cell transplants, and organ transplant patients on immunosuppressants.^{1,7-9}

The mean age of presentation of covid-19 associated mucormycosis as reported by Hoeningel M et al is 55 years (range 10-86 years).¹⁰ Various studies has shown that ROCM has male predilection.¹⁰⁻¹⁴ Demographic profile in our study was almost consistent with these findings. Mean age of our study sample was 50 years and it ranged between 5 and 80 years. Majority (73.7%) of the subjects were males. Greater outdoor exposure and hence, to fungal spores may be the reason for this sex predilection.

Regarding systemic comorbidities, 84.67% of our study population were diabetics. Diabetes mellites has been identified as an independent risk factor for mucormycosis.¹² Multiple literature reviews that has been published seconds this observation.^{10,11} It is noted that the incidence of mucormycosis is 7.5 times higher among diabetics compared to general population.¹⁵ Interestingly 17 patients in our study had no systemic comorbidities. Out of this, 7 did not have history of prior hospital admission for covid-19, nor steroid administration. 5 Of them had history of frequent use of nebulisers and steam inhalation, which are also suspected to be associated with the rise in

Table 1: Systemic illness in the patients with rhinocerebral mucormycosis

Systemic illness	Number of patients	Percentage
Diabetes mellites	210	84.67%
Hypertension	61	24.6%
Cardiac disease	8	3.22%
Chronic kidney disease	6	2.41%
Asthmatic	6	2.41%
Malignancies	4	1.61%
Cerebrovascular accidents	2	0.8%
Nil systemic	17	6.85%

mucormycosis, due to the unsterilized equipment used and poor water quality.^{16–18}

In our study, the mean time period of presentation was around 18 days after recovery from covid-19. Some patients even presented after 2-3 months following covid treatment, which necessitates the need of prolonged follow up following covid recovery.

Out of 480 eyes of 248 patients with rhino-orbito-cerebral mucormycosis evaluated, 151 (31.45%) had orbital involvement. Unlike other anatomical sites, ROCM has visible signs and symptoms leading to early presentation and diagnosis. Most of the patients presented with proptosis, ptosis, loss of vision and facial pain. No predilection in laterality was noted in our study. Cerebral involvement was noted in 37% of the study subjects in previous study,¹⁰ whereas in our study it was only 10%.

Apart from isolated case reports, no large study has been published regarding the posterior segment findings in rhino-orbital mucormycosis. Out of 151 eyes with orbital involvement, 65 had normal fundus, 26(17.21%) had diabetic retinopathy, 24 had CRAO, 12 had disc pallor, 10 had disc edema and 14 had miscellaneous changes. As per literature review, incidence of CRAO is 16%-20% in ROCM.^{19–21} It is attributed to the direct invasion of fungi to the internal elastic lamina of the central retinal artery. Optic neuritis in cases with ROCM is a recognised finding and is postulated as a route of perineural spread of the fungi.^{22–26} In our study, we noted 6 cases with optic neuritis and 4 with papilledema. Exudative retinal detachment in covid-19 associated ROCM has been recorded in the literature^{27–29} and it is proposed that inflammation of the sclera in close contact with necrotic fungi materials may be the cause exudative retinal detachment. We could observe two cases with similar findings in our study. Out of 329 uninvolved eyes, 239 had normal fundus, 53(16.10%) had diabetic retinopathy. We could not find statistically significant difference between the prevalence of diabetic retinopathy in eyes with orbital involvement and without orbital involvement (p=.39).

5. Conclusion

Around one-third of the patients with post-covid mucormycosis had posterior segment findings. These are related to direct disease manifestation as well as underlying co-morbidities.

6. Declaration of Patient Consent

The authors certify that they have obtained all appropriate patient consent forms. In the form the patient(s) has/have given his/her/their consent for his/her/their images and other clinical information to be reported in the journal. The patients understand that their names and initials will not be published and due efforts will be made to conceal their identity, but anonymity cannot be guaranteed.

7. Acknowledgment

None.

8. Source of Funding

None.

9. Conflict of Interest

None.

References

- Honavar SG. Code mucor: guidelines for the diagnosis, staging and management of rhino-orbito-cerebral mucormycosis in the setting of covid-19. 2021;69(6):1361–5. doi:10.4103/ijo.IJO_1165_21.
- Maurya RP. Post COVID-19 Mucormycosis: What is role of iron and iron chelating agents? *Ind J Clin Exp Ophthalmol.* 2021;7(2):253–4.
- Imam S, Mukherjee D, Harikrishnan SN, Sinha AR. Fungus in a viral land-Orbital mucormycosis in patients with covid-19 infection. *OSF Preprints.* 2021;doi:10.31219/osf.io/j5mhh.
- Rawson TM, Moore LSP, Zhu N, Ranganathan N, Skolimowska K, Gilchrist M, et al. Bacterial and Fungal Coinfection in Individuals With Coronavirus: A Rapid Review To Support COVID-19 Antimicrobial Prescribing. *Clin Infect Dis.* 2020;71(9):2459–68. doi:10.1093/cid/ciaa530.
- Millette K, Cuala J, Wang P, Marks C, Woo V, Hayun M, et al. SARS-CoV2 infects pancreatic beta cells in vivo and induces cellular and subcellular disruptions that reflect beta cell dysfunction. *Res Sq.* 2021;p. rs.3.rs-592374. doi:10.21203/rs.3.rs-592374/v1.
- Steenblock C, Ritcher S, Berger I, Barovic M, Schmid J, Schubert U, et al. Viral infiltration of pancreatic islets in patients with COVID-19. *Nat Commun.* 2021;12(1):1–2.
- Skied A, Pavleas J, Drogari-Apiranthitou M. Epidemiology and diagnosis of mucormycosis: An update. *J Fungi (Basel).* 2020;6(4):265. doi:10.3390/jof6040265.
- Papadogeorgakis N, Parara E, Petsinis V, Vourlakou C. A case of successfully treated rhinocerebral mucormycosis: Dental implications. *Int J Dent.* 2010;doi:10.1155/2010/273127.
- Sen M, Lahane S, Lahane TP, Parekh R, Honavar SG. Mucor in a viral land: A tale of two pathogens. *Indian J Ophthalmol.* 2021;69(2):1002–4. doi:10.4103/ijo.IJO_3763_20.
- Hoenigl M, Seidel D, Carvalho A, Rudramurthy SM, Arastehfar A, Gangneux JP, et al. The emergence of COVID-19 associated mucormycosis: a review of cases from 18 countries. *Lancet Microbe;*3(7):e443–52. doi:10.1016/S2666-5247(21)00237-8.
- Singh AK, Singh R, Joshi SR, Misra A. Mucormycosis in COVID-19: A systematic review of cases reported worldwide and in India. *Diabetes Metab Syndr.* 2021;15(4):102146. doi:10.1016/j.dsx.2021.05.019.
- Jeong W, Keighley C, Wolfe R, Lee WL, Slavin MA, Kong DC, et al. The epidemiology and clinical manifestations of mucormycosis: a systematic review and meta-analysis of case reports. *Clin Microbiol Infect.* 2019;25(1):26–34.
- Sen M, Honavar SG, Bansal R, Sengupta S, Rao R, Kim U, et al. Epidemiology, clinical profile, management, and outcome of COVID-19-associated rhino-orbital-cerebral mucormycosis in 2826 patients in India-Collaborative OPAI-IJO Study on Mucormycosis in COVID-19 (COSMIC). *Indian J Ophthalmol.* 2021;69(7):1670–92.
- Desai EJ, Pandya A, Upadhyaya I, Patel T, Banerjee S, Jain V, et al. Clinical Features and Management of Rhino Orbital Mucormycosis in Post COVID 19 Patients. *Indian J Otolaryngol Head Neck Surg.* 2021;74(1):103–7.
- Bala K, Chander J, Handa U, Punia RS, Attri AK. A prospective study of mucormycosis in north India: Experience from a tertiary care

- hospital. *Med Mycol.* 2015;53(3):248–57. doi:10.1093/mmy/myu086.
16. Jamal SA, Rayapati A. A look into the relationship between outdated coronavirus disease 2019 (COVID-19) treatment protocols and the overwhelming rise of mucormycosis in COVID-19 patients in India. *Infect Control Hosp Epidemiol.* 2021;p. 1–2. doi:10.1017/ice.2021.385.
 17. Panta P. Additional insights on COVID-associated mucormycosis. *Br J Oral Maxillofac Surg.* 2021;60(4):e531–2. doi:10.1016/j.bjoms.2021.09.020.
 18. Arakeri G, Patil S, Rao V, Mendes RA, Oepfen RS, Brennan PA, et al. Pathogenesis of COVID-19 associated mucormycosis (CAM) in India: probing the triggering factors. *Br J Oral Maxillofac Surg.* 2021;60(4):e533–4. doi:10.1016/j.bjoms.2021.10.018.
 19. Bawankar P, Lahane S, Pathak P, Gonde P, Singh A. Central retinal artery occlusion as the presenting manifestation of invasive rhino-orbital-cerebral mucormycosis. *Taiwan J Ophthalmol*;10(1):62–5. doi:10.4103/tjo.tjo_72_18.
 20. Bhansali A, Bhadada S, Sharma A, Gupta A, Singh P, Chakarbarti A, et al. Presentation and outcome of rhino-orbital-cerebral mucormycosis in patients with diabetes. *Postgrad Med J.* 2004;80(949):670–4. doi:10.1136/pgmj.2003.016030.
 21. Patnaik A, Sharma B, Ahmad R, Kumar A, Chitrotpala R, Gupta M, et al. A Case of Bilateral Central Retinal Artery Occlusion in a Post-COVID Rhino-Orbital-Cerebral Mucormycosis Patient. *Cureus.* 2021;13(11):e20062. doi:10.7759/cureus.20062.
 22. Singh P, Khan P, Gupta A, Patel N, Chandra T, Yadav DK. Optic neuritis in post-Covid rhino-orbital-cerebral mucormycosis (ROCM): A rare presentation. *Int J Case Rep Images.* 2021;12:101256–101257.
 23. Chaulk AL, Do TH, Supsupin EP, Bhattacharjee MB, Richani K, Adesina OO. A unique radiologic case of optic nerve infarction in a patient with mucormycosis. *J Neuroophthalmol.* 2021;41(3):354–6. doi:10.1097/WNO.0000000000001179.
 24. Mathur S, Karimi A, Mafee MF. Acute optic nerve infarction demonstrated by diffusion-weighted imaging in a case of rhinocerebral mucormycosis. *AJNR Am J Neuroradiol.* 2007;28(3):489–90.
 25. Hosseini SM, Borghei P. Rhinocerebral mucormycosis: pathways of spread. *Eur Arch Oto-Rhino-Laryngology Head Neck.* 2005;262(11):932–8.
 26. Maurya RP. Indications for orbital exenteration in COVID-19 associated Rhino-orbit-cerebral Mucormycosis. *IP Int J Ocul Oncol Oculoplast.* 2021;7(2):105–8.
 27. Sarkar S, Gokhale T, Kaliaperumal S, Singh R, Begam RB, Deb AK, et al. Exudative retinal detachment in COVID-19 - associated rhino-orbital mucormycosis – A rare clinical finding. *Indian J Ophthalmol.* 2021;69(9):2535–7. doi:10.4103/ijo.IJO_1729_21.
 28. Vidhya E. Case report of rhino-orbital-cerebral mucormycosis secondary to periodontal abscess presenting as exudative retinal detachment. *TNOA J Ophthalmic Sci Res.* 2021;59(3):286–8. doi:10.4103/tjosr.tjosr_36_21.
 29. Kim IT, Shim JY, Jung BY. Serous retinal detachment in a patient with rhino-orbital mucormycosis. *Jpn J Ophthalmol.* 2001;45(3):301–4.

Author biography

Zainu Shams, Senior Resident

C Shwetha Kumari, Assistant Professor

Malvika S B Mutt, Junior Resident

Bharathi N, Associate Professor

Madhura M Khanapur, Senior Specialist

Cite this article: Shams Z, Kumari CS, Mutt MSB, Bharathi N, Khanapur MM. Posterior segment findings in post-Covid mucormycosis: A cross-sectional study. *IP Int J Ocul Oncol Oculoplasty* 2022;8(2):136-140.