

Content available at: <https://www.ipinnovative.com/open-access-journals>

IP International Journal of Ocular Oncology and Oculoplasty

Journal homepage: <https://ijooo.org/>

Review Article

Ocular surface squamous neoplasia: An overview

Vibha Singh¹, Rajendra Prakash Maurya^{1,*}, Kajal Pal¹, Shivangi Singh²,
Virendra P Singh¹, Kartika Anand³

¹Regional Institute of Ophthalmology, Institute of Medical Sciences, Banaras Hindu University, Varanasi, Uttar Pradesh, India

²Motilal Nehru Medical College, Prayagraj, Uttar Pradesh, India

³Dept. of Ophthalmology, Rohilkhand Medical College and Hospital, Bareilly, Uttar Pradesh, India



ARTICLE INFO

Article history:

Received 25-04-2022

Accepted 03-05-2022

Available online 09-05-2022

Keywords:

Ocular surface squamous neoplasia

Xeroderma pigmentosum

Histopathological

ABSTRACT

Ocular surface squamous neoplasia (OSSN) is a diverse range of neoplasm arising from squamous epithelium of conjunctiva, limbus and cornea. OSSN is considered as a low grade malignancy but may be locally invasive and require exenteration. It has relatively high recurrence rate. It has multifactorial etiology and specific pathogenesis of lesion has yet to be attributed. Histopathology with immunohistochemistry is a gold standard diagnostic tool.

This mini review highlights the pathogenesis, risk factors, various clinical manifestations, latest diagnostic tools and recent development in treatment of OSSN.

This is an Open Access (OA) journal, and articles are distributed under the terms of the [Creative Commons Attribution-NonCommercial-ShareAlike 4.0 License](https://creativecommons.org/licenses/by-nc-sa/4.0/), which allows others to remix, tweak, and build upon the work non-commercially, as long as appropriate credit is given and the new creations are licensed under the identical terms.

For reprints contact: reprint@ipinnovative.com

1. Introduction

Ocular surface squamous neoplasia (OSSN) term encompasses pre-cancerous and cancerous epithelial lesions of the conjunctiva and cornea. It incorporates wide range of pathological changes from Dysplasia, Carcinoma in-situ (CIS) to Invasive SCC.¹ When OSSN is not treated it can lead to blindness and even death. Most common non-pigmented malignancy of the ocular surface is OSSN.² This disease presents in two different pattern based on age of presentation, risk factor and race- an older white male population with UVB as the primary risk and other group comprising young female population where HPV and HIV-AIDS are more prevalent.³ The gold standard treatment for the disease is surgical excision but because of the high recurrence rate of tumour after surgical excision, recently it has been seen that conservative medical approach is being encouraged and progressively this modality of

treatment is being considered in the recent years.⁴ It was for the first time described by Von Graefe dating back in 1860.⁵ Surprisingly OSSN usually affects one eye.⁶

2. Epidemiology

The incidence of OSSN varies region wise with this being the most common non-pigmented malignancy of the ocular surface,^{2,7–10} with an incidence ranging from 0.03-1.9 per 100,000/year in the Caucasian population,^{7,8,9} to 3-3.4 per 100,000/year in African ethnicity populations.^{7,11,12} The high prevalence rate of HIV in Sub-Saharan Africa explains the difference between the two incidence rates, as HIV is the one of the most important risk factor for OSSN.¹¹ Males, Caucasians and residents of lower latitudes (closer than 30 latitude to the equator) are at highest risk of getting OSSN.¹³ Mean age of presentation of this tumour is reported to be 56 years with an age range of 4-96 years.^{14,15} For population residing at lower altitudes, among patients suffering from Xeroderma pigmentosum and HIV infection,

* Corresponding author.

E-mail address: mauryarp_bhu@yahoo.com (R. P. Maurya).

the age of presentation is at an earlier age.^{13,15-17}

3. Predisposing Factors

The development of OSSN is associated with exposure to the sun-light, HIV-AIDS infection and HPV type 16 infection. Besides the above mentioned factors, many other factors predispose to the development of OSSN which includes :exposure to cigarette smoke, deficiency of vitamin-A, injury to ocular surface , chronic ocular inflammation (e.g. allergic conjunctivitis), petroleum chemicals exposure, chronic viral infections such as hepatitis B and C and immunodeficient states.^{18,19} Other than HIV-AIDS, Immune dysregulation syndromes like iatrogenic immunosuppression post organ transplantation, non-Hodgkin's lymphoma, asthma/eczema/atopic disease, ocular cicatricial pemphigoid, xeroderma pigmentosum, and papillon-Lefevre syndrome can also predispose to OSSN.⁷

3.1. Role of UV-B rays

The degree of risk depends on the type of UV rays, the intensity of exposure, total cumulative exposure and the quantity of the light-absorbing "protective mantle" of melanin.¹⁵ The mutagenic effect of UVB is related to a combination of UVB induced DNA damage, primarily in the p53 tumour suppressor gene, and impaired DNA repair mechanisms^{6,19,20}. Following ultraviolet B radiation exposure, there is alteration in the pattern of MMP-1 and MMP-3 which is implicated in the pathogenesis of OSSN. A study published in 2008 showed the role of matrix metalloproteinases (MMP) and tissue inhibitors of matrix metalloproteinases in the changed expression pattern of above implicating factors namely MMP-1 and MMP-3.¹⁵ Xeroderma pigmentosum (XP) is an autosomal recessive disorder with defective DNA repair mechanism which also predisposes to OSSN and other mucosal and cutaneous cancers with aggressive clinical presentation at a younger age. OSSN has been reported as early as 3 years of age in a patient of XP.^{20,21}

3.2. Human papilloma virus and OSSN

In recent studies, association between human papilloma virus -16 and conjunctival neoplasia has been seen.^{14,22} HPV alone can't act in causing the development of OSSN but in synergism with other predisposing factors like UV-B radiation as mentioned above¹⁴ UV-B radiation related DNA damage which includes the formation of pyrimidine dimers(CC>TT) and epigenetic changes in the p16 gene promoter act synergistically with HPV-16 induced inhibition of tumour suppressor gene retinoblastoma ultimately leading to neoplastic transformation of the cell lineage.^{7,23}

3.3. HIV and OSSN

There is eight fold increased incidence of OSSN in patients of HIV and the risk is mainly seen in the first two years of getting AIDS.^{24,25} Screening for HIV should always be done in cases of atypical presentation of OSSN or endemic regions as this can be initial presentation of 50-86% of HIV in endemic regions.^{7,26} HIV infection has been associated with younger age at presentation of OSSN, female or no gender predilection, more severe course, bilateralism, worse prognosis, and increased risk of recurrence.^{7,27-29} In patients of HIV, the clinical presentation of OSSN is more aggressive as compared to those without HIV and therefore the management often requires enucleation or exenteration as well.²⁹

4. Pathophysiology of OSSN

LIMBAL TRANSITION ZONE/STEM CELL THEORY: Stem cells present in the basal epithelial layer of nasal limbus are considered as precursor cells for OSSN. Actually nasal limbus receives the highest intensity of UV-B radiation based on the strategic anatomy. OSSN present limbally arises from basal layer and then spreads to ocular surface progressively and in advance stages invades the basement membrane.³⁰ Nasal side of limbus contains highest concentration of stem cells and are likely originators of neoplasia. The tumorigenesis occurs in the background of UV-B radiation exposure as DNA damage occurs due to it. More over, the immunosuppression induced by HIV and xerophthalmia, impairs immune surveillance of tumors, in this way it promotes the survival of aberrant cells. The telomerase reactivation promotes increase in size of tumour and its metastasis. The cellular matrix is also destroyed by proliferation of activated vascular endothelial growth factors and metalloproteinases.^{6,31}

5. Clinical Presentation

Clinically OSSN presents in varied way. Mostly it presents as a sessile, fleshy, elevated lesion adjacent to the limbus in the inter-palpebral region.¹⁵ Most of the patients come in the out patient department with complaint of the fleshy mass or a round lump in the eye, increased irritation, redness, foreign body sensation, itching in the eyes and reduced visual acuity due to astigmatism or visual axis involvement.^{31,32} The conjunctival OSSN is present in the bulbar conjunctiva, which gradually progresses to involve the limbus and cornea. Bilateral or multifocal mass can be a rare presentation of OSSN. They most commonly bestride the nasal or temporal limbus between the palpebral fissures.³³ Classification of OSSN can be done based into nodular, nodulo-ulcerative, gelatinous, leukoplakic, placoid, or papillary forms.³⁴ Diagnosing infiltrative variants of OSSN can be challenging as it simulates necrotizing scleritis.³⁵ At times pigmented variants of OSSN can

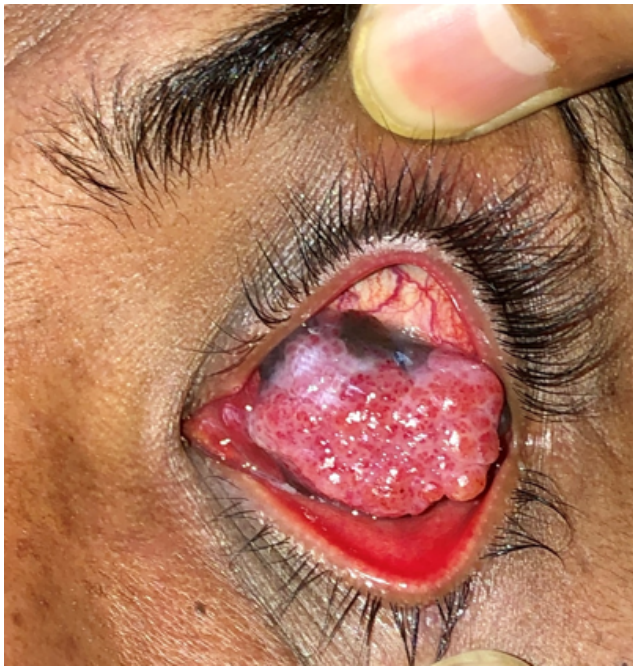

Fig. 1: Nodular OSSN generally indicating Squamous cell carcinoma.

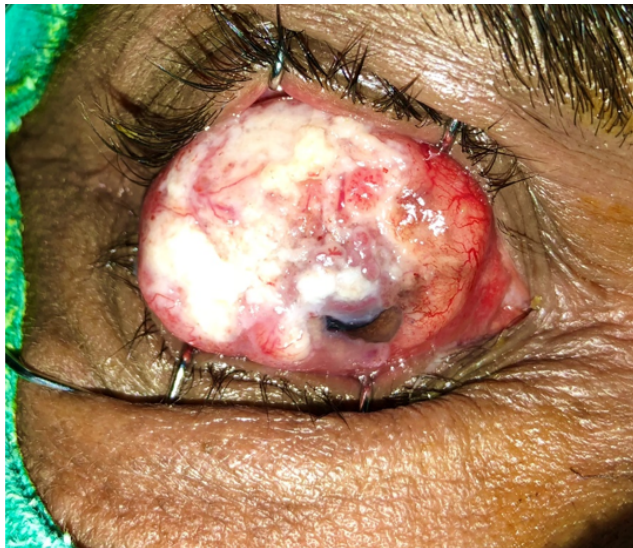

Fig. 2: Giant OSSN extending into orbit.

pose difficulty in differentiating it from conjunctival melanoma.³⁶

Pannus, actinic disease, vitamin A deficiency, benign intraepithelial dyskeratosis, pinguecula, pyogenic granuloma, keratoacanthoma, pseudo epitheliomatous hyperplasia, malignant melanoma, and nevi, especially in patients with racial melanosis are the differential diagnosis of OSSN.⁵

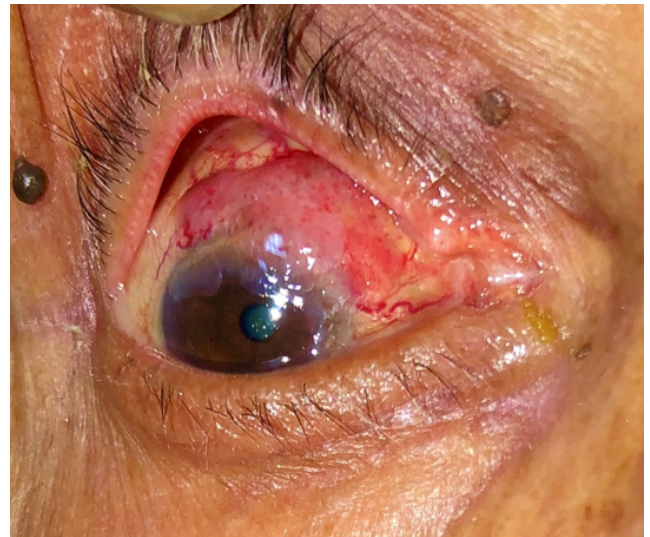

Fig. 3: OSSN is seen extending more than 180 degrees around the limbus.

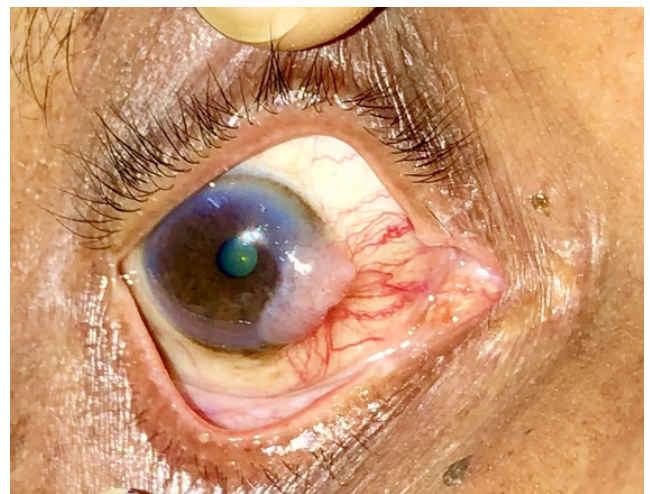


Fig. 4: Gelatinous leukoplakic ocular surface squamous neoplasia with keratin deposits and feeder vessels.

Although aggressive variants of OSSN are uncommon but deserve special mention. Mucoepidermoid carcinoma which is seen in elderly age groups has a propensity for intraocular and orbital invasion. Mucin producing cells give it a yellow cystic appearance of lesion is given by mucin producing cells. Spindle cell carcinoma is an aggressive variant with propensity to metastasize. These are generally managed surgically with wider margins.¹⁴ Changes like a diffuse or multifocal configuration, brown pigmentation, median basal diameter of > 10 mm, and thickness of > 1 mm are suggestive of malignant transformation.^{7,37,38}

6. Diagnosis

Histopathological examination after incisional or excisional biopsy is the gold standard for diagnosis of OSSN after it is clinically suspected based on the appearance of the lesion.¹⁵

Besides histopathological examination, additionally other methods are described for diagnosing OSSN which include: impression cytology (IC), anterior segment optical coherence tomography (AS-OCT), confocal microscopy, ultrasound biomicroscopy (UBM) and vital dyes.^{3,39} With course of time as the management of OSSN is proceeding from surgical approach to more conservative medical management from topical chemo to immunotherapy, there is increasing tendency of going towards more non-invasive techniques for diagnosing OSSN.^{1,15,40,41}

6.1. Diagnostic vital dyes

The various dyes used to assist OSSN diagnosis are rose bengal, toluidine blue, and methylene blue. These vital have a good negative predictive value and easily exclude the diagnosis of OSSN. Their main application is during surgery to localize lesion and margins for excision.³¹

6.1.1. Toluidine blue

Because of the high affinity, toluidine blue is a metachromatic acidophilic dye which stain nuclear material (high density). The OSSN tumour mass having high mitotic figures and less intercellular adhesions also stain well with toluidine blue. Gichuhi et al., in their analysis for OSSN, showed that 0.05% toluidine blue is safer, no toxic effects and produces only little discomfort with topical application. The study showed a high sensitivity and low specificity of 92% and 31% respectively for toluidine blue in diagnosing OSSN.⁴²

6.1.2. Methylene blue

This is an acidophilic dye which helps in diagnosis of OSSN. This dye can penetrate cell walls and easily binds to nucleic acid. This dye has a high affinity for the tumour cells of OSSN with a rapid metabolic rate. Steffen et al., in their prospective analysis of 75 patients, showed that this dye has 97% sensitivity and 50% specificity for OSSN lesions.⁴³

6.1.3. Rose Bengal

Unhealthy and dead devitalized epithelial cells are stained bright pink by Rose Bengal dye. It stains OSSN tissues and helps in differentiating the abnormal epithelium. The other pathological lesions having abnormal epithelium also get stained. Hence this has high sensitivity and low specificity.⁴⁴

6.2. Exfoliative and Impression cytology

Larmande and Timsit studied the use of exfoliative cytology for the very first time in 1954.⁴⁵ Malignant cells tend to

have a low cell to cell adherence and also desquamate when present on the mucosal surface therefore exfoliative cytology is performed by using cytobrush and in contrast to this impression cytology is performed by using cellulose acetate paper (CAP) and is equally simple and inexpensive as is exfoliative cytology.⁴⁶ The main advantage of performing cytology by such methods is that the cell-to-cell relationship is maintained. The most commonly used non-invasive method for performing a conjunctival biopsy in cases of suspected OSSN is CAP. There is 80% correlation between impression cytology, histopathology samples, and suspected diagnosis from the specimens obtained by incisional biopsy with CAP specimen. Another method using a biopore membrane is also used for performing impression cytology. The advantage of this method is that the specimens can be stored for several days while maintaining the cell-to-cell relationship.⁴⁷ Major limitations of this methodology is that it requires experience of both the practitioner performing the investigation and of the cytologist reading the specimen because of which the applicability is limited.⁴⁸ Moreover, invasive disease still can't be identified definitely.⁴⁹

6.3. In vivo Confocal microscopy

IVCM is a non-invasive technique and allows en face images of the ocular surface. This technique utilises a source and detector of same focal length using a slit or point source light and a point or slit detector; the source and detector use conjugate pinholes in order to enhance optical resolution by reducing interference from light contamination. Impressive resolution, down to the cellular level, is obtained, though only 1 plane can be imaged at one point of time. IVCM is safe and non-invasive and can be easily performed in clinics thus the information is immediately available.^{50,51} Confocal microscopy is helpful in diagnosing OSSN early along with the follow-up and estimating the recurrence of OSSN. It is also helpful in assessing the treatment response of various topical chemotherapeutic agents in corneal and conjunctival OSSN.³¹ In small studies of IVCM, it has been shown that the technique has good correlation to histology; however, as these were all correlation studies, the sensitivity and positive predictive value of this technique is not yet known.⁵²⁻⁵⁴ However, study conducted by Xu et al concluded that IVCM is useful for predicting the grade of dysplasia and the extent to which epithelium is involved as well the stromal invasion.⁵⁴ Although IVCM can be a useful additional tool to histology, these findings indicate that it cannot replace biopsy for diagnosing OSSN. Limitations of this technique include the requirement for operator expertise in capturing and the interpretation of images, and decreased visualization in very thick/keratinized lesions that degrade the optical properties of the normally transparent conjunctival and corneal epithelium.^{53,54}

6.4. Anterior Segment Optical coherence tomography

Izatt et al. in 1994 introduced anterior segment optical coherence tomography (AS-OCT) for the first time, is a noncontact and non-invasive imaging technique that captures high resolution cross-sectional images of the anterior segment. High resolution OCT (HR-OCT) is capable of providing axial resolution of 5–10 μm , while ultra-high resolution OCT (UHR-OCT) can provide axial resolution better than 5 μm .^{55,56} Vajzovic et al reported that UHR-OCT of an OSSN lesion showed epithelial thickening and increased reflectivity of the epithelium with an obvious delineation from tumor to nonaffected tissue.^{55,57} Several studies have further shown that thickened hyperreflective epithelium, abrupt transition from normal to abnormal epithelium, and a sharp plane of cleavage between the lesion and underlying tissue were all features that were seen in UHR-OCT images and histopathologic specimens of OSSN lesions.⁵⁸⁻⁶¹ Normal epithelium overlying subepithelial lesion rules out OSSN.⁶⁰ UHR-OCT can also be used to monitor the resolution of disease and detection of residual subclinical disease. Lesions that were treated successfully with topical agents, post-treatment UHR-OCT have shown normalisation of epithelial architecture at the site of the treated lesions. However, lesions that are resistant to medical treatment, UHR-OCT showed persistently thickened epithelium with retained abrupt transition between normal and diseased epithelium.^{56,58} In this way, it prevents the premature termination of medical therapy.⁶² One study has reported the use of AS-OCT in detection of residual disease after surgical excision in a case of corneal intraepithelial neoplasia and this finding thus allowed for supplemental medical therapy until resolution of disease.⁶³ UHR-OCT can also play role in ruling out OSSN in eyes with clinically indeterminate lesions.⁶²

6.5. Ultrasound biomicroscopy

Pavlin et al. in 1990 developed Ultrasound biomicroscopy (UBM) for the first time, provides cross-sectional visualization of the anterior segment in an intact globe at microscopic resolution.⁶⁴ In the 50 MHz mode produces images to a depth of 5 to 6 mm at a resolution of 25 microns.⁶⁵ Anterior segment tumors are widely imaged by UBM these days although limitations exist. There is requirement of an eyebath in the reclined position and a familiarity of technician with its use to obtain the best images.⁵⁵ Studies on the use of UBM in diagnosing OSSN have shown that UBM is most useful in assessing intraocular tumor extension and metastasis.^{66,67}

6.6. Histopathology

Histopathological evaluation is the gold standard for diagnosis of OSSN after an incisional or excisional biopsy of the lesion.¹⁵ Microscopic examination of the

excised lesion with safe margins shows that there is an abrupt transition of the epithelial lesion from the adjacent uninvolved conjunctiva. An increase in the size of nuclei, irregular nuclear membrane, hyperchromasia and fine to coarse chromatin are seen cytologically in the dysplasia cells. Up gradation or down gradation of severity of dysplasia can occur based on the degree of nuclear atypia irrespective of level of epithelial thickness involvement. Dysplasia are classified into varying grades based on the level of involved epithelial thickness. When lower one third and lower two thirds of the epithelium shows abnormal transformation the lesion is termed as mild and moderate dysplasia respectively. Severe dysplasia is termed when the abnormality involves more than 2/3rds of the epithelial thickness, however surface maturation is preserved. Involvement of full thickness of epithelium, however with retained integrity of epithelial basement membrane is termed as carcinoma in situ. Cytopathic effect are seen in some cells in lesions associated with HPV infections which results in the formation of a halo cell known as the Koilocyte.^{15,68} Actinic keratosis, pterygium, pinguecula and actinic granuloma can mimic OSSN but can be easily differentiated from OSSN by studying the morphology

7. Classification

Tumor staging is assessed using the TNM (Tumor, Node, Metastasis) definitions, as stated in the American Joint Committee on Cancer (AJCC) recommendations, T describes features of the primary tumor, N describes the involvement of the regional nodes, and M describes the spread of distant metastasis. The 8th edition of the AJCC classification has been recently diagnosed, and the definitions for T1 and T2 differ from those in the 7th edition. In the 7th edition the definition of T1 and T2 was based solely on the size of tumour, whereas in the 8th edition T classification is based both on the size of tumour (≤ 5 or $> 5\text{mm}$) and the involvements of the basement membrane and adjacent structures, namely the fornix, the plica semilunaris, the caruncle, the eyelid lamellae, the orbit, the sinuses bone, and the brain.⁷⁰

8. Management

OSSN management can be divided into two main groups, medical and surgical. There has been a move in recent years to medical therapy as this removes the risk associated with anaesthesia and surgery.^{69,70}

8.1. Medical Management

With the advent of less invasive diagnostic modalities such as AS-OCT, confocal microscopy and impression cytology, there has been paradigm shift from surgical treatment to less invasive management options. The main limitation of

Table 1:

Tumor (T) category	Tumor criteria	Comments
TX	Primary tumor cannot be assessed	
TO	No evidence of primary tumor	
Tis	carcinoma in situ	Includes mild, moderate, and severe dysplasia and carcinoma in situ. collectively referred to as conjunctiva intraepithelial neoplastic
T1	Tumor (\leq mm in greatest dimension) invades through the conjunctival Basement membrane without invasion of adjacent structures	TI stage and beyond represent invasive squamous cell carcinoma
T2	Tumor (>5 mm in greatest dimension) invades through the conjunctival basement membrane without invasion of adjacent structures	Excludes tumors that invade cornea, intraocular structures forniceal conjunctiva, palpebral conjunctiva, tarsal conjunctiva, lacrimal punctum, canaliculi, plica, caruncle, anterior or posterior eyelid lamella, or eyelid margin
T3	Tumor invades adjacent structures (excluding the orbit)	Includes involvement of adjacent structures excluded in T2
T4	Tumor invades the orbit with or without further extension	
T4a	Tumor invades orbital soft tissues without bone invasion	
T4b	Tumor invades bone	
T4c	Tumor invades adjacent paranasal sinuses	
T4d	Tumor invades brain	
Node (N) category	Node criteria	
NX	Regional lymph nodes cannot be assessed	
NO	No regional lymph node metastasis	
N1	Regional lymph node metastasis	
Metastasis (M) category	Metastasis criteria	
MO	No distant metastasis	
M1	Distant metastasis	

AJCG 8 recommends histopathology for accurate staging. It also recommends Ki 67 growth fraction reported as percentage of positive cell by immunohistochemistry for data collection. Histologic grades include GX: Grade cannot be assessed, G1: Well differentiated, G2: Moderately differentiated, G3: Poorly differentiated, G4: Undifferentiated. AJCC: American Joint Committee on Cancer

Source: American Joint Committee on Cancer Eighth Edition Tumor Node Metastasis Classification for Conjunctival Squamous Cell Carcinoma

these therapies is the prolongation of therapy and need for compliance.

8.1.1. Mitomycin-C

Mitomycin-C is an alkylating agent which has got antineoplastic/antibiotic properties. Its mechanism of action is by binding to DNA during DNA synthesis and inhibiting its synthesis and function.^{71–73} It is toxic to both proliferating and non-proliferating cells by causing apoptosis and inhibition of fibroblast migration.^{74,75} The main advantage of MMC is that it can be used as a primary treatment agent for OSSN along with its usefulness intraoperatively, as an adjuvant to excisional biopsy, and post-operatively in patients with positive conjunctival or deep margins.^{76–79} MMC is compounded into a concentration between 0.02 and 0.04% when used as primary treatment for OSSN.^{76–80} The regimen of MMC is 4 times daily for 1 week followed by 2 to 3 weeks of no treatment. The length of the period of no treatment depends on how long it takes the eye to recover from the 1 week of treatment. Other regimens include 1 week

on/1 week off, 2 weeks on with variable duration between cycles and 3 weeks of continuous therapy.^{77,80,81} MMC is also used intraoperatively during tumor excision, usually soaked on a sponge at a concentration of 0.02% and applied to the margins of conjunctiva for a duration of 1~3 min.^{78,82,83} Postoperatively, in the patients having positive margins for neoplasia, MMC drops is used after the surface heals. The treatment regimen during post-operative use is similar to that of primary use.⁸⁴ Pain and epitheliopathy, allergic conjunctivitis, hyperaemia, ectropion and punctal stenosis are the main side effects of using mitomycin-C.^{85,86} Because of the high risk of punctal stenosis, punctal plugs should be inserted before initiating topical MMC.⁸⁶

8.1.2. 5-Fluorouracil

5-FU is a pyrimidine analogue that blocks thymidine synthase leading to inhibition of DNA formation. This leads to a reduction in RNA ultimately causing poor cell growth and cell death.⁸⁷ It is well-tolerated and effective agent for primary treatment of OSSN as well as an adjuvant after surgical excision.^{88–90} Most commonly used regimen for

the primary treatment of OSSN is in a cyclical pattern four times daily for a week followed by a 3 week holiday and is compounded as a 1% solution.^{88,90} This pattern makes one cycle, which is repeated on average of 4 to 6 cycles based on clinical response (noted by both slit lamp examination and HR-OCT imaging). Alternate regimens have been developed and reported in the literature including continuous administration of 5-FU 3 to 4 times a day for 4 weeks or administration of 5-FU for only 2 to 4 days with a 30 to 45 day drug-holiday.⁹¹⁻⁹⁶ On comparing side effects of topical 5-FU with IFN α -2b, 5-FU has got more side effects, most commonly pain and redness at the instillation side, but 5-FU has lesser side effects than MMC. Eyelid swelling, conjunctival congestion, filamentary keratitis and rarely superficial stromal melting are other side effects of 5 FU.^{90,93} Topical corticosteroids in conjunction with preservative free artificial tears are used to reduce the symptoms. Punctal or canalicular stenosis is reported to occur with systemic 5-FU treatment but not when used topically.⁷⁰

8.1.3. Interferon alpha 2b (IFN α -2b)

Interferon α -2b (IFN α -2b) is a cytokine which contains 165 amino acid residues with immunomodulatory effects. Intralesional injections of IFN α -2b increases the production of IL-2 and IFN- γ mRNA by the immune system and reduces the production of IL-10. These cytokines help in the recognising and targeting of neoplastic cells.⁹⁷ IFN α -2b can be used as topical eye drops, sub conjunctival injections, or a combination of both when used for treatment of OSSN.⁹⁷⁻¹⁰¹ IFN α -2b topically and intralesionally can be used as primary or adjuvant therapies. Topically, the most frequently prescribed regimen of IFN α -2b is dose being 1 million IU/ml four times a day without interruption until one or two more months after clinical resolution of the lesion. It usually takes about 4 months for the lesion to resolve clinically after treatment.^{97,100} Other doses, including 2 and 3 million IU/ml, have also been reported and are used in the same manner. One study showed similar efficacy between the 1 million IU/ml and 3 million IU/ml doses, without any statistically significant differences in clinical resolution and duration of treatment.¹⁰⁰ When used as a post-surgical adjuvant in individuals with positive margins, the regimen is topical IFN α -2b 1 million IU/ml administered four times daily for a duration of 2 months post-operatively.¹⁰² Subconjunctival IFN α -2b injections (3 million IU/0.5 ml) are given weekly until there is resolution of OSSN (typically requiring 4 to 5 injections to achieve clinical resolution).^{97,99,101} When used topically, IFN α -2b eye drops generally have minimal to no adverse effects however follicular conjunctivitis and hyperaemia have infrequently been reported along with formation of epithelial microcysts.¹⁰³ Flu-like syndrome that lasts for approximately 48h after administration of the injection is

the main adverse effect of sub conjunctival injection. 1g of oral acetaminophen is administered at the time of the injection to reduce the intensity of adverse effects and then as needed until symptoms resolve.^{70,97,99,104}

8.2. Surgical Management

Tumours that occupy four clock hours or less of the limbus, or have a basal diameter of 15 mm or less surgical excision remains the gold standard treatment.¹ The surgical approach follows the traditional “no touch” technique, which minimises seeding of the tumour during surgery, and recommends 3-4mm macroscopically clear margins. Limbal stem cell deficiency (LSCD), scarring, pyogenic granulomas, infection and damage to the sclera or retina from excessive cryotherapy are the main risk associated with surgical treatment. The major limitation of surgical treatment is that it only removes the macroscopically visible tumour. If the surgical margins are found to be positive on histology, adjuvant topical chemotherapy can be given to minimise recurrence.^{1,7,40,70}

8.3. Novel Therapies

8.3.1. Photodynamic therapy

Photodynamic therapy uses a combination of a photosensitising agent (verteporfin) and diode laser, used to produce oxygen free radicals that result in vascular occlusion that promotes tumour destruction in photodynamic therapy.¹⁰⁵ In one pilot study it has been observed to cause tumour resolution in 100% of cases that are smaller than the laser spot size of 5 mm, with no recurrence at one year.¹⁰⁶ Minor reversible side effects like chemosis, conjunctival haemorrhages and foreign body sensation are reported following photodynamic therapy .106. Major limitation in adoption of this as popular treatment modality is the high cost of the photosensitising agent and limited evidence in the literature.¹⁰⁵

8.3.2. Anti-VEGF

Anti-VEGF agents are monoclonal antibodies against the vascular endothelial growth factor (VEGF) interfering with the growth of blood vessels.¹⁰⁶ Subconjunctival anti-VEGF injections for OSSN have been described in several small case series, with resolution seen in up to 60% of cases.¹⁰⁷⁻¹⁰⁹ No significant adverse effects were reported in any of these study series.¹⁰⁷⁻¹⁰⁹

8.3.3. Cidofovir

Cidofovir is a monophosphate nucleotide analogue that has shown in vitro activity against a number of DNA viruses.¹¹⁰ A study series conducted in Australia has shown resolution of 83% cases which were treatment resistant when treated with topical Cidofovir 0.25% administered three times a day for 4-9 weeks.¹¹¹

8.3.4. EGFR inhibitors

A case series reported a significant response to systemic EGFR inhibitors in two patients of elderly age group with advanced orbital extension of OSSN.¹¹² Because of the high cost of these agents it has got limited accessibility and clinical use.

9. Prognosis

Overall, OSSN has a good/fair prognosis, with low mortality rate minimal tendency to metastasize; metastasis is often linked to regional or distant metastases or intracranial invasion.¹¹³ Factors associated with guarded prognosis and high recurrence rate following treatment include incompletely excised tumor margins, old age, deeper tissue penetration, corneal OSSN, and large tumors (greater than 2 mm). Recent surgical and medical treatment modalities have proved to be effective. Less than 2% lymph node metastasis and local recurrence rate of less than 5% has been reported. The invasive and mucocoeptidermoid carcinoma have got worst prognosis.¹¹⁴

10. Conflict of Interest

The authors declare that there are no conflicts of interest in this paper.

11. Source of Funding

None.

References

- Shields CL, Shields JA. Tumours of the conjunctiva and cornea. *Surv Ophthalmol*. 2004;49(1):3–24. doi:10.1016/j.survophthal.2003.10.008.
- Shields CL, Demirci H, Karatza E, Shields JA. Clinical survey of 1643 melanocytic and nonmelanocytic conjunctival tumors. *Ophthalmology*. 2004;111(9):1747–54.
- Hollhumer R, Williams S, Michelow P. Ocular surface squamous neoplasia: Population demographics, pathogenesis and risk factors. *Afr Vis Eye Health*. 2020;79(1). doi:10.4102/aveh.v79i1.553.
- Nanji AA, Moon CS, Galor A, Sein J, Oellers P, Karp CL, et al. Surgical versus medical treatment of ocular surface squamous neoplasia: a comparison of recurrences and complications. *Ophthalmology*. 2014;121(5):994–1000.
- Basti S, Macsai MS. Ocular surface squamous neoplasia: a review. *Cornea*. 2003;22(7):687–704.
- Gichuhi S, Ohnuma S, Sagoo MS, Burton MJ. Pathophysiology of ocular surface squamous neoplasia. *Exp Eye Res*. 2014;129:172–82. doi:10.1016/j.exer.2014.10.015.
- Cicinelli MV, Marchese A, Bandello F, Modorati G. Clinical Management of Ocular Surface Squamous Neoplasia: A Review of the Current Evidence. *Ophthalmol The*. 2018;7(2):247–62. doi:10.1007/s40123-018-0140-z.
- Lee GA, Hirst LW. Incidence of ocular surface epithelial dysplasia in metropolitan Brisbane. A 10-year survey. *Arch Ophthalmol*. 1992;110(4):525–7.
- Sun EC, Fears TR, Goedert JJ. Epidemiology of squamous cell conjunctival cancer. *Cancer Epidemiol Biomark Prev*. 1997;6(2):73–7.
- Ateenyi-Agaba C. TP53 mutations in squamous-cell carcinomas of the conjunctiva: evidence for UV-induced mutagenesis. *Mutagenesis*. 2004;19(5):399–401. doi:10.1093/mutage/geh048.
- Ateenyi-Agaba C. Conjunctival squamous-cell carcinoma associated with HIV infection in Kampala, Uganda. *Lancet*. 1995;345(8951):695–6.
- Gichuhi S, Sagoo MS, Weiss HA, Burton MJ. Epidemiology of ocular surface squamous neoplasia in Africa. *Trop Med Int Health*. 2013;18(12):1424–43.
- Newton R. A review of the aetiology of squamous cell carcinoma of the conjunctiva. *Br J Cancer*. 1996;74(10):1511–3.
- Lee GA, Hirst LW. Ocular surface squamous neoplasia. *Surv Ophthalmol*. 1995;39(6):429–50. doi:10.1016/s0039-6257(05)80054-2.
- Mittal R, Rath S, Vemuganti GK. Ocular surface squamous neoplasia - Review of etio-pathogenesis and an update on clinico-pathological diagnosis. *Saudi J Ophthalmol*. 2013;27(3):177–86. doi:10.1016/j.sjopt.2013.07.002.
- Ni C, Searl SS, Kriegstein HJ, Wu BF. Epibulbar carcinoma. *Int Ophthalmol Clin*. 1982;22:1–33.
- Hertle RW, Durso F, Metzler JP. Epibulbar squamous cell carcinomas in brothers with xeroderma pigmentosa. *J Pediatr Ophthalmol Strabismus*. 1991;28(6):350–3. doi:10.3928/0191-3913-19911101-15.
- Napora C, Cohen EJ, Genvert GI, Presson AC, Arentsen JJ, Eagle RC, et al. Factors associated with conjunctival intraepithelial neoplasia: a case control study. *Ophthalmic Surg*. 1990;21(1):27–30.
- Gichuhi S, Macharia E, Kabiru J, Zindamoyen AM, Rono H, Ollando E, et al. Risk factors for ocular surface squamous neoplasia in Kenya: a case-control study. *Trop Med Int Health*. 2016;21(12):1522–30.
- Jacyk WK. Xeroderma pigmentosum in black South Africans. *Int J Dermatol*. 1999;38(7):511–4. doi:10.1046/j.1365-4362.1999.00724.x.
- Ng J, Coroneo MT, Wakefield D, Girolamo ND. Ultraviolet radiation and the role of matrix metalloproteinases in the pathogenesis of ocular surface squamous neoplasia. *Invest Ophthalmol Vis Sci*. 2008;49:5295–306. doi:10.1167/iovs.08-1988.
- McDonnell JM, McDonnell PJ, Sun YY. Human papillomavirus DNA in tissues and ocular surface swabs of patients with conjunctival epithelial neoplasia. *Invest Ophthalmol Vis Sci*. 1992;33(1):184–9.
- Chauhan S, Sen S, Sharma A, Kashyap S, Tandon R, Bajaj MS, et al. p16(INK4a) overexpression as a predictor of survival in ocular surface squamous neoplasia. *Br J Ophthalmol*. 2018;102(6):840–7.
- Carreira H, Coutinho F, Carrilho C, Lunet N. HIV and HPV infections and ocular surface squamous neoplasia: systematic review and meta-analysis. *Br J Cancer*. 2013;109(7):1981–8.
- Goedert JJ, Cote TR. Conjunctival malignant disease with AIDS in USA. *Lancet*. 1995;346(8969):257–8.
- Karp CL, Scott IU, Chang TS, Pflugfelder SC. Conjunctival intraepithelial neoplasia. A possible marker for human immunodeficiency virus infection? *Arch Ophthalmol*. 1996;114(3):257–61.
- Steele KT, Steenhoff AP, Bisson GP, Nkomazana O. Ocular surface squamous neoplasia among HIV-infected patients in Botswana. *S Afr Med J*. 2015;105(5):379–83.
- Masanganise R, Mukome A, Dari J, Makunike-Mutasa R. Bilateral HIV related ocular surface squamous neoplasia: a paradigm shift. *Cent Afr J Med*. 2010;56(5-8):23–6.
- Shields CL, Ramasubramanian A, Mellen PL, Shields JA. Conjunctival squamous cell carcinoma arising in immunosuppressed patients (organ transplant, human immunodeficiency virus infection). *Ophthalmology*. 2011;118(11):2133–7.
- Gichuhi S, Ohnuma S, Sagoo MS, Burton MJ. Pathophysiology of ocular surface squamous neoplasia. *Exp Eye Res*. 2014;129:172–82. doi:10.1016/j.exer.2014.10.015.
- Gurnani B, Kaur K. Ocular Surface Squamous Neoplasia. In StatPearls. . StatPearls Publishing; 2021.
- Kapoor AG, Vempuluru VS, Laghimshetty S, Roy A, Sharma S, Mishra DK, et al. Ocular Surface Squamous Neoplasia With Coexistent Microbial Keratitis: Incidence, Risk Factors, Clinical

- Features, Microbiological Profile, and Treatment Outcome. *Cornea*. 2022;41(3):294–303. doi:10.1097/ICO.0000000000002809.
33. Lee GA, Hirst LW. Ocular surface squamous neoplasia. *Survey Ophthalmol*. 1995;39(6):429–50. doi:10.1016/S0039-6257(05)80054-2.
 34. Kaliki S, Freitag SK, Chodosh J. Nodulo-ulcerative ocular surface squamous neoplasia in 6 patients: a rare presentation. *Cornea*. 2017;36(3):322–6.
 35. Rath S, Honavar SG, Naik MN, Gupta R, Reddy VA, Vemuganti GK. Evisceration in unsuspected intraocular tumors. *Arch Ophthalmol*. 2010;128(3):372–9.
 36. Shields CL, Manchandia A, Subbiah R, Jr RE, Shields JA. Pigmented squamous cell carcinoma in situ of the conjunctiva in 5 cases. *Ophthalmology*. 2008;115(10):1673–8. doi:10.1016/j.ophtha.2008.01.020.
 37. Kao AA, Galor A, Karp CL, Abdelaziz A, Feuer WJ, Dubovy SR, et al. Clinicopathologic correlation of ocular surface squamous neoplasms at. *Ophthalmology*. 2001;119(9):1773–6.
 38. Shields CL, Alset AE, Boal NS. Comparative analysis of benign versus malignant counterparts. The 2016 James D. Allen Lecture. *Am J Ophthalmol*. 2017;173:106–33. doi:10.1016/j.ajo.2016.09.034.
 39. Steffen J, Rice J, Lecuona K, Carrara H. Identification of ocular surface squamous neoplasia by in vivo staining with methylene blue. *Br J Ophthalmol*. 2014;98(1):13–5.
 40. Shields CL, Chien JL, Surakiatchanakul T, Sioufi K, Lally SE, Shields JA, et al. Conjunctival Tumors: Review of Clinical Features, Risks, Biomarkers, and Outcomes—The 2017 J. Donald M. Gass Lecture. *Asia Pac J Ophthalmol (Phila)*. 2017;6(2):109–20. doi:10.22608/APO.201710.
 41. Thomas BJ, Galor A, Nanji AA, Sayyad FE, Wang J, Dubovy SR, et al. Ultra high-resolution anterior segment optical coherence tomography in the diagnosis and management of ocular surface squamous neoplasia. *Ocul Surf*. 2014;12(1):46–58. doi:10.1016/j.jtos.2013.11.001.
 42. Gichuhi S, Macharia E, Kabiru J, Zindamoyen AM, Rono H, Ollando E, et al. Toluidine Blue 0.05% Vital Staining for the Diagnosis of Ocular Surface Squamous Neoplasia in Kenya. *JAMA Ophthalmol*. 2015;133(11):1314–21.
 43. Steffen J, Rice J, Lecuona K, Carrara H. Identification of ocular surface squamous neoplasia by in vivo staining with methylene blue. *Br J Ophthalmol*. 2014;98(1):13–5.
 44. Nanji AA, Mercado C, Galor A, Dubovy S, Karp CL. Updates in Ocular Surface Tumor Diagnostics. *Int Ophthalmol Clin*. 2017;57(3):47–62.
 45. Larmande A, Timsit E. L'interet du cyto-diagnostic en ophtalmologie; communication preliminaire a propos de neuf cas de tumeurs du limbe sclerocorneen. *Bull Soc ophthalmol Fr*. 1954;19:415–9.
 46. Nolan GR, Hirst LW, Bancroft BJ. The cytomorphology of ocular surface squamous neoplasia by using impression cytology. *Cancer*. 2001;93(1):60–7.
 47. Doughty MJ. On the Variability in Goblet Cell Density in Human Bulbar Conjunctival Samples Collected by Impression Cytology with Millicell-CM Biopore Membrane Units. *Curr Eye Res*. 2016;41(11):1393–9.
 48. Grossniklaus HE, Stulting RD, Gansler T. Aspiration cytology of the conjunctival surface. *Acta Cytol*. 2003;47(2):239–46. doi:10.1159/000326510.
 49. Kheirkhah A, Mahbod M, Farzbod F. Repeated applications of impression cytology to increase sensitivity for diagnosis of conjunctival intraepithelial neoplasia. *Br J Ophthalmol*. 2012;96(2):229–33. doi:10.1136/bjo.2010.201103.
 50. Nanji AA, Mercado C, Galor A, Dubovy S, Karp CL. Updates in Ocular Surface Tumor Diagnostics. *Int Ophthalmol Clin*. 2017;57(3):47–62. doi:10.1097/IIO.0000000000000174.
 51. Chiou AG, Kaufman SC, Kaufman HE. Clinical corneal confocal microscopy. *Surv Ophthalmol*. 2006;51(5):482–500. doi:10.1016/j.survophthal.2006.06.010.
 52. Alomar TS, Nubile M, Lowe J. Corneal intraepithelial neoplasia: in vivo confocal microscopic study with histopathologic correlation. *Am J Ophthalmol*. 2011;151(2):238–47. doi:10.1016/j.ajo.2010.08.035.
 53. Parrozzani R, Lazzarini D, Dario A. In vivo confocal microscopy of ocular surface squamous neoplasia. *Eye*. 2011;25(4):455–60.
 54. Xu Y, Zhou Z, Xu Y, Wang M, Liu F, Qu H, et al. The clinical value of in vivo confocal microscopy for diagnosis of ocular surface squamous neoplasia. *Eye*. 2012;26(6):781–7. doi:10.1038/eye.2012.15.
 55. Ong SS, Vora GK, Gupta PK. Anterior Segment Imaging in Ocular Surface Squamous Neoplasia. *J Ophthalmol*. 2016;doi:10.1155/2016/5435092.
 56. Thomas BJ, Galor A, Nanji AA. Ultra highresolution anterior segment optical coherence tomography in the diagnosis and management of ocular surface squamous neoplasia. *Ocular Surf*. 2014;12(1):46–58.
 57. Vajzovic LM, Karp CL, Haft P. Ultra high-resolution anterior segment optical coherence tomography in the evaluation of anterior corneal dystrophies and degenerations. *Ophthalmology*. 2011;118(7):1291–6.
 58. Shousha MA, Karp CL, Perez VL. Diagnosis and management of conjunctival and corneal intraepithelial neoplasia using ultra high-resolution optical coherence tomography. *Ophthalmology*. 2011;118(8):1531–7.
 59. Kieval JZ, Karp CL, Shousha MA. Ultra-high resolution optical coherence tomography for differentiation of ocular surface squamous neoplasia and pterygia. *Ophthalmology*. 2012;119(3):481–6.
 60. Shousha MA, Karp CL, Canto AP. Diagnosis of ocular surface lesions using ultra-high-resolution optical coherence tomography. *Ophthalmology*. 2013;120(5):883–91. doi:10.1016/j.ophtha.2012.10.025.
 61. Izatt JA, Hee MR, Swanson EA. Micrometer-scale resolution imaging of the anterior eye in vivo with optical coherence tomography. *Arch Ophthalmol*. 1994;112(12):1584–9.
 62. Thomas B, Galor A, Nanji AA, Sayyad FE, Wang J, Dubovy S, et al. Ultra High-Resolution Anterior Segment Optical Coherence Tomography in the Diagnosis and Management of Ocular Surface Squamous Neoplasia. *Ocul Surf*. 2014;12(1):46–58. doi:10.1016/j.jtos.2013.11.001.
 63. Chin EK, Cortes DE, Lam A, Mannis MJ. Anterior segment OCT and confocal microscopy findings in atypical corneal intraepithelial neoplasia. *Cornea*. 2013;32(6):875–9. doi:10.1097/ICO.0b013e318285cab9.
 64. Pavlin CJ, Sherar MD, Foster FS. Subsurface ultrasound microscopic imaging of the intact eye. *Ophthalmology*. 1990;97(2):244–50.
 65. Bianciotto C, Shields CL, Guzman JM. Assessment of anterior segment tumors with ultrasound biomicroscopy versus anterior segment optical coherence tomography in 200 cases. *Ophthalmology*. 2011;118(7):1297–302.
 66. Finger PT, Tran HV, Turbin RE. High-frequency ultrasonographic evaluation of conjunctival intraepithelial neoplasia and squamous cell carcinoma. *Arch Ophthalmol*. 2003;121(2):168–72.
 67. Char DH, Kundert G, Bove R, Crawford JB. 20 MHz high frequency ultrasound assessment of scleral and intraocular conjunctival squamous cell carcinoma. *Br J Ophthalmol*. 2002;86(6):632–5.
 68. Koss LG. Cytologic and histologic manifestations of human papillomavirus infection of the female genital tract and their clinical significance. *Cancer*. 1987;60(8):1942–50. doi:10.1002/1097-0142(19901015)60:8+<1942::aid-cnrcr2820601504>3.0.co;2-v.
 69. Nanji AA, Sayyad FE, Karp CL. Topical chemotherapy for ocular surface squamous neoplasia. *Curr Opin Ophthalmol*. 2013;24(4):336–42.
 70. Sayed-Ahmed IO, Palioura S, Galor A, Karp CL. Diagnosis and medical management of ocular surface squamous neoplasia. *Expert Rev Ophthalmol*. 2017;12(1):11–9. doi:10.1080/17469899.2017.1263567.
 71. Verweij J, Pinedo HM. Mitomycin C: mechanism of action, usefulness and limitations. *Anticancer Drugs*. 1990;1(1):5–13.

72. Bayyat GA, Arreaza-Kaufman D, Venkateswaran N, Galor A, Karp CL. Update on pharmacotherapy for ocular surface squamous neoplasia. *Eye Vis (Lond)*. 2019;6:24. doi:10.1186/s40662-019-0150-5.
73. Conway RM, Graue GF, Pelayes DE. Conjunctival carcinoma. In: AJCC cancer staging manual. 8th edn. Basel: Springer; 2017. p. 787–93.
74. Singh P. Mitomycin-C use in ophthalmology. *IOSR J Pharm*. 2013;3(1):12–4.
75. Rudkin AK, Dempster L, Muecke JS. Management of diffuse ocular surface squamous neoplasia: efficacy and complications of topical chemotherapy. *Clin Exp Ophthalmol*. 2015;43(1):20–5.
76. Blasi MA, Maceroni M, Sammarco MG, Pagliara MM. Mitomycin C or interferon as adjuvant therapy to surgery for ocular surface squamous neoplasia: comparative study. *Eur J Ophthalmol*. 2018;28(2):204–9.
77. Shields CL, Naseripour M, Shields JA. Topical mitomycin C for extensive, recurrent conjunctival-corneal squamous cell carcinoma. *Am J Ophthalmol*. 2002;133(5):601–6.
78. Giacconi JA, Karp CL. Current treatment options for conjunctival and corneal intraepithelial neoplasia. *Ocul Surf*. 2003;1(2):66–73.
79. Frucht-Pery J, Sugar J, Baum J, Sutphin JE, Pe'er J, Savir H, et al. Mitomycin C treatment for conjunctival-corneal intraepithelial neoplasia : a multicenter experience. *Ophthalmology*. 1997;104(12):2085–93.
80. Hirst LW. Randomized controlled trial of topical mitomycin C for ocular surface squamous neoplasia: early resolution. *Ophthalmology*. 2007;114(5):976–82.
81. Ballalai PL, Erwenne CM, Martins MC, Lowen MS, Barros JN. Long-term results of topical mitomycin C 0.02% for primary and recurrent conjunctival-corneal intraepithelial neoplasia. *Ophthalmic Plast Reconstr Surg*. 2009;25(4):296–9.
82. Siganos CS, Kozobolis VP, Christodoulakis EV. The intraoperative use of mitomycin-C in excision of ocular surface neoplasia with or without limbal autograft transplantation. *Cornea*. 2002;21(1):12–6.
83. Kemp EG, Harnett AN, Chatterjee S. Preoperative topical and intraoperative local mitomycin C adjuvant therapy in the management of ocular surface neoplasias. *Br J Ophthalmol*. 2002;86(1):31–4.
84. Chen C, Louis D, Dodd T, Muecke J. Mitomycin C as an adjunct in the treatment of localised ocular surface squamous neoplasia. *Br J Ophthalmol*. 2004;88(1):17–8.
85. Khong JJ, Muecke J. Complications of mitomycin C therapy in 100 eyes with ocular surface neoplasia. *Br J Ophthalmol*. 2006;90(7):819–22.
86. Billing K, Karagiannis A, Selva D. Punctal-canalicular stenosis associated with mitomycin-C for corneal epithelial dysplasia. *Am J Ophthalmol*. 2003;136(4):746–7.
87. Longley DB, Harkin DP, Johnston PG. 5-fluorouracil: mechanisms of action and clinical strategies. *Nat Rev Cancer*. 2003;3(5):330–8.
88. Joag MG, Sise A, Murillo JC, Sayed-Ahmed IO, Wong JR, Mercado C, et al. Topical 5-fluorouracil 1% as primary treatment for ocular surface squamous neoplasia. *Ophthalmology*. 2016;123(7):1442–8.
89. Parrozzani R, Lazzarini D, Alemany-Rubio E, Urban F, Midena E. Topical 1% 5-fluorouracil in ocular surface squamous neoplasia: a long-term safety study. *Br J Ophthalmol*. 2011;95(3):355–9.
90. Venkateswaran N, Mercado C, Galor A, Karp CL. Comparison of topical 5-fluorouracil and interferon alfa-2b as primary treatment modalities for ocular surface squamous neoplasia. *Am J Ophthalmol*. 2019;199:216–22. doi:10.1016/j.ajo.2018.11.007.
91. Sepulveda R, Edoardo JP, Midena E, Seregard S, Dua HS, Singh AD, et al. Topical chemotherapy for ocular surface squamous neoplasia: current status. *Br J Ophthalmol*. 2010;94(5):532–5. doi:10.1136/bjo.2009.160820.
92. Viani GA, Fendi LI. Adjuvant treatment or primary topical monotherapy for ocular surface squamous neoplasia: a systematic review. *Arq Bras Oftalmol*. 2017;80(2):131–6.
93. Yeatts PR, Engelbrecht NE, Curry CD, Ford JG, Walter KA. 5-fluorouracil for the treatment of intraepithelial neoplasia of the conjunctiva and cornea. *Ophthalmology*. 2000;107(12):2191–5.
94. Midena E, Angeli CD, Valenti M, De Belvis V, Boccatto P. Treatment of conjunctival squamous cell carcinoma with topical 5-fluorouracil. *Br J Ophthalmol*. 2000;84(3):268–72.
95. Chaugule SS, Park J, Finger PT. Topical chemotherapy for giant ocular surface squamous neoplasia of the conjunctiva and cornea: is surgery necessary? *Indian J Ophthalmol*. 2018;66(1):55–60.
96. Houglum JE. Interferon: mechanisms of action and clinical value. *Clin Pharm*. 1983;2(1):20–8.
97. Karp CL, Galor A, Chhabra S, Barnes SD, Alfonso EC. Subconjunctival/perilesional recombinant interferon alpha2b for ocular surface squamous neoplasia: a 10-year review. *Ophthalmology*. 2010;117(12):2241–6.
98. Shah SU, Kaliki S, Kim HJ, Lally SE, Shields JA, Shields CL, et al. Topical interferon alfa-2b for management of ocular surface squamous neoplasia in 23 cases: outcomes based on American joint committee on Cancer classification. *Arch Ophthalmol*. 2012;130(2):159–64.
99. Vann RR, Karp CL. Perilesional and topical interferon alfa-2b for conjunctival and corneal neoplasia. *Ophthalmology*. 1999;106(1):91–7.
100. Galor A, Karp CL, Chhabra S, Barnes S, Alfonso EC. Topical interferon alpha 2b eye-drops for treatment of ocular surface squamous neoplasia: a dose comparison study. *Br J Ophthalmol*. 2010;94(5):551–4.
101. Shields CL, Kaliki S, Kim HJ, Al-Dahmash S, Shah SU, Lally SE, et al. Interferon for ocular surface squamous neoplasia in 81 cases: outcomes based on the American Joint Committee on Cancer classification. *Cornea*. 2013;32(3):248–56.
102. Kao AA, Galor A, Karp CL, Abdelaziz A, Feuer WJ, Dubovy SR, et al. Clinicopathologic correlation of ocular surface squamous neoplasms at Bascom palmer eye institute. *Ophthalmology*. 2001;119(9):1773–6.
103. Aldave AJ, Nguyen A. Ocular surface toxicity associated with topical interferon alpha-2b. *Br J Ophthalmol*. 2007;91(8):1087–8.
104. Tsatsos M, Karp CL. Modern management of ocular surface squamous neoplasia. *Expert Rev Ophthalmol*. 2014;8(3):287–95.
105. Barbazetto IA, Lee TC, Abramson DH. Treatment of conjunctival squamous cell carcinoma with photodynamic therapy. *Am J Ophthalmol*. 2004;138(2):183–9. doi:10.1016/j.ajo.2004.04.007.
106. Kim LA, D'Amore PA. A brief history of anti-VEGF for the treatment of ocular angiogenesis. *Am J Pathol*. 2012;181(2):376–9.
107. Finger PT, Chin KJ. Refractory squamous cell carcinoma of the conjunctiva treated with subconjunctival ranibizumab (Lucentis): a two-year study. *Ophthalmic Plast Reconstr Surg*. 2012;28(2):85–9. doi:10.1097/IOP.0b013e3182392f29.
108. Zaki AA, Fouad H, Emera S, Labib H. Subconjunctival anti VEGF for conjunctival intraepithelial and invasive neoplasia. *Aust J Basic Appl Sci*. 2009;3(4):3186–9.
109. Faramarzi A, Feizi S. Subconjunctival bevacizumab injection for ocular surface squamous neoplasia. *Cornea*. 2013;32(7):998–1001. doi:10.1097/ICO.0b013e318289ddd8.
110. Zabawski EJ, Cockerell CJ. Topical and intralesional cidofovir: a review of pharmacology and therapeutic effects. *J Am Acad Dermatol*. 1998;39(5):741–5.
111. Ip MH, George CR, Naing Z, Perlman EM, Rawlinson W, Coroneo MT, et al. Topical cidofovir for treatment-refractory ocular surface squamous neoplasia. *Ophthalmology*. 2018;125(4):617–9. doi:10.1016/j.ophtha.2017.11.021.
112. El-Sawy T, Sabichi AL, Myers JN, Kies MS, William WN, Glisson BS, et al. Epidermal growth factor receptor inhibitors for treatment of orbital squamous cell carcinoma. *Arch Ophthalmol*. 2012;130(12):1608–11. doi:10.1001/archophthol.2012.2515.
113. Tabbara KF, Kersten R, Daouk N, Blodi FC. Metastatic squamous cell carcinoma of the conjunctiva. *Ophthalmology*. 1988;95(3):318–21.
114. Tabin G, Levin S, Snibson G, Loughnan M, Taylor H. Late recurrences and the necessity for long-term follow-up in corneal and conjunctival intraepithelial neoplasia. *Ophthalmology*.

1997;104(3):485–92.

Author biography

Vibha Singh, Junior Resident

Rajendra Prakash Maurya, Associate Professor

Kajal Pal, Senior Resident

Shivangi Singh, Junior Resident

Virendra P Singh, Professor

Kartika Anand, Junior Resident

Cite this article: Singh V, Maurya RP, Pal K, Singh S, Singh VP, Anand K. Ocular surface squamous neoplasia: An overview. *IP Int J Ocul Oncol Oculoplasty* 2022;8(1):1-11.