

Content available at: <https://www.ipinnovative.com/open-access-journals>

IP International Journal of Ocular Oncology and Oculoplasty

Journal homepage: <https://ijooo.org/>

## Case Series

# To study the clinical course of rhino orbital mucormycosis in post COVID-19 patients: A case series

Aditi Jhunjhunwala<sup>1,\*</sup>, Ram Kumar<sup>1</sup>

<sup>1</sup>Dept. of Ophthalmology, B.R.D. Medical College, Gorakhpur, Uttar Pradesh, India



## ARTICLE INFO

### Article history:

Received 23-08-2021

Accepted 01-09-2021

Available online 25-10-2021

### Keywords:

clinical course

Covid 19

Fungal infection

Mucormycosis

## ABSTRACT

**Aim:** Rhino orbital cerebral mucormycosis is an opportunistic fungal infection with high morbidity and mortality which has seen the rise during the second wave of covid 19 in our country. Aim of our study was to study the clinical course, diagnosis and management of patient of rhino orbital mucormycosis in post covid phase presenting at our tertiary care centre.

**Materials and Methods:** 4 cases of rhino-orbital mucormycosis who presented to us in post covid phase was followed and details recorded and analyzed to study its clinical course, diagnosis and management.

**Observation:** 4 patients presented to us in post covid phase with signs of orbital cellulitis like periorbital swelling with pain, drooping of eyelids, proptosis, restriction of extraocular movements, decrease and loss of vision and sluggish reacting pupil. MRI/CT of the patients showed intraconal and extraconal involvement suggestive of orbital cellulitis. Diagnostic Nasal Endoscopy (DNE) was done and tissue sent for KOH mounting, culture and histopathology. After KOH mount showed fungal hyphae, patients were started on IV liposomal amphotericin B and retrobulbar amphotericin B. Patients were then taken up for endoscopic debridement and significant improvement in proptosis, ptosis, peribulbar swelling and pain was seen in immediate post op period.

**Conclusion:** significant improvement was seen in patients with IV amphotericin B, retrobulbar amphotericin B and endoscopic debridement.

**Key Message:** Patients with rhino orbital mucormycosis can be managed with amphotericin and endoscopic debridement when exenteration is not possible.

This is an Open Access (OA) journal, and articles are distributed under the terms of the [Creative Commons Attribution-NonCommercial-ShareAlike 4.0 License](https://creativecommons.org/licenses/by-nc-sa/4.0/), which allows others to remix, tweak, and build upon the work non-commercially, as long as appropriate credit is given and the new creations are licensed under the identical terms.

For reprints contact: [reprint@ipinnovative.com](mailto:reprint@ipinnovative.com)

## 1. Introduction

Rhino-orbital mucormycosis is one of the emerging and life threatening opportunistic infection in post covid patients. Patient present with signs of orbital cellulitis like periorbital swelling, conjunctival congestion and chemosis, ptosis, proptosis and loss of vision. Diabetes, oxygen inhalation, acidosis and steroid use are some risk factors. We present a case series of post covid rhino-orbital mucormycosis patients which were treated with IV liposomal amphotericin B, retrobulbar amphotericin B and endoscopic debridement.

\* Corresponding author.

E-mail address: [aditijtw@gmail.com](mailto:aditijtw@gmail.com) (A. Jhunjhunwala).

## 2. Case Report 1

A 74 year old male a known diabetic and hypertensive presented to us with complaints of pain and swelling over right cheek, right periorbital region, drooping of right eyelid and loss of vision in right eye for 1 week which was sudden in onset and progressive. Patient is post covid with history of hospitalization and dexamethasone was given for 9 days. There was no history of oxygen support. Patient was vaccinated with covishield first dose on 11<sup>th</sup> April 2021. On examination, GCS of the patient was 15/15, there was no meningeal signs with normal higher mental function, motor function and sensory functions. Right maxillary sinus

tenderness with ulcers on right buccal mucosa and necrosis of hard palate mucosa on right side was present. On examining right eye, there was complete ptosis, proptosis with hazy cornea and normal shaped and sluggish reacting pupil with extraocular movement restricted in all gazes and no perception of light. Fundus was normal. Examination of left eye was normal. MRI of the patient showed right pansinusitis with orbital involvement [Figure 1 a and b]. Diagnostic nasal endoscopy was done which showed black necrotic tissue/ eschar on middle turbinate and tissue was sent for KOH, culture and HPE. Patient was then started on injection Liposomal Amphotericin B (5mg/kg body weight) along with broad spectrum antibiotics vancomycin, meropenem and metrogl. Retrobulbar amphotericin B was given to the patient on 3 alternate days. KOH mount showed broad aseptate branched fungal hyphae. Patient then underwent FESS, when debridement of frontal and maxillary sinus with antrum and medial wall of orbital plate was done. Patient was then followed up in post operative period and showed stable clinical course on liposomal amphotericin B with decreased peribulbar swelling along with pain. [Figure 1c and d]

### 3. Case Report 2

A 40 year old male, known diabetic and hypertensive presented to us with complaints of pain and swelling over left cheek, left periorbital pain and swelling, Drooping of left eyelid and loss of vision in left eye for the last 15 days which was sudden in onset and progressive. Patient was post covid with no history of hospitalization, oxygen support, and steroid administration. No history of covid vaccination. On examination, GCS of the patient was 15/15, with normal higher mental function, motor function and sensory functions. Left maxillary and frontal sinus tenderness was present. On examining left eye, there was complete ptosis, proptosis with hazy cornea and normal shaped and sluggish reacting pupil with extraocular movement restricted in all gazes and no perception of light. Fundus was normal. Examination of right eye was normal. MRI of the patient shows moderate edema of the left sided recti muscles and extraconal involvement [Figure 2a]. Diagnostic nasal endoscopy was done which showed black necrotic tissue/ eschar on middle turbinate, inferior turbinate and bulla ethmoidalis with necrosis of hard palate [Figure 2b,c,d] and tissue was sent for KOH, culture and HPE. Patient was then started on injection Liposomal Amphotericin B (5mg/kg body weight) along with broad spectrum antibiotics vancomycin, meropenem and metrogl. Retrobulbar amphotericin B was given to the patient on 3 alternate days. KOH mount showed broad aseptate branched fungal hyphae. Patient complained of increase in pain on left side while being on Amphotericin B. MRI brain, orbit and PNS was repeated which showed intraconal along with extraconal and preseptal involvement

[Figure 3a,b] Patient then underwent FESS, all the sinuses were debrided along with parts of lamina papyracea which was eroded and necrosed orbital fat from medial, postero-superior and inferior parts till bleeding noticed from extra ocular muscles. Patient was then followed up in post op period and showed stable clinical course on liposomal amphotericin B with decreased peribulbar swelling along with pain [Figure 3c,d]

### 4. Case Report 3

A 65 year old male known diabetic and hypertensive presented to us with the complaints of difficulty in opening mouth, swelling on right cheek and right periorbital swelling and pain for the last 5 days which was sudden in onset and progressive. Patient was post covid with history of hospitalization (was in ICU for 3 days), oxygen support and steroids. No history of covid vaccination. On examination, GCS of the patient was 15/15, with normal higher mental function, motor function and sensory functions. White crusts in oral cavity and right maxillary sinus tenderness was present. Examination of the right eye showed conjunctival congestion with chemosis with moderate ptosis and proptosis, hazy cornea, pupil which was normal in shape and sluggish reacting to light with extraocular movements restricted in all gazes. Fundus was normal. Examination of the left eye was normal. MRI of the patient showed soft tissue thickening in right ethmoid and maxillary sinus with stranding of right retro orbital fat with enhancing preseptal soft tissue [Figure 4b,c]. Diagnostic nasal endoscopy was done which showed black necrotic tissue/ eschar on middle turbinate with necrosis of hard palate and tissue was sent for KOH, culture and HPE. Patient was then started on injection Liposomal Amphotericin B (5mg/kg body weight) along with broad spectrum antibiotics vancomycin, meropenem and metrogl. Retrobulbar amphotericin B was given to the patient on 3 alternate days. KOH mount showed broad aseptate branched fungal hyphae. Patient then also underwent FESS, with sinus debridement and lamina papyracea which was necrosed, orbit was entered and orbital fat and tissues was debrided till healthy tissue was seen. Patient was then followed up in post op period and showed stable clinical course on liposomal amphotericin B with decreased peribulbar swelling along with pain [Figure 4a].

### 5. Case Report 4

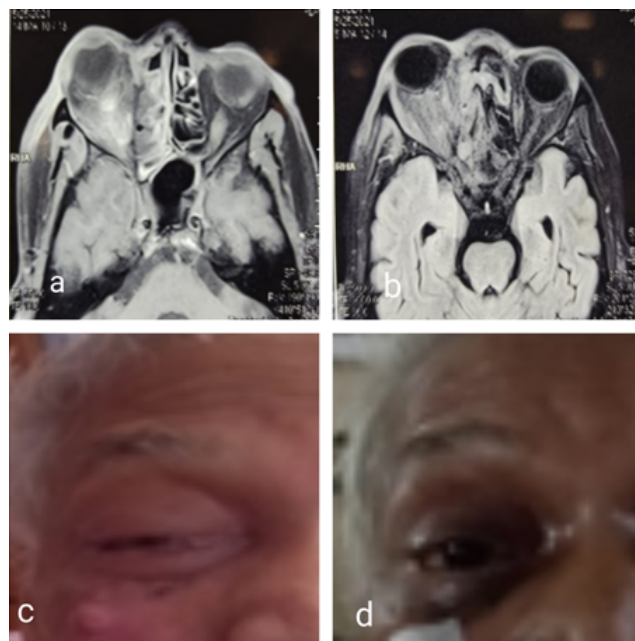
A 51 year old male, known diabetic and hypertensive presented to us with chief complaints of swelling on right cheek for 10 days. Right periorbital pain and swelling, right hemcranial headache, drooping of right eye lid and Loss of vision for 6 days. Patient developed symptoms while he was covid -19 positive for which he was hospitalized, was on oxygen support and given dexamethasone for 6 days. He presented to us a day after testing negative

for covid -19. On examination, GCS of the patient was 15/15, with normal higher mental function, motor function and sensory functions. Right maxillary sinus tenderness. On examining right eye, there was complete ptosis, proptosis with conjunctival congestion and chemosis and normal shaped and sluggish reacting pupil with extraocular movement restricted in all gazes and no perception of light. Fundus was normal. Examination of left eye was normal. CT of the patient showed Mucosal thickening in right frontal, maxillary and ethmoid sinuses with obliterated right osteomeatal complex with central hypodense and central hyperdense area lateral to lateral rectus on right side with displacement of lateral rectus with mild thickening of right optic nerve [Figure 5b,c]. Diagnostic nasal endoscopy was done which showed black necrotic tissue/ eschar on middle and inferior turbinate and tissue was sent for KOH, culture and HPE. Patient was then started on injection Liposomal Amphotericin B (5mg/kg body weight) along with broad spectrum antibiotics vancomycin, meropenem and metrogyl. Retrobulbar amphotericin B was given to the patient on 3 alternate days. KOH mount showed broad aseptate branched fungal hyphae. Patient then also underwent FESS, with debridement of sinuses and lamina papyracea was done. Orbit was then entered and necrotic tissue was removed till healthy bleeding seen. Patient was then followed up in post op period and showed stable clinical course on liposomal amphotericin B with decreased peribulbar swelling along with pain. [Figure 5 a]

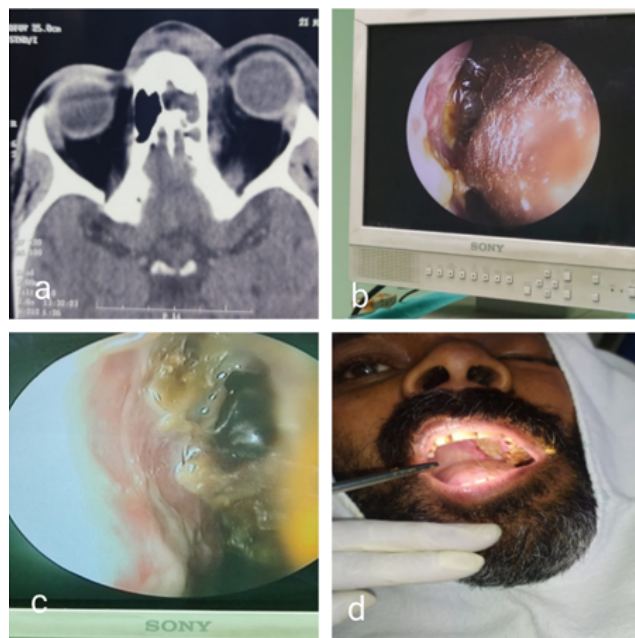## 6. Discussion

A novel coronavirus was identified by the Chinese Center for Disease Control and Prevention (CDC) on 7 January 2020 and was subsequently named by WHO 2019-nCoV.<sup>1,2</sup> Coronavirus consumes immune cells leading to decrease in the total number of lymphocytes which in turn inhibits body's cellular immune function,<sup>1</sup> which along with the complex interaction of different factors like preexisting comorbidities (diabetes mellitus, kidney disease), use of immunosuppressive drugs, hospital acquired infection leads to secondary infection in patients.<sup>3</sup> Use of intravenous methylprednisolone 0.5-1 mg/kg/day for three days in moderate cases and 1-2 mg/kg/day in severe cases is currently recommended by Government of India (GOI)<sup>4</sup> and the use of dexamethasone (6 mg per day for a maximum of 10 days) in patients on ventilator or on supplemental oxygen is recommended by The National Institute of Health.<sup>5</sup>

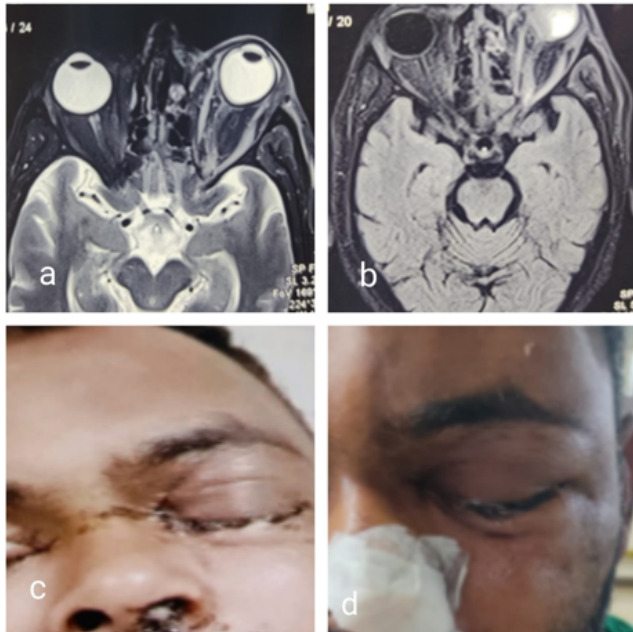
Mucormycosis is a rare life threatening angio-invasive fungal infection of the group mucormycetes which are found abundantly in nature. Spores of these fungi can be inhaled and then infect the lungs, sinuses, eye and can extend into the brain. People who are immunocompromised having diabetes, solid organ transplantation, neutropenia, long-term systemic corticosteroid use, and iron overload are at highest risk.<sup>6,7</sup> Mucormycosis in post covid patients



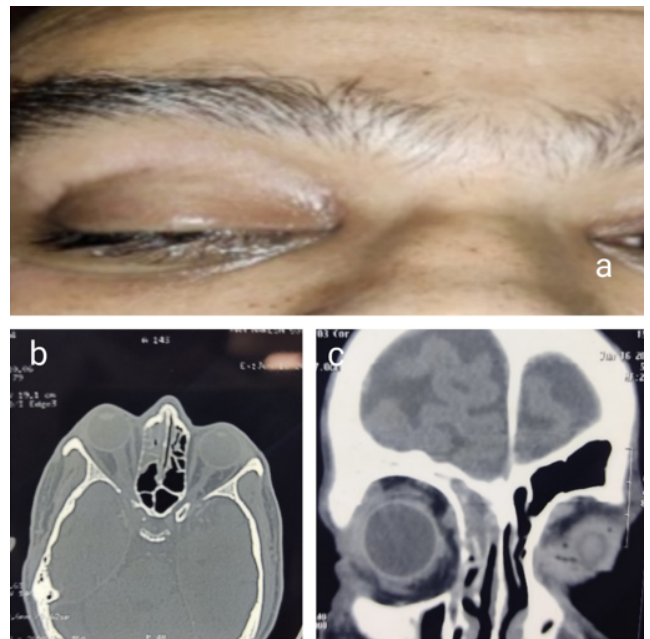
**Fig. 1:** a: MRI of the patient involvement of ant and post ethmoid sinus with right intraconal and extraconal involvement of the orbit; b: T2 weighted MRI image showing involvement of right ethmoid and sphenoid sinus along with intra and extraconal involvement of right orbit; c: Pre FESS photo of patient showing complete ptosis and abscess on right cheek; d: Post FESS photo shows decreased swelling, and moderate ptosis.



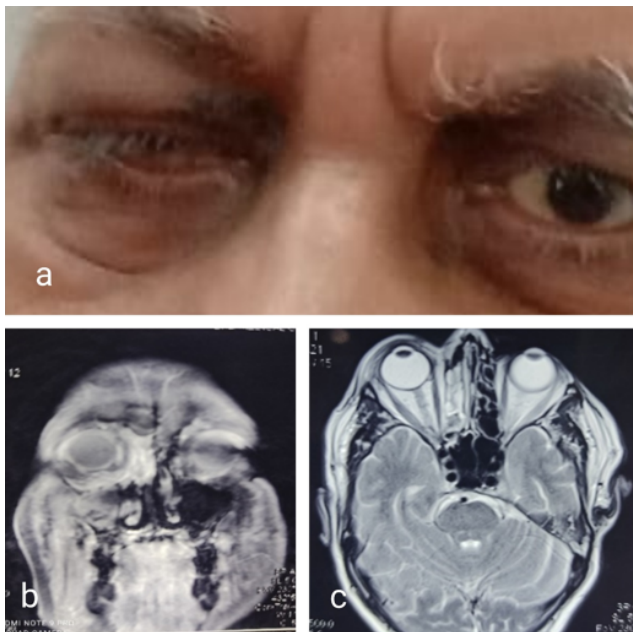
**Fig. 2:** a: MRI of the patient shows moderate edema of the left sided recti muscles and extraconal involvement; b,c,d: Diagnostic nasal endoscopy showed black necrotic tissue/ eschar on middle turbinate, inferior turbinate and bullaethmoidalis with necrosis of hard palate.



**Fig. 3:** a,b: Repeat MRI showed intraconal along with extraconal and preseptal involvement; c: pre FESS; d: post FESS.



**Fig. 5:** a: Post FESS; b,c: CT of the patient showed Mucosal thickening in right frontal, maxillary and ethmoid sinuses with obliterated rightosteomeatal complex with central hypodense and central hyperdense area lateral to lateral rectus on right side with displacement of lateral rectus with mild thickening of right optic nerve.



**Fig. 4:** a: Post FESS; b,c: MRI showing soft tissue thickening in right ethmoid and maxillary sinus with stranding of right retro orbital fat with enhancing preseptal soft tissue.

is now a common problem we all are dealing with. Its strongest association was found to be with hyperglycemic state like uncontrolled diabetes mellitus.<sup>8</sup> In a recent review, 72% of the total cases were reported from India among which 78% were males, 85% had history of diabetes mellitus and 85% had history of Glucocorticoid use. The median time interval between first covid positive report and first symptom of mucormycosis was found to be 15 days.<sup>8</sup>

Diagnosis of mucormycosis is based on clinical history and examination, imaging, microbiology and histopathology. MRI/CT findings are often nonspecific which makes it difficult to distinguish it from other entities. These are best employed to delineate the extent of disease.<sup>9</sup> Confirmation of diagnosis is done by KOH mount showing fungal hyphae, culture showing growth of mucor and histopathology shows pathognomonic broad, irregular, non-septate, and right-angle branching hyphae along with evidence of angioinvasion and tissue infarction.<sup>10</sup>

Aiims Rishikesh Management protocol for mucormycosis advises urgent surgical debridement of all necrotic tissue along with strict glycemic control and systemic anti fungal (liposomal amphotericin B 5-10mg/kg body weight) with azole derivatives (posaconazole and isavuconazole) as second line therapy.<sup>11</sup>

In our study, all the patients received broad spectrum antibiotic coverage, intravenous liposomal amphotericin

B injection, retrobulbar liposomal amphotericin B and debridement of the necrotic tissue endoscopically. All the patients in follow up period showed some improvement with these measures with significant improvement seen in peribulbar swelling, pain, ptosis and proptosis. It also decreased the need of exenteration, about which patients were very apprehensive because of the possible deformity and were not ready to give consent for the surgery. Endoscopic debridement has the benefit of being cosmetically acceptable procedure and along with local infiltration with amphotericin B it showed significant improvement in patients and can be done as an eye saving procedure.

### 7. Conflict of Interest

There is no conflict of interest. The authors alone are responsible for the content and writing of the paper.

### 8. Source of Funding

None.

### References

1. Chen N, Zhou M, Dong X. Epidemiological and clinical characteristics of 99 cases of 2019 novel coronavirus pneumonia in Wuhan, China: a descriptive study. *Lancet*. 2020;395(10223):507–13. doi:10.1016/S0140-6736(20)30211-7.
2. Maurya R. Ocular trauma during COVID-19 crisis: Trends and management. *Indian J Clin Exper Ophthalmol*. 2020;6(4):478–9.

3. Mehta S, Pandey A. PMID. 2020.
4. 2020. Available from: <https://www.mohfw.gov.in/pdf/ClinicalManagementProtocolforCOVID19.pdf2020>.
5. Horby P, Lim WS, Emberson JR, Mafham M, Bell JL, Linsell L, et al. Dexamethasone in hospitalized patients with Covid-19 - preliminary report. The RECOVERY Collaborative Group. *New Engl Med*. 2020;384(8):693–704. doi:10.1056/NEJMoa2021436.
6. WHO south Asia. Available from: [https://www.who.int/india/emergencies/coronavirus-disease-\(covid-19\)/mucormycosis](https://www.who.int/india/emergencies/coronavirus-disease-(covid-19)/mucormycosis).
7. Maurya RP. Post COVID-19 Mucormycosis: What is role of iron and iron chelating agents? *Indian J Clin Exper Ophthalmol*. 2020;7(2):253–4.
8. Pal R, Singh B, Bhadada SK, Banerjee M, Bhogal RS, Hage N, et al. COVID-19-associated mucormycosis: An updated systematic review of literature. *Mycoses*. 2021;doi:10.1111/myc.13338..
9. Available from: [www.aao.org/eyenet/article/diagnosis-management-of-orbital-mucormycosis](http://www.aao.org/eyenet/article/diagnosis-management-of-orbital-mucormycosis).
10. Maurya RP. Indications for orbital exenteration in COVID-19 associated Rhino-orbital-cerebral Mucormycosis. *IP Intern J Ocular Oncol Oculoplasty*. 2021;7(2):105–8.
11. Available from: [https://aiimsrishikesh.edu.in/a1\\_1/wp-content/uploads/2020/11/MUCOR-Management-protocol\\_AIIMS-Rishikesh\\_Version-1.0.cleaned.pdf](https://aiimsrishikesh.edu.in/a1_1/wp-content/uploads/2020/11/MUCOR-Management-protocol_AIIMS-Rishikesh_Version-1.0.cleaned.pdf).

### Author biography

Aditi Jhunjhunwala, Resident

Ram Kumar, HOD

**Cite this article:** Jhunjhunwala A, Kumar R. To study the clinical course of rhino orbital mucormycosis in post COVID-19 patients: A case series. *IP Int J Ocul Oncol Oculoplasty* 2021;7(3):328-332.