

Content available at: <https://www.ipinnovative.com/open-access-journals>

IP International Journal of Ocular Oncology and Oculoplasty

Journal homepage: <https://ijooo.org/>

## Case Report

# A rare case report on thyroid associated orbitopathy

Leena Paul<sup>1,\*</sup>, Utkarsh Rai<sup>1</sup>

<sup>1</sup>Dept. of Ophthalmology, Assam Medical College and Hospital, Dibrugarh, Assam, India



### ARTICLE INFO

#### Article history:

Received 08-06-2021

Accepted 06-08-2021

Available online 25-10-2021

#### Keywords:

Graves disease

Ptosis

Proptosis

Thyroid associated orbitopathy

Specific orbital inflammatory disease

### ABSTRACT

Thyroid associated orbitopathy (TAO) or graves disease is an autoimmune disorder associated with hyperthyroidism though few cases of hypothyroidism and euthyroidism are also found. Most common presentation is eyelid retraction followed by exophthalmos. Although TAO is more common in women, the proportion in men increases as severity increases. We report a case of young adult woman who presented with proptosis, severe ptosis in right eye and motility restriction in both eye with moderately painful swelling of right eyelid. CEMRI orbit revealed swelling of bilateral recti muscles with sparing of tendons which is characteristic of TAO. Thyroid profile showed hyperthyroid state, Clinical features were suggestive of orbital apex syndrome and diagnosis of TAO was based on orbital muscle changes in MRI. A course of methylprednisolone was given with tapering dose which improved proptosis, ptosis and extraocular movement on follow up.

This is an Open Access (OA) journal, and articles are distributed under the terms of the [Creative Commons Attribution-NonCommercial-ShareAlike 4.0 License](https://creativecommons.org/licenses/by-nc-sa/4.0/), which allows others to remix, tweak, and build upon the work non-commercially, as long as appropriate credit is given and the new creations are licensed under the identical terms.

For reprints contact: [reprint@ipinnovative.com](mailto:reprint@ipinnovative.com)

## 1. Introduction

Thyroid eye disease (TED) is an autoimmune inflammatory orbital disease potential to cause severe functional, aesthetic and psychosocial effects.<sup>1</sup> TED or thyroid associated orbitopathy (TAO) or Graves disease is the most common cause of unilateral and bilateral proptosis in young adults.<sup>2</sup> Pathogenesis include glycosaminoglycan deposition, fibrosis affecting extraocular muscles and adipogenesis in orbit.<sup>3–7</sup>

The accompanying ocular swelling, chemosis, proptosis and eyelid retraction help in diagnosis. In absence of eye findings TAO would not be suspected primarily. In such cases orbital apex syndrome may be suspected as there is palsy of II, III, IV and VI cranial nerves which can be confirmed by radiological findings.<sup>8</sup>

This case report highlights rare presentation of TAO with absence of characteristic ocular findings and importance of

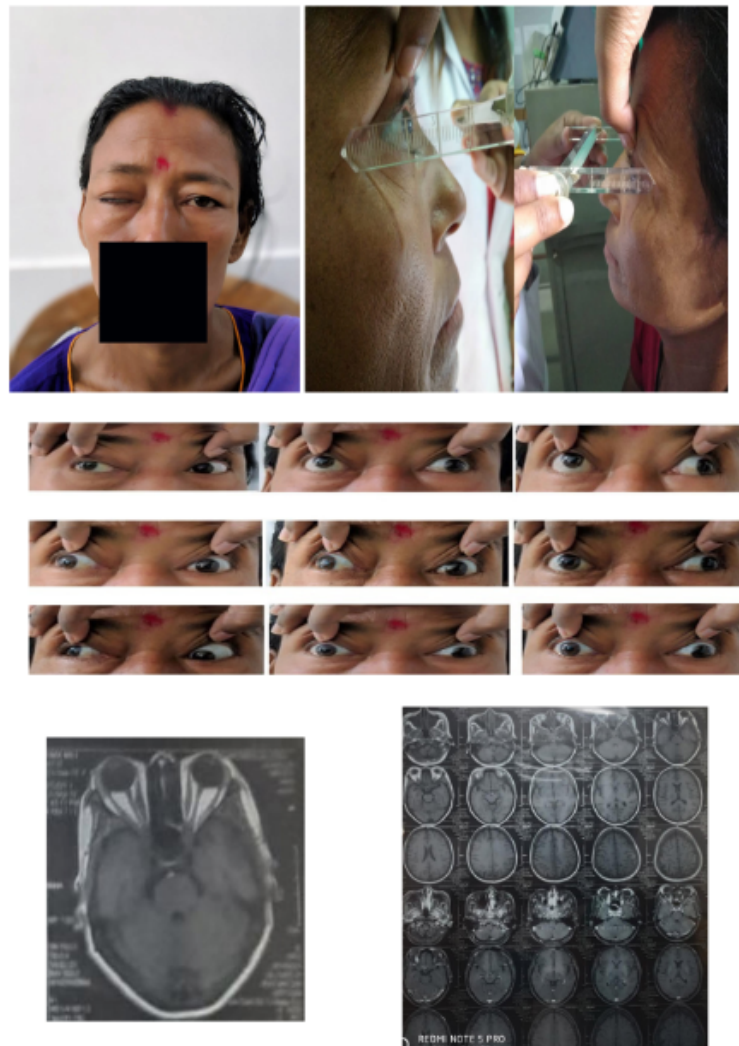
radiological imaging for diagnosis.

## 2. Case History

A 35 years female presented with insidious onset bulging of right eyeball, drooping of right upper eyelid and restriction of movements of both eye since 6 months. Symptoms were associated with moderate pain and swelling in right eyelid. She had no history of smoking, antecedent trauma, eyelid surgery, bleeding diatheses or drug intake. On examination patient was conscious cooperative and well oriented. Her vitals, general and systemic examination were normal. BCVA both eye 6/6N6 and IOP was within normal limit. Right eyelid was swollen with severe ptosis (figure) and impaired LPS function along with restriction of extra ocular movement (figure). Axial proptosis in right eye was 24mm which is non-compressible, non pulsatile, non transillumination and size doesn't change with Valsalva maneuver or coughing, straining and change in head position and no bruit heard. Rest of the anterior and

\* Corresponding author.

E-mail address: [leenapaul.assam@gmail.com](mailto:leenapaul.assam@gmail.com) (L. Paul).



**Fig. 1:**

posterior segment were found to be normal.

On investigation random blood sugar, haemogram, serum electrolyte and renal function were normal however TSH (Thyroid stimulating hormone)  $< 0.015 \mu\text{Iu/ml}$ , FT3 (free T3)  $2.87 \text{ ng/dl}$  and FT4 (free T4)  $15.0 \mu\text{g/dl}$ . Contrast enhancement MRI (CEMRI) of brain and orbit showed fusiform enlargement of bilateral medial rectus, superior rectus and lateral rectus muscle sparing tendinous insertion site showing homogenous post contrast enhancement. The presence of characteristic MRI finding with low TSH and high FT3 & FT4 confirms the diagnosis of thyroid associated orbitopathy.

Patient was treated with oral prednisolone on tapering dose, propranolol and propylthiouracil and she has been followed up after 1 month which showed reduction in proptosis (21mm) and slight improvement of motility and ptosis.

### 3. Discussion

TAO is a syndrome comprising hyperthyroid goitre, dermatopathy and 50% develops orbitopathy,<sup>9,10</sup> which gradually leads to compression of the intraorbital contents resulting in disorders of the lid-corneal interface, exposure keratopathy, motility restriction, severe proptosis and increase IOP leads to dysthyroid optic neuropathy.<sup>11,12</sup>

In our case the young female patient was clinically diagnosed as orbital apex syndrome as there was palsy of combination of cranial nerves along with ptosis. In this syndrome lesions are localised to the apex of the orbit which includes infections, neoplasm, TAO, granulomatous, iatrogenic mucocele and vascular lesions.<sup>13–17</sup> The important differentials were TAO and Tolosa Hunt Syndrome. The CEMRI of brain and orbit showed inflammation and swelling of ocular muscles with sparing of tendinous insertion site which is characteristic of

TAO and hyperthyroid profile also supports the diagnosis. Imaging didn't show any mass lesion or localised collection and brain parenchyma was also found to be normal.

The eyelid involvement (ptosis) and impairment of extraocular muscles could be explained by inflammation of recti muscles and compression of trigeminal nerve. Clinical activity score in our case was 4 where the role of anti-inflammatory drug is predicted to be good.<sup>18</sup> As vision was normal and response rate of glucocorticoid is 63-70%,<sup>19</sup> oral methyl prednisolone 1g/day was given on tapering dose. There was improvement on following up of the case. On concluding thyroid eye Disease run a self limited course with intermission and relapse, more or less unaffected by treatment but spontaneous resolution occurs which is rarely complete.

#### 4. Conflict of Interest

The authors declare that there are no conflicts of interest in this paper.

#### 5. Source of Funding

None.

#### References

1. Kashkoui MB, Kaghazkanani R, Heidari I, Ketabi N, Jam S, Azarnia S, et al. Bilateral versus unilateral thyroid eye disease. *Indian J Ophthalmol.* 2011;59(5):363–6.
2. Manjandavida FP, Chahar S. An update on thyroid eye disease: Current knowledge, preferred practice patterns, and future therapies. *Kerala J Ophthalmol.* 2020;32(1):10.
3. Bahn RS, Heufelder AE. Pathogenesis of Graves' ophthalmopathy. *N Engl J Med.* 1993;329(20):1468–75.
4. Feldon SE, Weiner JM. Clinical significance of extraocular muscle volumes in Graves' ophthalmopathy: A quantitative computed tomography study. *Arch Ophthalmol.* 1982;100(8):1266–9. doi:10.1001/archophth.1982.01030040244006.
5. Nunery WR, Nunery CW, Martin RT, Truong TV, Osborn DR. The risk of diplopia following orbital floor and medial wall decompression in subtypes of ophthalmic Graves' disease. *Ophthal Plast Reconstr Surg.* 1997;13(3):153–60. doi:10.1097/00002341-199709000-00001.
6. Smith TJ, Hoa N. Immunoglobulins from patients with Graves' disease induce hyaluronan synthesis in their orbital fibroblasts through the self-antigen, insulin-like growth factor-I receptor. *J Clin Endocrinol Metab.* 2004;89(10):5076–80. doi:10.1210/jc.2004-0716.
7. Maurya RP, Ananya PR, Kadir SM, Singh VP. Recent advances in thyroid eye disease: An overview. *IP Int J Ocular Oncol Oculoplast.* 2021;7(2):117–30.
8. Verma R, Gupta M, Mehta VK. Thyroid associated orbitopathy. *BMJ Case Rep.* 2013;2013:bcr2013009920. doi:10.1136/bcr-2013-009920.
9. Burch HB, Wartofsky L. Graves' ophthalmopathy: Current concepts regarding pathogenesis and management. *Endocr Rev.* 1993;14:747–93.
10. Siracuse-Lee DE, Kazim M. Orbital decompression: Current concepts. *Curr Opin Ophthalmol.* 2002;13(5):310–6. doi:10.1097/00055735-200210000-00004.
11. Aggarwal S, Maurya RP. Current concepts in diagnosis and management of Grave's orbitopathy: An overview. *International J Ocular Oncol Oculoplasty.* 2016;2(1):31–41.
12. Verity DH, Rose GE. Acute thyroid eye disease (TED): Principles of medical and surgical management. *Eye (Lond).* 2013;27(3):308–19. doi:10.1038/eye.2012.284.
13. Saxena R, Phuljhele S, Aalok L. A rare case of orbital apex syndrome with herpes zoster ophthalmicus in a human immunodeficiency virus-positive patient. *Indian J Ophthalmol.* 2010;58(6):527–30. doi:10.4103/0301-4738.71708.
14. Kurimoto T, Tonari M, Ishizaki N. Orbital apex syndrome associated with herpes zoster ophthalmicus. *Clin Ophthalmol.* 2011;5:1603–8. doi:10.2147/OPHTH.S25900.
15. Sethi A, Sareen D, Mrig S, Agarwal AK, Khara PS. Acute suppurative otitis media: an unusual cause of orbital apex syndrome. *Orbit.* 2008;27(6):462–5. doi:10.1080/01676830802352519.
16. Li Y, Wu W, Xiao Z, Peng A. Study on the treatment of traumatic orbital apex syndrome by nasal endoscopic surgery. *Eur Arch Otorhinolaryngol.* 2011;268(3):341–9. doi:10.1007/s00405-010-1409-6.
17. Venkitaraman R, Madhavan J, Ramachandran K. Primary adenoid cystic carcinoma presenting as an orbital apex tumor. *Neuroophthalmology.* 2008;32(1):27–32. doi:10.1080/01658100701818198.
18. Maheshwari R, Weis E. Thyroid associated orbitopathy. *Indian J Ophthalmol.* 2012;60(2):87–93. doi:10.4103/0301-4738.94048.
19. Mallika PS, Tan AK, Aziz S. Thyroid associated ophthalmopathy-a review. *Malays Fam Physician.* 2009;4(1):8–14.

#### Author biography

**Leena Paul**, Senior Resident

**Utkarsh Rai**, Resident

**Cite this article:** Paul L, Rai U. A rare case report on thyroid associated orbitopathy. *IP Int J Ocul Oncol Oculoplasty* 2021;7(3):306-308.