



## Case Report

# Severe dry eye associated with Steven Johnson Syndrome: A case report

Namrata Shree<sup>1,\*</sup>, Baby Deka<sup>1</sup>, Rajneel Bhattacharjee<sup>1</sup>

<sup>1</sup>Dept. of Ophthalmology, Silchar Medical College and Hospital, Silchar, Assam, India



### ARTICLE INFO

#### Article history:

Received 04-06-2021

Accepted 16-06-2021

Available online 24-07-2021

#### Keywords:

Case Report

Dry eye

Steven Johnson Syndrome

Toxic Epidermal Necrolysis

### ABSTRACT

**Introduction:** Stevens-Johnson-Syndrome (SJS), and its severe variant, toxic epidermal necrolysis (TEN), are life-threatening diseases of skin and mucous membranes. Cases with pseudo-membrane formation and epithelial defects, have higher risk of ocular sequelae. Severe dry eye in SJS includes three mechanisms: (1) aqueous tear deficiency, (2) decreased wettability of corneal surface, and (3) increased evaporation.

**Observation:** A 47-year-old male patient presented in OPD with chief complaint of severe discomfort and grittiness in both eyes since last 21 years. Proper history taking and examination was done. Patient was given conservative treatment and was explained about recent advancements of treatment that can help in improving his condition.

**Conclusion:** In SJS patients, dryness causes eye pain, and unstable tear film causes diminution of vision. After acute stage reactions, visual impairment and severe dry eye are observed as ocular sequelae.

© This is an open access article distributed under the terms of the Creative Commons Attribution License (<https://creativecommons.org/licenses/by/4.0/>) which permits unrestricted use, distribution, and reproduction in any medium, provided the original author and source are credited.

## 1. Introduction

Stevens-Johnson-Syndrome (SJS) and Toxic-Epidermal-Necrolysis (TEN), are acute inflammatory diseases of skin and mucous membranes predisposing patients to life-threatening complications like sepsis, respiratory and multi-organ dysfunction.<sup>1</sup> After acute-stage subsides, cicatrization of ocular surface progresses, visual impairment and ocular discomfort develops.<sup>2-4</sup> In the acute phase of SJS-TEN, 75-80% patients have ocular involvement. Among these, chronic ocular manifestations develop in 21-29% of pediatric cases and 27-59% of adult cases.

Most frequent ocular sequelae is Dry Eye.<sup>5,6</sup> SJS is defined when skin and mucous membrane involvement is less than 10% , TEN when over 30% and “overlapping SJS-TEN” when 10% to 30%.<sup>7</sup>

At chronic stage, with identical ocular findings, its difficult to differentiate SJS from TEN. So, ocular surface diseases are collectively termed “SJS” from Ophthalmologist’s perspective.

Chronic stage is characterized by posterior lid margin keratinization and corneal changes that impair vision.

Treatment option for posterior lid margin keratinization include topical all-trans retinoic acid, autologous mucosal membrane grafting, and protective scleral contact lenses. The topical all-trans retinoic acid and autologous mucosal membrane grafting decrease the extent of lid margin keratinization. Topical all trans retinoic acid is a non-invasive means to treat keratinization by altering epithelial cell differentiation. In autologous mucous membrane grafting, surgical excision of the keratinized lid margin and replacing it with mucosal membrane grafted from the oral cavity is required. The scleral lens forms a protective barrier and seals the tear film layer for the corneal surface and help in reducing the extent of mechanical injury to the cornea from the posterior eyelid margin, distichiasis, trichiasis, and other adnexal changes.

In Meibomian gland dysfunction with reduced tear production, treatment options are, artificial tears that supplement natural tear production,<sup>8</sup> punctal occlusion that prevents drainage of naturally formed tears and salivary gland transplantation in superior and inferior conjunctival

\* Corresponding author.

E-mail address: [angel.dcool5@gmail.com](mailto:angel.dcool5@gmail.com) (N. Shree).

fornices.

In this case report we will observe the manifestation of dry eye associated with Steven Johnson Syndrome, the treatment provided and various treatment options available.

## 2. Case Report

A 47 year old male presented to the ophthalmology outpatient department with the chief complaint of diminution of vision, feeling of dryness, grittiness and nonspecific ocular discomfort in both eyes since last 21 years.

He gave history of taking anti-malarial drugs 21 years back after which he developed severe allergic reaction all over his body including both eyes. For this he got admitted and treated in a hospital setup.

Ocular examination revealed Entropion and Trichiasis of eyelids of both eyes (Figure 1), Conjunctival xerosis and Symblepheron due to cicatrization and Corneal xerosis and keratinization of both eyes (Figure 2).

Both punta of both eyes are found to be stenosed. On General examination – systemic findings were normal and no skin lesions were seen at the present stage of the disease.

Routine blood investigations, blood sugar levels, viral serology, chest x-ray and x-ray of limbs and joints were done, to identify any disease if present for which patient might require drugs that can lead to Steven Johnson Syndrome.

Drugs causing SJS are as follows– Anti malarials (Chloroquine), Anti-gout medication (Allopurinol), Anticonvulsants (Phenytoin, Carbamazepine), Antipsychotic (Haloperidol), Antibiotics (sulphonamides), etc.

The following specific tests for dry eye were done;

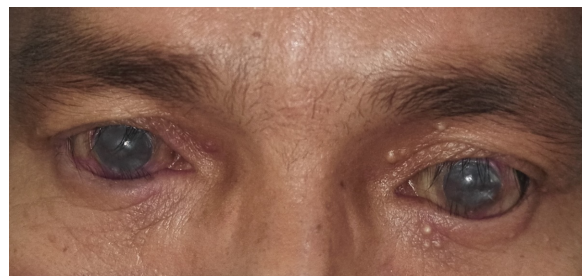1. Schirmer test (Figure 3 a and b): R/E - No wetting at the end of 5 min, L/E - No wetting at the end of 5 min
2. Tear film breakup time: R/E - No tear film present, L/E - No tear film present
3. Ocular surface staining (Fluorescein) (Figure 4 a and b): R/E - Stain negative corneal opacity, L/E - Stain negative corneal opacity.

The patient was treated with–

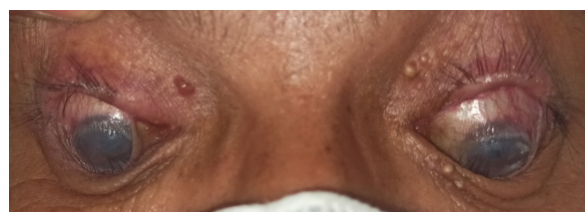1. E/D cyclosporine – 1 DROP 2 TIMES DAILY B/E  
Cyclosporine is an immunomodulator (calcineurin inhibitor) that helps in reducing the inflammatory reactions.
2. E/D carboxymethyl cellulose 1% GEL – 1 Drop 4 times daily B/E.  
Artificial tears are the mainstay of treatment which reduces the symptoms of dry eye and prevent further damage.
3. Emollient eye gel –To apply locally at bed time B/E.  
Emollient gel helps in soothing the grittiness and

discomfort caused by dry eye.

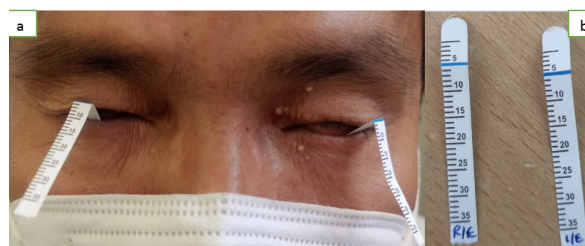The patient has been explained about recent advancements of treatment other than those already used, that can help in improving his condition.



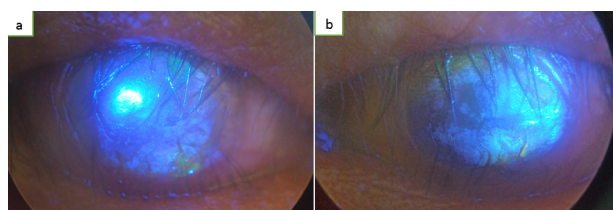
**Fig. 1:** Entropion and Trichiasis of eyelids of both eyes seen in a case of SJS



**Fig. 2:** Conjunctival xerosis and Symblepheron due to cicatrization and Corneal xerosis and keratinization of both eyes seen in a case of SJS



**Fig. 3: a;** Schirmer's test procedure performed, **b;** Schirmer's test result showing no wettability at 5 minutes in both eyes,



**Fig. 4: a and b** – Ocular surface staining result seen in, (4a) Right eye and (4b) Left eye

### 3. Discussion

Very severe dryness of the ocular surface causes eye pain, photophobia, foreign body sensation, and visual disturbance, and patients have difficulty in opening their eyes.<sup>9</sup> Sometimes, SJS patients present to us with the complaint of severe dryness of the eye despite frequent instillation of artificial tears eye drops.

So, it is necessary to understand that severe dry eye with the combined mechanisms of aqueous tear deficiency, decreased corneal surface wettability, and increased evaporation may be involved in cicatrized cases with Steven Johnson Syndrome.

The initial ocular pathogenesis of Steven Johnson Syndrome is conjunctival inflammation and necrosis. Followed by subsequent destruction of goblet cells and keratinization. Final outcome is often scarring. Mucus production from goblet cells is essential for maintaining the adequate tear film required for corneal clarity. The long-term sequelae occur as a combined effect of cicatricial conjunctivitis and inadequate tear film.

The eyes in which the superior and inferior punctum are occluded due to scarring or surgery (e.g., punctal plugs or cauterization), tear deficiency is often underestimated when the meniscus is first observed. SJS related complications like trichiasis, cicatricial entropion, and scarring of the mucocutaneous junction (lid margin) can be the cause of blink-related microtrauma, and intensify the symptoms related to dry eye.<sup>4–6</sup>

It is to be remembered that a stable tear film over the cornea is required for consistent good vision, and that unstable tear film related to dry eye can result in diminution of vision. In fact, SJS patients at the chronic stage usually complain of decreasing visual acuity, especially in the eye with severe dry eye, depending on the time after blinking. By the use of functional visual acuity (FVA) measurement system, Dynamic visual changes can be continuously measured in a 30-second blink-free period in one eye. Kaido et al.<sup>10</sup> examined the Dynamic visual changes in SJS using the FVA system and reported that time related decline of FVA was more in patients with SJS as compared to normal subjects. In addition to the above observation, the visual maintenance ratio (VMR) was found to be markedly lower in patients with SJS as compared to patients with Sjogren syndrome (SS) and normal controls.

To achieve a proper treatment of dry eye in SJS cases, it is vital to pay attention to ocular surface inflammation along with dry eye. In SJS, at the chronic stage, there exists persistent conjunctival inflammation.<sup>11</sup> Recently, chronic inflammation in the follicles of eyelashes. The administration of artificial tears is necessary to increase the tear volume, and preservative-free artificial tears are recommended for this purpose. Scleral contact lenses, and newly developed limbal-rigid contact lenses, improve the patients' visual acuity and reduce symptoms.<sup>12</sup>

As of now, autologous serum/plasma is being widely used for the treatment of dry eye and/or persistent corneal epithelial defects. The application of a punctal plug or surgical punctal occlusion is also effective in some cases.<sup>12</sup> In cases of chronic inflammation, low-dose topical steroids decrease the patients' symptoms. But, when topical steroids are used, strict attention is to be paid to adverse events like infectious keratitis and the elevation of intraocular pressure.

In our case, as it's in chronic stage, the treatment initially given was directed to reduce any inflammation if present for which topical cyclosporine was given, and to maintain a tear film we gave topical carboxymethyl cellulose 1%.

### 4. Source of Funding

None.

### 5. Conflicts of Interest

All contributing authors declare no conflict of interest.

### References

1. Stevens A, Johnson F. A new eruptive fever associated with stomatitis and ophthalmia: report of two cases in children. *Am J Dis Child.* 1922;24(6):526–33. doi:10.1001/archpedi.1922.04120120077005.
2. Lehman SS. Long-term Ocular Complication of Stevens-Johnson Syndrome. *Clin Pediatr.* 1999;38(7):425–7. doi:10.1177/000992289903800709.
3. Pascuale MD, Espana E, Liu D, Kawakita T, Li W, Gao Y, et al. Correlation of Corneal Complications with Eyelid Cicatricial Pathologies in Patients with Stevens-Johnson Syndrome and Toxic Epidermal Necrolysis Syndrome. *Ophthalmology.* 2005;112(5):904–12. doi:10.1016/j.ophtha.2004.11.035.
4. Thorel D, Ingen-Housz-Oro S, Royer G, Delcampe A, Bellon N, Bodemer C, et al. Management of ocular involvement in the acute phase of Stevens-Johnson syndrome and toxic epidermal necrolysis: french national audit of practices, literature review, and consensus agreement. *Orphanet J Rare Dis.* 2020;15(1):259. doi:10.1186/s13023-020-01538-x.
5. Kohanim S, Palioura S, Saeed HN. Acute and Chronic Ophthalmic Involvement in Stevens-Johnson Syndrome/Toxic Epidermal Necrolysis - A Comprehensive Review and Guide to Therapy. II. Ophthalmic Disease. *Ocul Surf.* 2016;14(2):168–88.
6. Jain R, Sharma N, Basu S, Iyer G, Ueta M, Sotozono C, et al. Stevens-Johnson syndrome: The role of an ophthalmologist. *Surv Ophthalmol.* 2016;61(4):369–99. doi:10.1016/j.survophthal.2016.01.004.
7. Léauté-Labrèze C, Lamireau T, Chawki D, Maleville J, Taïeb A. Diagnosis, classification, and management of erythema multiforme and Stevens-Johnson syndrome. *Arch Dis Child.* 2000;83(4):347–52.
8. Maurya RP, Singh VP, Chaudhary S, Roy M, Srivastav T. Prevalence of severe dry eye disease in postmenopausal women in North India: A teaching hospital study. *Indian J Obstet Gynecol Res.* 2019;6(1):94–6. doi:10.18231/2394-2754.2019.0021.
9. Maurya R. Dry eye disease: An overview. *Indian J Clin Exp Ophthalmol.* 2018;4(4):433–4.
10. Kaido M, Dogru M, Yamada M, Sotozono C, Kinoshita S, Shimazaki J, et al. Functional Visual Acuity in Stevens-Johnson Syndrome. *Am J Ophthalmol.* 2006;142(6):917–22. doi:10.1016/j.ajo.2006.07.055.
11. Kawasaki S, Nishida K, Sotozono C, Quantock AJ, Kinoshita S. Conjunctival inflammation in the chronic phase of Stevens-Johnson syndrome. *Br J Ophthalmol.* 2000;84(10):1191–3.
12. Sotozono C, Ueta M, Norihiko Yokoi; Severe Dry Eye With Combined Mechanisms is Involved in the Ocular Sequelae of SJS/TEN at the Chronic Stage. *Invest Ophthalmol Vis Sci.* 2018;59(14):80–6.

**Author biography**

**Namrata Shree**, Post Graduate Trainee

**Baby Deka**, Associate Professor

**Rajneel Bhattacharjee**, Post Graduate Trainee

**Cite this article:** Shree N, Deka B, Bhattacharjee R. Severe dry eye associated with Steven Johnson Syndrome: A case report. *IP Int J Ocul Oncol Oculoplasty* 2021;7(2):225-228.