

Content available at: <https://www.ipinnovative.com/open-access-journals>

IP International Journal of Ocular Oncology and Oculoplasty

Journal homepage: <https://ijooo.org/>

Guest Editorial

Advances in the management of eyelid tumors

Kasturi Bhattacharjee^{1,*}, Aditi Mehta¹, Vatsalya Venkatraman¹

¹Dept. of Ophthalmic Plastic and Reconstructive Surgery and Oculofacial Aesthetics, Sri Sankaradeva Nethralya, Guwahati, Assam, India



ARTICLE INFO

Article history:

Received 08-06-2021

Accepted 12-06-2021

Available online 24-07-2021

© This is an open access article distributed under the terms of the Creative Commons Attribution License (<https://creativecommons.org/licenses/by/4.0/>) which permits unrestricted use, distribution, and reproduction in any medium, provided the original author and source are credited.

In the Indian population, sebaceous cell carcinoma is the most common malignant eyelid tumor, followed by basal cell carcinoma.¹ Squamous cell carcinoma involving the eyelid is less common than conjunctival squamous cell carcinoma. Malignant melanoma of the eyelid is least common amongst the four malignant tumors.

Sebaceous cell tumors can arise from meibomian glands, glands of Zeis, the caruncle, and the eyebrow skin with an inherent propensity of pagetoid spread with skip lesions and a map biopsy is essential during surgical excision. Basal cell carcinomas commonly involve the lower eyelid and medial canthus and can invade locally and into the orbit. Squamous cell carcinomas may arise de novo or from premalignant lesions like actinic keratosis and Bowen's disease. They can metastasize via lymphatic spread and a sentinel lymph node biopsy is indicated during surgical excision. Eyelid melanomas are rare and can arise de novo or from preexisting pigmented lesion.

Clinical clues are self-evident for certain lesions. Premalignant lesions pose a diagnostic dilemma. The gold standard is biopsy followed by histo-pathological examination. We discuss here the novel tumor markers, gene expression and recent diagnostic advances and their potential implications in management.

* Corresponding author.

E-mail address: kasturibhattacharjee44@hotmail.com (K. Bhattacharjee).

1. Advances for Benign Tumors

Propranolol for infantile haemangiomas: The first line FDA approved standard of treatment is oral propranolol (1.7mg/kg body weight).² Newer advances include 6 weekly doses intralesional propranolol (1mg/ml, 1 ml per centimeter of lesion with maximum of 5ml) and topical application of timolol maleate gel 2% for small localized tumors.

Carbon Dioxide pulse laser: Super pulse CO₂ laser of 10600 nm wavelength cause tissue photo ablation allowing for simultaneous cutting and hemostasis has become an effective and well tolerated therapeutic method for benign eyelid tumors.³ In orbital plexiform neurofibromatosis, CO₂ laser ablation gives better hemostasis and prevents the loss of natural tissue planes from the tumor's diffuse mode of growth.⁴

1.1. Advances for Malignant Tumors

1.1.1. Sebaceous cell carcinoma

The management of sebaceous cell carcinomas is primarily surgical with intraoperative frozen section along with a map biopsy. When the tumor involves the caruncle or a post septal spread is detected on clinical preoperative evaluation, imaging is mandated to look for orbital spread and, surgical resection along with loco-regional lymph node dissection is followed by adjuvant radiotherapy. Other indications for adjuvant therapy are intraepithelial invasion,

incomplete tumor excision, tumor size >20 mm, canthal and anterior orbital extension, and histopathological evidence of perineuritic, lymphatic, or vascular invasion. Neoadjuvant chemotherapy to downstage the disease prior to surgery may also be offered. The chemotherapeutic agents used are carboplatin and 5-fluorouracil.

Muir Torre syndrome (MTS), a subtype of hereditary nonpolyposis colorectal cancer syndrome (HNPCC), is associated with various benign and malignant neoplasms of the sebaceous glands and gastrointestinal, genitourinary as well as breast malignancies. MTS has been ascribed to mutations

in the DNA mismatch repair (MMR) genes MSH2 or MLH1 and is in close linkage to a locus on chromosome 2p.⁵ Expression of PD-1 and PD-L1 is also demonstrated in sebaceous cell carcinomas making it a good target for immunotherapy.

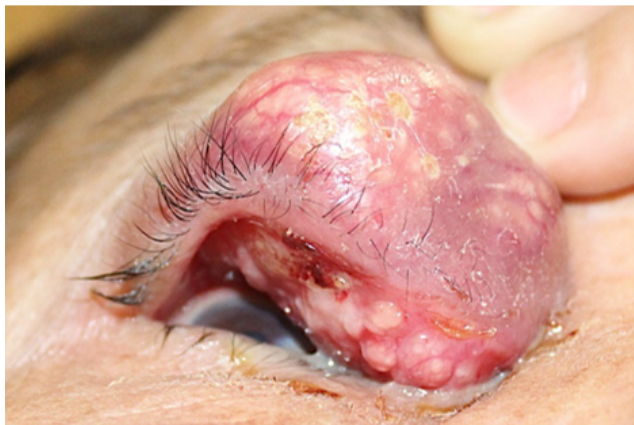

Fig. 1: Sebaceous cell carcinoma involving the entire upper lid

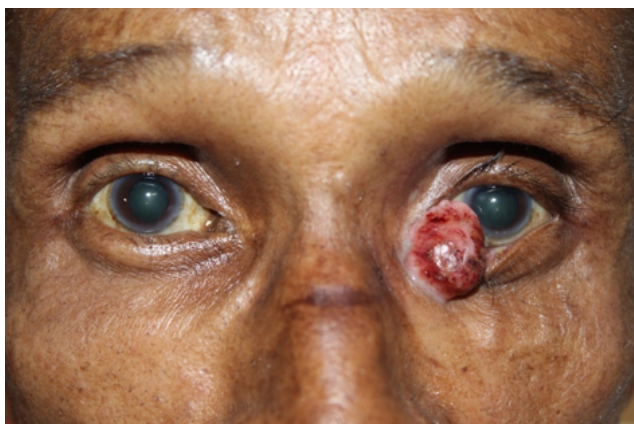


Fig. 2: Squamous cell carcinoma involving the medial canthus and lacrimal sac

1.1.2. Basal cell carcinoma

Although traditionally the treatment of choice for basal cell carcinoma is surgical excision, newer modalities of treatment for the same are gaining popularity. Vismodegib, a check point inhibitor of oral Hedgehog signaling pathway provides a new treatment option for locally aggressive or metastatic basal cell carcinoma in patients who are poor candidates for surgery. The Hedgehog signal transduction pathway plays an important role in cell proliferation and survival, through regulation of gene expression of PTCH1. Vismodegib suppresses the Hedgehog pathway, thereby blocking PTCH1 mediated tumor proliferation and leads to a decrease in tumor size and may even produce complete resolution. The dose is 150 mg per oral, once daily till resolution. The most common side effects are muscle spasms, alopecia, dysgeusia and anosmia, which can be managed by a 1 to 2 weeks' drug holiday.⁶ Oral sonidegib has also been found to have similar properties.⁷

Topical application of Imiquimod has high efficacy for low-risk basal cell carcinoma. Imiquimod is an immune modulator which stimulates innate and adaptive immunity to induce apoptosis in tumor cells. Administration is in the form of a 5% cream, applied once per day, five times per week for 8–16 weeks.⁸ Side effects include allergic conjunctival irritation and cutaneous erythema which resolve after discontinuing the therapy.

Photodynamic therapy (PDT) with topical methyl aminolevulinate is another safe and effective noninvasive treatment option that causes minimal collateral damage and leads to excellent cosmetic outcomes.⁹ Ocular shield needs to be placed before administering PDT to reduce the risk of phototoxic intraocular damage. Matrix metalloproteinases 1 and 13 have been found to have a role in the tumor progression and thus make for potential targets in the cancer therapy.¹⁰

1.1.3. Squamous cell carcinoma

Epithelial growth factor receptor (EGFR), is a transmembrane protein and activates the RAS/RAF/MEK/MAPK, PI3K/AKT and STAT pathways resulting in cellular proliferation with severe epidermal disorganization and invasion in both normal and malignant human skin.¹¹ Squamous cell carcinomas over-express the EGFR receptors and the EGFR inhibitors, such as cetuximab, gefitinib, panitimumab and erlotinib have been used either as monotherapy or in combination with systemic chemotherapy (cisplatin, methotrexate, 5 fluorouracil) in these lesions.¹² Other chemotherapeutic targets include the check point inhibitors- cemiplimab, nivolumab and pembrolizumab. These drugs target the PD-1 and PD-L1 (the receptor and its ligand) responsible for programmed cell death. Cancer cells overexpress PD-L1 which binds to a PD-1 receptor on T cells, inhibiting their activation and thereby suppressing effective T-cell cytotoxic response

against a tumor antigen.¹³

Ingenol mebutate, a plant derivative from the sap of *Euphorbia peplus*, in a dose of 150 µg/g gel, has been FDA approved for treatment of actinic keratosis and squamous cell carcinomas.¹⁴ It affects the PKC/MEK/ERK signalling pathway resulting in a reduction in the long-term viability of the cells and induction of programmed cancer cell death. Other topical chemotherapeutic agents include 5 fluorouracil (5%) and imiquimod 5% cream.

2. Malignant Melanoma

About half of all melanomas have changes (mutations) in the BRAF gene and the related target proteins, BRAF and MEK. Vemurafenib, dabrafenib and encorafenib are drugs that attack the BRAF protein directly.¹⁵ Drugs that block MEK proteins also produce a similar effect; MEK inhibitors include trametinib, cobimetinib and binimetinib. A small portion of melanomas have changes in the C-KIT gene. The targeted drugs for C-KIT include imatinib and nilotinib. Genetic testing on biopsy specimens can help identify these mutations in order to offer novel targeted therapy for these tumours. PD-L1 inhibitors (discussed above) are also used in metastatic melanoma.¹⁶

3. Source of Funding

None.

4. Conflicts of Interest

All contributing authors declare no conflict of interest.

References

1. Kaliki S, Bothra N, Bejjanki KM, Nayak A, Ramappa G, Mohamed A, et al. Malignant Eyelid Tumors in India: A Study of 536 Asian Indian Patients. *Ocul Oncol Pathol*. 2019;5(3):210–9. doi:10.1159/000491549.
2. Mehta A, Bajaj MS, Pushker N, Chawla B, Pujari A, Grewal SS, et al. To compare intralesional and oral propranolol for treating periorbital and eyelid capillary hemangiomas. *Indian J Ophthalmol*. 2019;67(12):1974–80. doi:10.4103/ijo.ijo_59_19.
3. Zhang J, Duan J, Gong L. Super pulse CO2 laser therapy for benign eyelid tumors. *J Cosmet Dermatol*. 2018;17(2):171–5. doi:10.1111/jocd.12375.
4. Lapid-Gortzak R, Lapid O, Monos T, Lifshitz T. CO2-laser in the removal of a plexiform neurofibroma from the eyelid. *Ophthalmic Surg Lasers*. 2000;31(5):432–4.
5. Rishi K, Font RL. Sebaceous Gland Tumors of the Eyelids and Conjunctiva in the Muir-Torre Syndrome. *Plast Reconstr Surg*. 2004;20(1):31–6. doi:10.1097/01.iop.0000103009.79852.bd.
6. Demirci H, Worden F, Nelson CC, Elner VM, Kahana A. Efficacy of Vismodegib (Eriedge) for Basal Cell Carcinoma Involving the Orbit and Periocular Area. *Ophthalmic Plast Reconstr Surg*. 2015;31(6):463–6. doi:10.1097/IOP.0000000000000388.
7. Hou X, Rokohl AC, Ortmann M, Heindl LM. Effective treatment of locally advanced periocular basal cell carcinoma with oral hedgehog pathway inhibitor? *Graefes Arch Clin Exp Ophthalmol*. 2009;258(10):2335–7. doi:10.1007/s00417-020-04779-5.
8. Shi Y, Jia R, Fan X. Ocular basal cell carcinoma: a brief literature review of clinical diagnosis and treatment. *Oncol Targets Ther*. 2017;10:2483–9. doi:10.2147/OTT.S130371.
9. Togsverd-Bo K, Wulf HC. Photodynamic Therapy for Tumors on the Eyelid Margins. *Arch Dermatol*. 2009;145(8):944–7. doi:10.1001/archdermatol.2009.157.
10. Mercuț IM, Simionescu CE, Stepan AE, Andreiana BC, Ciurea AM, Mercuț R, et al. The immunoeexpression of MMP-1 and MMP-13 in eyelid basal cell carcinoma. *Rom J Morphol Embryol*. 2020;61(4):1221–6. doi:10.47162/RJME.61.4.23. PMID: 34171070.
11. Yin VT, Merritt H, Esmali B. Targeting EGFR and sonic hedgehog pathways for locally advanced eyelid and periocular carcinomas. *World J Clin Cases*. 2014;2(9):432–8.
12. Girbardt C, Mößner A, Wiedemann P, Grunewald S. Therapiealternativen zur chirurgischen Versorgung maligner Lidtumoren und deren Vorläuferstufen [Therapeutic alternatives to surgical treatment of malignant eyelid tumors and their precursors. *Ophthalmologe*. 2020;117(5):478–83. doi:10.1007/s00347-020-01072-y.
13. Nagarajan P, El-Hadad C, Gruschus SK, Ning J, Hudgens CW, Sagiv O, et al. PD-L1/PD1 Expression, Composition of Tumor-Associated Immune Infiltrate, and HPV Status in Conjunctival Squamous Cell Carcinoma. *Invest Ophthalmol Vis Sci*. 2019;60(6):2388–98. doi:10.1167/iovs.19-26894.
14. Zarchi K, Jemec GB. Ingenol mebutate: from common weed to cancer cure. *Curr Probl Dermatol*. 2014;46:136–42. doi:10.1159/000366549.
15. Patel H, Yacoub N, Mishra R, White A, Yuan L, Alanazi S, et al. Current Advances in the Treatment of BRAF-Mutant Melanoma. *Cancers (Basel)*. 2020;12(2):482. doi:10.3390/cancers12020482.
16. Habib LA, Wolkow N, Freitag SK, Yoon MK. Advances in Immunotherapy and Periocular Malignancy. *Semin Ophthalmol*. 2019;34(4):327–33. doi:10.1080/08820538.2019.1620813.

Author biography



Kasturi Bhattacharjee, MS, DNB, FRCSEd, FRCS (Glasg), FAICO(Orbit & Oculoplasty) Director (Clinics and Academics) of Sri Sankaradeva Nethralaya, Guwahati and Head of the Dept. of Ophthalmic Plastic and Reconstructive Surgery and Oculofacial Aesthetics

Aditi Mehta, Fellow

Vatsalya Venkatraman, Fellow

Cite this article: Bhattacharjee K, Mehta A, Venkatraman V. Advances in the management of eyelid tumors. *IP Int J Ocul Oncol Oculoplasty* 2021;7(2):112–114.