



## Original Research Article

## Study of effect of amniotic membrane grafting in non healing corneal ulcer

Muhammad Iqbal Khan<sup>1,\*</sup>, Ram Kumar<sup>1</sup><sup>1</sup>Dept. of Ophthalmology, BRD Medical College, Gorakhpur, Uttar Pradesh, India

## ARTICLE INFO

## Article history:

Received 27-02-2020

Accepted 11-08-2020

Available online 03-09-2020

## Keywords:

Amniotic membrane grafting

Medical Therapy

## ABSTRACT

**Aims:** To evaluate effect of amniotic membrane grafting on non healing corneal ulcer and incidence of complications and recurrence of disease.

**Materials and Methods:** This would be an observational study with study period of one year involving 58 randomly selected patients with corneal surface disorder divided into groups, group A, patients control group (medical therapy) and group B, patients the study group (amniotic membrane grafting).

**Result:** Relief of symptoms was assessed under individual complains of pain, photophobia, foreign body sensation, watering, Redness and discharge. In Group-A out of 28 patients, 24(85.72%) showed complete relief of pain, 25 (89.28%) patients showed complete relief of photophobia, 26(92.85%) patients showed complete relief of foreign body sensation, 24(85.71%) showed complete relief of watering, 22(78.51%) patients showed complete relief of redness, 25(89.28%) showed complete relief of discharge. In Group-B, out of 30 patients, 29(96.6%) showed complete relief of pain, 27 (90%) patient showed complete relief of photophobia 28 (93.33%) patients showed relief of foreign body sensation, 27(90.00%) patients showed complete relief of watering, 28(93.33%) patients showed complete relief, 29(96.6%) showed complete relief of discharge. Statistically the difference is insignificant  $p < 0.05$ .

**Conclusion:** Amniotic membrane grafting definitely gives good symptomatic relief and re-epithelialization. Patients having AMG have short operative time and early improvement in symptoms, visual acuity and re-epithelialization than any other method of grafting.

© 2020 Published by Innovative Publication. This is an open access article under the CC BY-NC license (<https://creativecommons.org/licenses/by-nc/4.0/>)

## 1. Introduction

Cornea is a very delicate part of the eyeball and cannot tolerate the slightest insult. It is avascular and thus lacks the vascular support to fight any pathological damage caused by the attacking enemies which can range from slightest abrasion by eyelashes to disastrous microorganisms.<sup>1</sup>

The ultimate result of the corneal surface disorder is blindness either by destroying it or by leaving behind a scar which hinders the entrance of light rays. In the treatment of corneal surface disorder, the aim is to alleviate the discomfort of the patient and to have minimum amount of corneal opacity so that the visual defect is minimized. Though corneal grafting has come up as remedy to corneal blindness but it has its own limitations not only due to

the unavailability of the donor's cornea but also due to the limitation of tissue rejection. There are many observed clinical effects of using freeze-dried amniotic membrane grafting in corneal surface disorders-

1. Facilitate epithelialisation, maintain normal epithelial phenotype, reduce inflammation, reduce vascularisations, reduce scarring, reduce pain, reduce the adhesion of tissues, reduce apoptosis,<sup>2</sup> promotes formation of hemidesmosomal attachment to epithelial basement membrane.

Amniotic membrane transplant are indicated as graft for persistent corneal epithelial defect with or without ulceration, perforated corneal ulcer, symblepharon due to chemical injury.

In the present study an attempt has been made to make an evaluation of patients treated with freeze dried amniotic

\* Corresponding author.

E-mail address: [iqbalkhan86.ik@gmail.com](mailto:iqbalkhan86.ik@gmail.com) (M. I. Khan).

membrane grafting and medical therapy for symptomatic relief in the management of corneal surface disorders.

**2. Objectives**

To evaluate effect of amniotic membrane grafting on nonhealing corneal ulcer.

**3. Material and Methods**

This would be an observational study with study period of one year involving 58 randomly selected patients with corneal surface disorder divided into groups A (28) patients Control Group (Medical Therapy) Group B (30) patients the study group (amniotic membrane grafting)

The study has been carried out on the patients coming in the OPD of Dept. of Ophthalmology, Nehru Chikitsalaya, BRD Medical College Gorakhpur.

**3.1. Inclusion criteria**

- 1. Age-all age group, sex-Both male and female,
- 2. sterile case

**3.2. Exclusion criteria**

- 1. Infected case, Diabetic pt, Hypertensive pt

**3.3. Case selection**

All the patients who satisfied the inclusion criteria underwent complete ophthalmic evaluation. A proper consent was obtained and patients were selection after assessment

**3.4. Patient's personal data**

Name, Age/Sex, OPD/CR No., Case No., Education, Occupation, Address Clinical diagnosis, Date of follow up.

**3.5. Chief Complaints**

Pain, Photophobia, Foreignbody sensation, Redness, Itching, Burning, Watering Discharge, Defective vision, others

**3.6. Detailed history of present illness**

**3.6.1. Past Medical History**

History of any ocular Surgery/Trauma/Drug

History of Diabetes, TB or any other systemic disease

**3.7. Routine systemic examination**

CNS, RESPI, CVS, GIT

**3.8. Local examination of eye under torch light with special Reference to-**

Sign of inflammation, any growth, Edema/Swelling, Movements Any scar, others

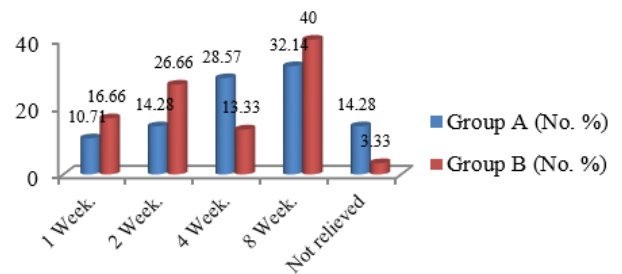
**3.9. Conjunctiva**

Any foreign body, Congestion, Any scar, any rowth, Symbplepheron, Others

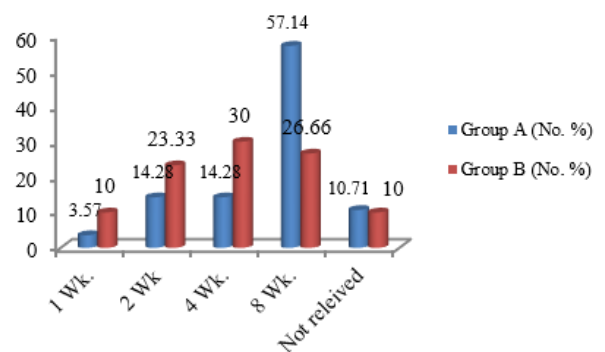
Cornea- Details of corneal disorder (by slit lamp after staining with fluorescein 2%)

Site-Pupillar /partial pupillar /outside papillary area

Size (extent)- <25%/25-50%. 50-75%/>75% of cornea.



**Fig. 1:** Pain after management



**Fig. 2:** Relief of photophobia

Depth- Epithelial/epithelial and superficial layers of stroma/impending perforation/full thickness (perforated) defect

**3.10. Transparency**

Haze/opacity, Sensation, Vascularization, Pigmentation,Others, Anterior Chamber, Depth, Contents

Visual acuity (by Snellen's Chart), IOP (by digital tonometry)

Lacrimal Sac examination by Regurgitation Test/syringing (as and when required) Tear film evaluation (in case of dry eye syndrome)

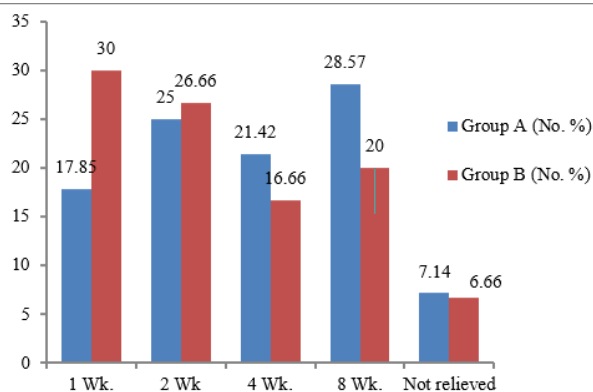


Fig. 3: Relief of F.B.sensation

**RELIEF OF WATERING**

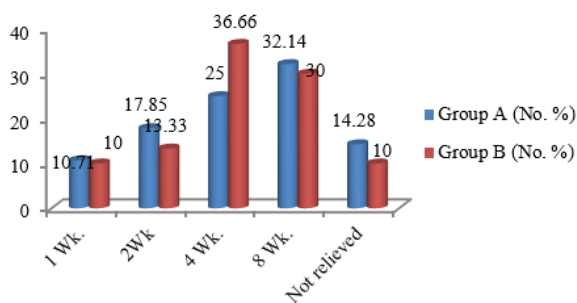


Fig. 4: Relief of watering

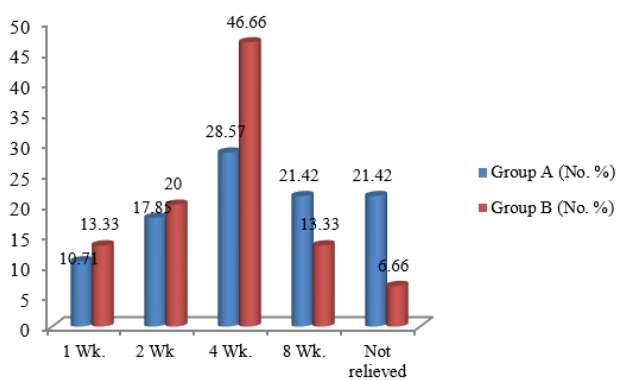


Fig. 5: Relief of redness

1. Schirmer’s test- Wetting in 5 min-

**4. Discussion**

The present study has been conducted on 58 patients of corneal surface disorders and was treated with amniotic membrane.

Grafting and topical drugs at Nehru Hospital attached to B.R.D. Medical College, Gorakhpur during the one year span of study.<sup>3</sup>

In the present study males (74%) outnumbered females (26%) in ratio of 2.84:1 may be because of working pattern of family where males usually are responsible for outdoor activities. M Dogru, M Yidiz, M Baykara, H Ozcetin and H Erturk, Department of Ophthalmology, Turkey applied a preserved amniotic membrane graft in a total of 10 eyes of 10 patients (7 male, 3 female) aged between 25 and 76 years. (mean 54.5+16.5 year) between April 2000 and April 2001 for persistent corneal epithelial defect with stromal ulceration and found that AMG can be helpful for the treatment of epithelial defects and stromal ulcer.

**5. Conclusion**

The study of effect of amniotic membrane grafting in nonhealing corneal ulcer" was conducted in upgraded Department of Ophthalmology, B.R.D. Medical College, Gorakhpur. The findings of the study are based on the observations made on 58 patients of corneal surface disorder.<sup>4</sup> All patients were divided in to two Groups-A and B of 28 and 30 patients respectively, using randomization by a computerized software. Group A received medical management, while Group-B received Amniotic membrane grafting with medical management.

Out of 28 patients in group A, 20(71.02%) had successful outcome and reported subsidence of symptoms. In group B out of 30 patients, 27(90.60%) had successful outcome.<sup>5</sup>

11 (19%) patients reported treatment failure. Among these 8 (28.0%) belonged to group A, while 3 (10%) belonged to Group B. However the difference between Group -A and Group-B is statistically insignificant (p value >0.05).

Visual acuity at presentation varied widely across both groups from only perception of light to + 1.000 Log MAR (Snellen’s equivalent= 6/60).

The average visual acuity at the end of 8th week were +0.8559 and +0.7687 for Group-A and B respectively.

However, as far as statistics are concerned, the difference between Group-A and B, was insignificant (p value >0.05).

Relief of symptoms was assessed under individual complains of pain, photophobia, foreign body sensation, watering, Redness and discharge.

In Group-A out of 28 patients, 24(85.72%) showed complete relief of pain. In Group-B, out of 30 patients, 29(96.6%) showed complete relief of pain. However,

statistically the difference between Group-A and Group-B is insignificant ( $p > 0.05$ ).

In Group-A 25 (89.28%) patients showed complete relief of photophobia. In Group-B out of 30 patients, 27 (90%) patient showed complete relief. Statistically the difference between both group is insignificant ( $p > 0.05$ ).

In Group-A, 26(92.85%) patients showed relief of foreign body sensation. In Group-B, 28 (93.33%) patients showed relief of this.

Statistically the difference between Group-A and Group-B is insignificant ( $p > 0.05$ ).

In Group-A. out of 28 patients, 24(85.71%) showed complete relief of watering, In Group-B. 27(90.00%) patients showed complete relief of watering. Statistically difference is insignificant. ( $P > 0.05$ )

In Group-A, 22(78.51%) patients showed complete relief of redness, in group B, 28(93.33%) patients showed complete relief. However, statistically the difference between two groups is insignificant.

In Group-A, out of 28 patients, 25(89.28%) showed complete relief of discharge while in Group-B, 29(96.6%) showed complete relief of discharge. Statistically the difference is insignificant.

Thus we concluded that, Amniotic membrane grafting definitely gives good symptomatic relief and re-epithelialization.

Patients having AMG have short operative time and early improvement in symptoms, visual acuity and re-epithelialization than any other method of grafting.

## 6. Source of Funding

None.

## 7. Conflict of Interest

None.

## References

1. Fernandes M, Sridhar MS, Sangwan VS, Rao GN. Amniotic Membrane Transplantation for Ocular Surface Reconstruction. *Cornea*. 2005;24(6):643–53.
2. Sangwas VS, Tseng SC. New perspectives in ocular surface disorders. An integrated approach for diagnosis and management. *Indian J Ophthalmol*. 2001;49:153–68.
3. Pellegrini G, Traverso CE, Franzi AT, Zingirian M, Cancedda R, Luca MD, et al. Long-term restoration of damaged corneal surfaces with autologous cultivated corneal epithelium. *Lancet*. 1997;349(9057):990–3.
4. Fukuda K, Tai-ichiro C, Nakamura M, Nishida T. Differential Distribution of Subchains of the Basement Membrane Components Type IV Collagen and Laminin Among the Amniotic Membrane, Cornea, and Conjunctiva. *Cornea*. 1999;18(1):73–9.
5. Grueterich M. Human Limbal Progenitor Cells Expanded on Intact Amniotic Membrane Ex Vivo. *Arch Ophthalmol*. 2002;120(6):783–90.

## Author biography

Muhammad Iqbal Khan Consultant

Ram Kumar Professor

Cite this article: Khan MI, Kumar R. Study of effect of amniotic membrane grafting in non healing corneal ulcer. *IP Int J Ocul Oncol Oculoplasty* 2020;6(3):200-203.