



Case Report

A classical case of cavernous hemangioma of the retina

T Premsai¹, Renuka Srinivasan¹, Hannah Ranjee Prasanth^{1,*}, Manoj Khatri¹,
Ishwarya T.S¹

¹Dept. of Ophthalmology, Pondicherry Institute of Medical Sciences, Pondicherry, India



ARTICLE INFO

Article history:

Received 11-01-2020

Accepted 12-02-2020

Available online 24-04-2020

Keywords:

Retinal cavernous hemangioma

vision loss

cluster of grapes

vision loss

Cluster of grapes

Saccular aneurysm

ABSTRACT

Cavernous hemangioma is a vascular hamartoma, composed of clusters of intraretinal aneurysms. It is usually unilateral, asymptomatic and rarely increase in size. Visual symptoms may occur due to macular involvement or vitreous hemorrhage.

© 2020 Published by Innovative Publication. This is an open access article under the CC BY-NC-ND license (<https://creativecommons.org/licenses/by/4.0/>)

1. Case Report

A 12-year-old female presented with gradually progressive, painless diminution of vision in her left eye for 1 year. On examination best corrected visual acuity in her right eye was 6/6 and left eye was 6/36. Her anterior segment examination was unremarkable. Left eye fundus examination - normal disc and vessels. At 3 DD temporal to disc, saccular grape like clusters of thin-walled angiomatic lesions was seen in the parafoveal region extending upto the ora serrata. (Figure 1) Periphery of the lesion showed chorioretinal atrophy that spilled on to the macula. (Figure 2). There was fibrous tissue at the periphery of the lesion near ora serrata (Figure 3). A clinical diagnosis of left eye cavernous hemangioma was made. A-Scan showed a high initial spike with high internal reflectivity.

B-Scan showed an irregular elevated hyperechoic lesion with no choroidal excavation. OCT Macula revealed thickening, multiple saccules with bridges in between them (Figure 4). Systemic examination by a pediatrician was

normal and MRA Brain was normal study.

2. Discussion

A hamartoma is a benign lesion consisting of normal tissues in an abnormal configuration. Cavernous hemangioma of the retina is a vascular hamartoma. It usually arises in the second decade of life and is more common in females.¹ Most cases of cavernous hemangiomas are sporadic, but they have been classified as part of Phakomatosis, which are multisystem disorders characterized by development of hamartomatous lesions involving CNS, skin and visceral organs in the body.

Cavernous hemangiomas are saccular aneurysms which are filled with venous blood. They mainly present between the 3 to 5th decade of life² (2) and account for 5 to 13% of vascular malformations.³ Typically the tumour is around 1-2 disc diameters in size and resemble “a bunch of grapes”. It may be an isolated lesion or it can fill the entire fundus. It may even follow the course of a major blood vessel. The lesion becomes symptomatic when it causes vitreous hemorrhage or when it is located on or next to the macula

* Corresponding author.

E-mail address: drranjee@hotmail.com (H. R. Prasanth).

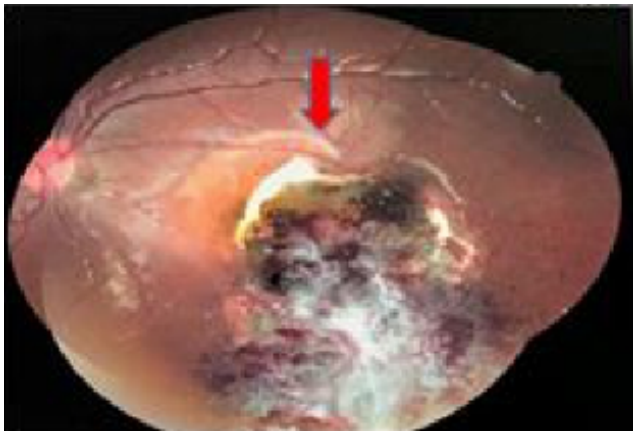


Fig. 3: Fibrotic tissue near the macula

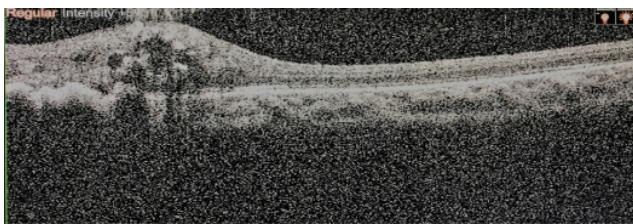


Fig. 4: OCT Macula showing sacculles with bridges between them

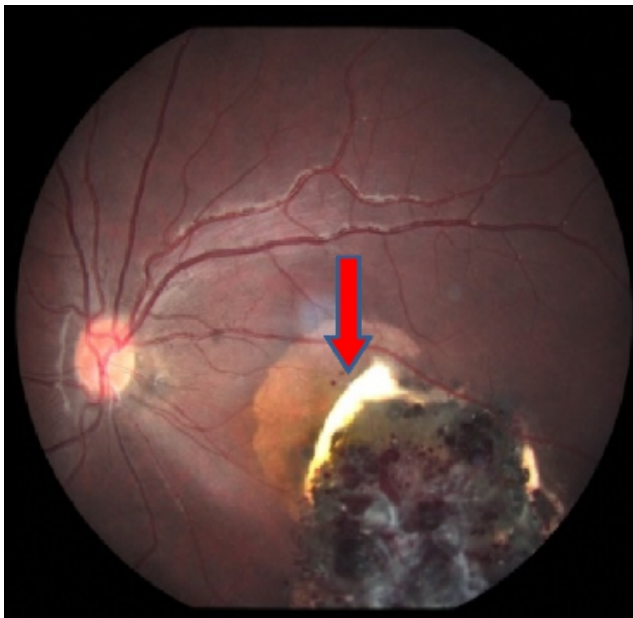

Fig. 1: Fundus image of left eye showing saccular grape like clusters of thin-walled angiomas was seen in the parafoveal region extending upto the ora serrate

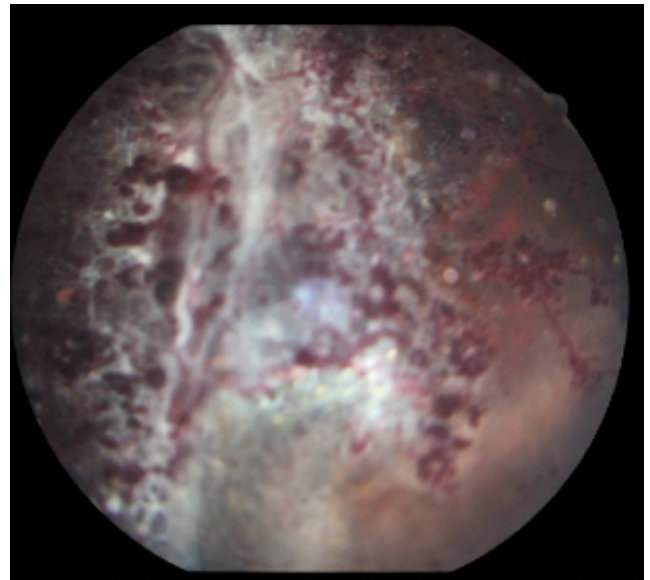


Fig. 2: Bunch of grape appearance with numerous dilated vessel and dot shaped intra-retinal hemorrhages

which has a reported incidence of 10% in literature.^{2,4} Similarly, lesions have been noted to occur on the optic nerve head. These patients had normal visual acuity with enlargement of the blind spot.⁵

Investigations like fluorescein angiography typically show slow filling of the aneurysm and plasma-erythrocyte separation which can be seen as pooling of the dye in the superior portion of the aneurysm. OCT usually demonstrates additional features like epiretinal membrane which can be present in the lesion. Other investigations like A-Scan shows high initial spike with high internal reflectivity and B-Scan demonstrates an irregular surface, large acoustic internal reflectivity and the absence of choroidal excavation.⁶

Periodic observation is advised in most cases as cavernous hemangiomas rarely increase in size or cause vitreous hemorrhage. Photocoagulation or cryotherapy is advised when vitreous hemorrhage occurs. Klein et al reported a case where the hemangioma increased in size following photocoagulation.⁷ In cases of non-clearing vitreous hemorrhage vitrectomy has proven to be beneficial.

3. Source of funding

None.

4. Conflict of interest

None.

References

1. Freidman, Kaiser PK. The Massachusetts Eye and Ear Infirmary - Illustrated clinical manual of ophthalmology. Boston, Massachusetts: Saunders Elsevier;. p. 465–477.
2. Messmer E, Laqua H, Wessing A, Spitznas M, Weidle E, et al. Nine Cases of Cavernous Hemangioma of the Retina. *Am J Ophthalmol.* 1983;95(3):383–390.
3. Maraire JN, Awad IA. Intracranial cavernous malformations: lesion behavior and management strategies. *Neurosurg.* 1995;37(4):591–605.
4. Naftchi S, la Cour M. A case of central visual loss in a child due to macular cavernous haemangioma of the retina. *Acta Ophthalmol Scand.* 2002;80(5):550–552.
5. Drummond JW, Hall DL, Steen W, Lusk JE. Cavernous hemangioma of the optic disc. *Ann Ophthalmol.* 1980;12(9):1017–1018.
6. Schachat A, Wilkinson C, Hinton D, Sadda S, Wiedemann P. Ryan's Retina. vol. 3. Elsevier;. p. 2421–2425.
7. Klein M, Goldberg M, Cotlier E. Cavernous hemangioma of the retina: report of four cases. *Ann Ophthalmol.* 1975;7(9):1213–1221.

Author biography

T Premsai Resident

Renuka Srinivasan Professor and HOD

Hannah Ranjee Prasanth Associate Professor

Manoj Khatri Visiting Consultant

Ishwarya T.S Senior Resident

Cite this article: Premsai T, Srinivasan R, Prasanth HR, Khatri M, Ishwarya T.S . **A classical case of cavernous hemangioma of the retina.** *IP Int J Ocul Oncol Oculoplasty* 2020;6(1):76-78.