



Original Research Article

Vitrectomy for the removal of intraocular foreign bodies: visual outcomes and prognostic factors

Kiran C. Patel¹, Parth D. Suthar², Abhishek H Shah², Mehul Patel², Somesh Aggarwal^{3,*}

¹GMERS Medical College, Himatnagar, Gujarat, India

²M & J WRIO, Government Eye Hospital, Ahmedabad, Gujarat, India

³M & J WRIO, Government Eye Hospital, Ahmedabad, Gujarat, India



ARTICLE INFO

Article history:

Received 24-01-2020

Accepted 27-01-2020

Available online 24-04-2020

Keywords:

Intraocular foreign body

Pars plana Vitrectomy

Penetrating ocular injury

Industrial hazards

ABSTRACT

Introduction: Penetrating ocular injuries with intraocular foreign bodies may result in severe visual loss. The posterior segment IOFBs are best treated by pars plana vitrectomy.

Aims: To correlate the shape, size and location of posterior segment intraocular foreign bodies with visual outcome and its prognostic factors.

Setting and Design: Tertiary care center of ophthalmology, Ahmedabad, India

Materials and Methods: This is a prospective study of 40 eyes of 40 patients who underwent Pars Plana Vitrectomy for the removal of posterior segment intraocular foreign bodies in Regional Institute of India. We studied the following parameters: age, gender, wound site, IOFB characteristics (shape, size, location), initial and final visual acuity.

Results: Among the study participants, 19 worked in factories, 6 were housekeepers, 7 were farmers and the remaining 5 patients were either unemployed or retired at the time of the injury. The foreign body was embedded in the surface of the retina (32.5%), located in the vitreous (55%) and in the sclera (12.5%). Nine patients (22.5%) developed delayed Retinal Detachment, which was the largest single cause of blindness in this group.

Conclusion : Our study concludes that the larger the size of posterior segment IOFB, presence of pre-existing or secondary RD, vitreous hemorrhage poorer the prognosis. We also emphasize the use of protective eye equipments at workplace in preventing this disability caused by penetrating ocular injury.

© 2020 Published by Innovative Publication. This is an open access article under the CC BY-NC-ND license (<https://creativecommons.org/licenses/by/4.0/>)

1. Introduction

Penetrating ocular injury with an associated retained intraocular foreign body (IOFB) is an important cause of blindness and ocular morbidity in the working age population. Among penetrating ocular injuries classified by Birmingham Eye Trauma Terminology System, ¹ injury due to sharp objects had a better visual prognosis than that associated with blunt objects. ²

Ocular injuries caused by IOFBs are often associated with corneal and scleral penetrating injury, hypheama, vitreous hemorrhage, lens injury, retinal damage or

detachment, and even more serious complications such as endophthalmitis ³⁻⁵ The objectives of this study were to identify the prognostic factors and evaluate the visual outcomes in posterior segment IOFB patients managed by pars plana vitrectomy (PPV). ⁶

Previous studies have described various aspects of penetrating ocular trauma, including demographic (Baker et al. 1996), ⁷ histopathological characteristics, clinical findings and visual outcome (Ahmadiet al. 1994). ⁸

In spite of this being one of the preventable health issues commonly seen around the world, unfortunately limited literature is available on the demography and epidemiological aspects of intraocular foreign bodies.

* Corresponding author.

E-mail address: dr.somesh@yahoo.com (S. Aggarwal).

Further, understanding the consequences of a maltreated, it becomes extremely important to address this issue in order to reduce its impact on the socioeconomics of the community.⁹

2. Materials and Methods

This is a prospective study carried out from January 1, 2015 to February 28, 2016 in 40 eyes of 40 patients who underwent PPV for the removal of posterior segment IOFBs in a tertiary referral care center of India. All ethical aspects have been taken due care of. This study included the patients with the foreign body in posterior segment, patients in whom IOFB extraction was not performed elsewhere and the follow-up period was 4 months or more. Those patients having perforating injuries (without IOFB), Anterior segment and corneal foreign body, previous history of ocular pathology and follow-up period less than 4 months after the injury were excluded.

History and Examination included the following:

1. Age and sex of the patient
2. Cause and mechanism of the injury
3. Snellen best corrected visual acuity
4. Intraocular pressure (IOP) measurement using applanation tonometry
5. Slit lamp biomicroscopy
6. Fundus examination by indirect ophthalmoscopy
7. Type, size (largest diameter) and location of the IOFB
8. Number of foreign bodies
9. Vitreous hemorrhage
10. Any retinal damage including retinal incarceration or detachment and types of retinal tears
11. Presence of endophthalmitis
12. Imaging like CT scan, X-ray, USG

After thorough evaluation, entry wounds were repaired under local anesthesia or general anesthesia as required followed by Pars Plana Vitrectomy for an intraretinal foreign body. Retinal tears were localized and treated with either laser photocoagulation or cryo-therapy. All of these patients were given oral antibiotic therapy i.e. fluoroquinolone for 7 days.

On follow up, post-operative Best-corrected Visual Acuity, Intra-ocular pressure, Fundus Examination, If needed: Ultrasonography, Complications if any were evaluated.

3. Results

Our study included 40 patients (40 eyes) with a minimum 4-month follow-up period (range: 4–24 months, mean: 12 months). There were 32 men (80%) and 8 women (20%). (Figure 1).

Their age varied from 12 to 69 years (mean- 34.2 years). (Table 1)

Considering the characteristics of the intraocular foreign bodies; the right eye was involved in 24 patients (60%), the left eye was involved in 16 patients (40%).

Among the study participants, 19 worked in factories, 6 were housekeepers, 7 were farmers and the remaining 5 patients were either unemployed or retired at the time of the injury. Three patients were children. (Table 2)

The IOFBs were sharp (45%), round (30%), or irregular (25%). IOFBs were metallic in 61% cases. (Figure 2)

The size of IOFB was defined by its largest diameter (mean: 2.5 mm, range: 0.5 to 8.5 mm). A single IOFB was present in 94% of the eyes.

The ocular findings at initial presentation were: corneal tear (68%), prolapse or damage of the iris (60%), hyphaema (40%), lens damage (45%), vitreous hemorrhage (54%) and retinal detachment (RD) (10%).

Pre-operative IOFB localization was done by orbital X-ray (30 patients, 75 %) or by computerized tomography scan (10 patients, 25%). The location of foreign body was in vitreous (55%), embedded in the surface of the retina (32.5%) or in the sclera (12.5%). (Figure 3)

Visual Acuity at presentation ranged from 6/6 to 'No Light Perception'.

3.1. Surgical management

Foreign body removal was attempted in each patient. PPV was performed within 7 days after the injury. All foreign bodies were successfully removed using this technique.

Traumatic cataract required pars plana lensectomy (13 cases, mean delay after trauma: 18 days), extracapsular cataract extraction with posterior IOL (2 cases, mean delay: 8 months) or phacoemulsification (3 cases, mean delay: 24 days).

3.2. Post-operative Complications

Traumatic cataract developed in 18 out of 40 patients (45 %). 10 of these 18 patients (55%) achieved a final VA better than or equal to 6/12.

Nine patients (22.5%) developed delayed RD. This complication was the largest single cause of blindness: final VA was worse than 6/60 in 78% of the cases. Vitreous hemorrhage (p=0.012) significantly correlated with secondary RD. (Table 3)

Two patients developed a traumatic glaucoma. None developed sympathetic ophthalmia, siderosis or chalcosis bulbi.

4. Discussion

Penetrating ocular injuries with intraocular foreign bodies (IOFBs) may result in severe visual loss. The aim of surgery is to restore the ocular integrity and obtain a good visual outcome.

Table 3: Prognostic factors of final VA

Factors		Number of eyes(%)	Final VA ≥ 6/60	Final VA < 6/60
Location of IOFB	Vitreous Retina Sclera	22(55%) 13(32.5%) 5 (12.5%)	13 (59%) 7(53.8%) 3(60%)	9(41%) 6(46.2%) 2(40%)
Shape of IOFB	Sharp Round Irregular	18(45%) 12(30%) 10(25%)	10(55.6%) 5(41.7%) 4(40%)	8(44.4%) 7(58.3%) 6(60%)
Size of IOFB	≤ 3 mm > 3 mm	33(82.5%) 7(17.5%)	23(69.7%) 1(14.3%)	10(30.3%) 6(85.7%)
Initial VA	≥ 6/60 < 6/60	12(30%) 28(70%)	12(100%) 11(39.3%)	0(0%) 17(60.7%)
RD	Primary Secondary	4(10%) 9(22.5%)	0(0%) 2(22.2%)	4(100%) 7(77.8%)
Iris Injury	Yes No	24(60%) 16(40%)	14(58.3%) 7(43.7%)	10(41.7%) 9(56.3%)
Lens Damage	Yes No	18(45%) 22(55%)	14(77.8%) 9(40.9%)	4(22.2%) 13(59.1%)

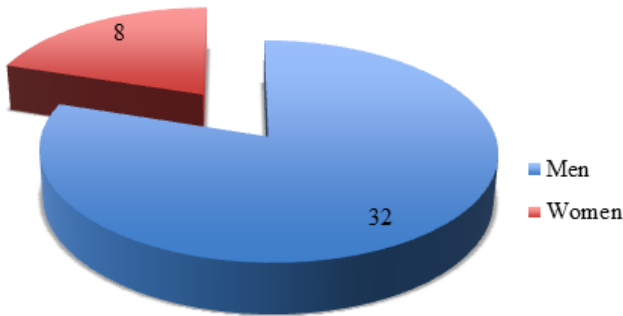


Fig. 1: Gender Distribution

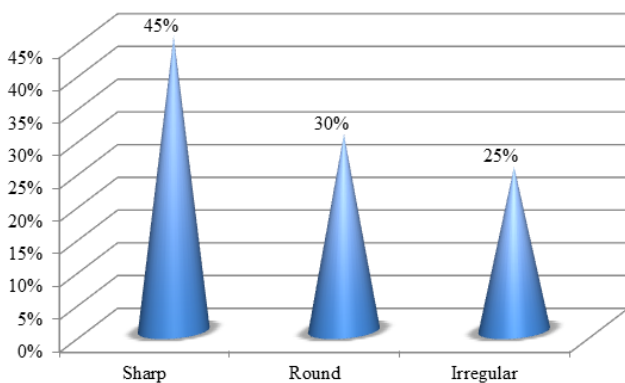


Fig. 2: Shape of IOFBs

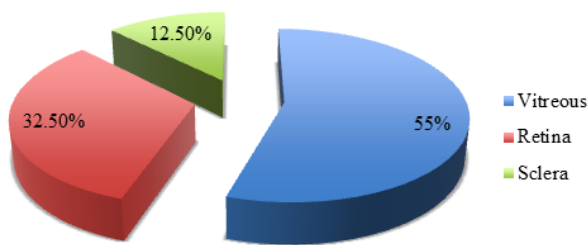


Fig. 3: IOFB Location

Table 1: Demographical data

Age group (years)	No. of Patients (%)
1-09	0 (0%)
10-19	6 (15%)
20-29	7 (17.5%)
30-39	13 (32.5%)
40-49	7 (17.5%)
50-59	5 (12.5%)
60-69	2 (5%)
Total	40

Table 2: Occupational Distribution

Occupation	No. of patients
Factory Workers	19 (47.5%)
Farmers	7 (17.5%)
Housekeepers	6 (15%)
Others	8 (20%)
Total	40

Several reports described the management of intraocular foreign bodies, but there is limited literature available on the demography and epidemiological aspects of posterior segment intraocular foreign bodies.

In a study conducted at Hong Kong by Candice C. H. Liu. There was a high male predominance (90 %). The mean age was 42 years. Work-related injuries (86 %) were the main cause, where only 10.5 % had eye protection. Most IOFBs were metallic (67 %). Our study had similar conclusions.¹⁰

The posterior segment IOFBs are best treated by pars plana vitrectomy.^{11,12} The current strategy is to carry out a PPV, and to decrease secondary complications by removing all proliferative mediators, and stabilization of the retina with removal of traction.

There are a few published studies in the literature for vitrectomy and posterior segment IOFB removal.

According to several reports (Ahmadiet al. 1994); clinical management of IOFB injuries using PPV may salvage the most severely injured eyes. Experimental studies have confirmed the effectiveness of PPV in the treatment of posterior segment trauma (Clearly & Ryan 1981),¹³ especially the prevention of tractional RD.⁸

Similar to our approach, most studies recommend the prompt removal of the IOFBs, within 24–48 h after trauma.^{14,15}

We found sharp foreign bodies as the most common type of IOFB. Round foreign bodies are difficult to remove, thus they are removed by “handshake” technique. The Internal limiting membrane (ILM) forceps is used to levitate the round foreign body to anterior vitreous cavity and subsequently another ILM forceps is used to align and remove it by handshake technique through the other port.

The size of IOFB is a significant predictive factor of poor visual outcome according to previous studies of IOFB removal.¹⁶ A large IOFB is more likely to inflict severe damage at the time of entry because of its higher kinetic energy, leading to a poor visual prognosis.¹⁶

In our series, the IOFB's were most commonly found within the vitreous. Final Visual Acuity being worse in those with intra-retinal foreign bodies, also suggested in similar other studies. An IOFB located close to the macula had poor visual outcome as compared to one located at the periphery of the retina.

In agreement with previous reports (Heimann et al. 1983; Karel & Diblik 1995), our results showed that RD was a crucial factor for poor visual outcome after IOFB injuries.¹⁷

5. Conclusion

This study highlights the demography of posterior segment IOFBs. Our study concludes that the larger the size of IOFB, presence of pre-existing or secondary RD, vitreous hemorrhage poorer the prognosis. The results of this study provide a series of high-risk conditions causing eye injuries, which would be better avoided. Education also needs to be given to industrial workers regarding use of protective eye equipments, which can prevent grave lifelong consequences.

6. Source of funding

None.

7. Conflict of interest

None.

References

1. Petrovic MG, Lumi X, Olup BD. Prognostic factors in open eye injury managed with vitrectomy: retrospective study. *Croat Med J.* 2004;45(3):299–303.
2. Warrasak S, Euswas A, Hongsakorn S. Posterior segment trauma: types of injuries, result of vitreo-retinal surgery and prophylactic broad encircling scleral buckle. *J Med Assoc Thai.* 2005;88(12):1916–1930.
3. Peyman GA, Raichand M, Goldberg MF, Brown S. Vitrectomy in the management of intraocular foreign bodies and their complications. *Br*

J Ophthalmol. 1980;64(7):476–482.

4. Alfaro DV, Roth D, Liggett PE. Posttraumatic endophthalmitis. Causative organisms, treatment, and prevention. *Retina.* 1994;14:206–217.
5. Chaudhry IA, Shamsi FA. Incidence and visual outcome of endophthalmitis associated with intraocular foreign bodies. *Graefes Arch Clin.* 2008;246:181–186.
6. Bencic G, Vatauk Z, Mandic Z. Novel approach in the treatment of intravitreal foreign body and traumatic cataract: Three case reports. *Croat Med J.* 2004;45:283–286.
7. Baker RS, Wilson MR. Demographic factors in a population-based survey of hospitalized, work-related, ocular injury. *Am J Ophthalmol.* 1996;122:213–219.
8. Ahmadi H, Sajjadi H. SURGICAL MANAGEMENT OF INTRARETINAL FOREIGN BODIES. *Retina.* 1994;14(5):397–403.
9. Négrel AD, Thylefors B. The global impact of eye injuries. *Ophthalmic Epidemiol.* 1998;5(3):143–169.
10. Liu CCH. Epidemiology and clinical outcome of intraocular foreign bodies in Hong Kong: a 13-year review. *Int Ophthalmol.* 2016;36(1):1–7.
11. Greven CM, Engelbert NE, Slusher SS. Intraocular foreign bodies. Management, prognostic factors and visual outcomes. *Ophthalmology.* 2000;107:608–618.
12. Chiquet C, Zech JC, Denis P, Adeleine P, Trepsat C, et al. Intraocular foreign bodies. Factors influencing final visual outcome. *Acta Ophthalmologica Scandinavica.* 1999;77(3):321–325.
13. Chiquet PE, Ryan SJ. Vitrectomy in penetrating eye injury. Results of a controlled trial of vitrectomy in an experimental posterior penetrating eye injury in the rhesus monkey. *Arch Ophthalmol.* 1981;99:287–292.
14. Roper-Hall MJ. Review of 555 Cases of Intra-Ocular Foreign Body with special reference to Prognosis. *British Journal of Ophthalmology.* 1954;38(2):65–99.
15. Mester V, Kuhn F. Ferrous intraocular foreign bodies retained in the posterior segment: management, options and results. *Int Ophthalmol.* 1998;22:355–362.
16. Wani VB, Al-Ajmi M, Thalib L. Vitrectomy for posterior segment intraocular foreign bodies: visual results and prognostic factors. *Retina.* 2003;23:654–660.
17. Heimann K, Paulmann H, Tavakoli U. The intraocular foreign body: principles and problems in the management of complicated cases by pars plana vitrectomy. *Int Ophthalmol.* 1983;6:235–242.

Author biography

Kiran C. Patel Assistant Professor

Parth D. Suthar 2nd Year Resident

Abhishek H Shah 2nd Year Resident

Mehul Patel Ex. Senior Resident

Somesh Aggarwal Professor and Head of Unit

Cite this article: Patel KC, Suthar PD, Shah AH, Patel M, Aggarwal S. Vitrectomy for the removal of intraocular foreign bodies: visual outcomes and prognostic factors. *IP Int J Ocul Oncol Oculoplasty* 2020;6(1):59–62.