



## Original Research Article

# A study of tumours and tumour like lesions in the Eye and its Adnexa: Our experience of 80 cases with review of literature

Somnath J Nandkar<sup>1</sup>, Bharat R Sonwane<sup>1,\*</sup><sup>1</sup>Dept. of Pathology, Government Medical College and Hospital, Aurangabad, Maharashtra, Aurangabad, Maharashtra, India

## ARTICLE INFO

## Article history:

Received 16-02-2020

Accepted 11-03-2020

Available online 24-04-2020

## Keywords:

Tumour  
Eyeball  
adnexa  
Tumour like

## ABSTRACT

**Introduction:** The eye is a unique special sensory organ which exhibits diverse histologic structures. Clinical signs symptoms of ocular malignancies simulate more commonly occurring benign conditions which pose great difficulties both for treating clinicians even experienced pathologists.

The present study is to evaluate the histomorphological spectrum of lesions of entire eyeball and ocular adnexa to compare our results with other studies.

**Materials and Methods :** The present study included the 80 cases of tumours tumour like lesions in the eye its adnexa, in our institute during June 2013 to October 2015.

All biopsies were embedded completely after thorough gross examination, resected specimens were noted for size, shape, consistency approximate section were taken. The enucleated eyeballs are sectioned according to stard protocols.

**Results:** In the present study, 80 cases of tumours and tumour like lesions in the eye its adnexa was carried. Out of these, eye lid was affected in 43 cases (53.75%), conjunctival cornea in 16 cases (20%), intraocular in 17 cases (21.25%) orbit in 4 cases (05%).

Among 80 cases maximum 44 cases (55%) were of malignant tumours followed by tumour like lesions 24 cases (30%) 12 cases (15%) of benign tumours.

**Conclusion:** Histopathological examinations of orbital ocular lesions are absolutely mandatory for definitive diagnosis and further management. Illiterate patient take some home remedies, which leads to complications and loss of eyesight. So awareness is needed to ensure early presentation.

© 2020 Published by Innovative Publication. This is an open access article under the CC BY-NC-ND license (<https://creativecommons.org/licenses/by/4.0/>)

## 1. Introduction

The eye is a unique sensory organ which exhibits diverse histologic structures. The knowledge of normal ocular anatomy spectrum of pathologic changes that involve these structures is necessary. The rarity at which these lesions occur complicates the recognition of their fine sometimes subtle presentation. Furthermore, clinical signs symptoms of ocular malignancies simulate more commonly occurring benign conditions which pose great difficulties both for treating clinicians experienced pathologists. Also, there exists a variation in pattern frequency on the basis of geographical locations.<sup>1</sup>

The present study is undertaken at our institute, to evaluate the histomorphological spectrum of lesions of entire eyeball and ocular adnexa, classify tumours tumour-like lesions of eye its adnexa on the guidelines of World Health organization and compare our results with other studies.

## 2. Materials and Methods

The present study included the 80 cases of tumours tumour like lesions in the eye its adnexa, in our institute during June 2013 to October 2015.

The surgical specimens were received for histopathological diagnosis, the clinical assessment; nature extent of lesion were studied in each case prospectively. Materials used for

\* Corresponding author.

E-mail address: bsonwane@gmail.com (B. R. Sonwane).

the histopathological study were received in 10% formalin. Specimen's received in the form of 1. Biopsy 2. Resected specimen 3. Enucleated eyeball.

2.1. Enucleated eyeball

1. Fix the intact ocular globe in formalin for 24 hours before sectioning.
2. Wash in running tap water for 1 or more hour optionally, place in 60% ethyl alcohol for few more hours.
3. Measure the anteroposterior, horizontal vertical dimensions of the globe, length of the optic nerve horizontal dimensions of the cornea.
4. Open the eye with sharp razor blade by holding the globe with left h, cornea down against the cutting block blade between the thumb middle finger of the right h. Open the eye with a sawing motion from back to front; the plane of the section should begin adjacent to optic nerve end through periphery of the cornea.
5. Examine the inferior of the globe.
6. Place the eye flat on its surface, make a second plane of section, parallel to the first, again passing from back to front.
7. Examine carefully the ~8mm disc shaped slab thus obtained, which should contain the cornea, pupil, lens optic nerve.<sup>31</sup> The sections were examined microscopically, special stain done wherever necessary.<sup>32</sup>

3. Observations and Results

The present study includes 80 cases of the tumours tumour like lesions in eye its adnexa from June 2013 to October 2015.

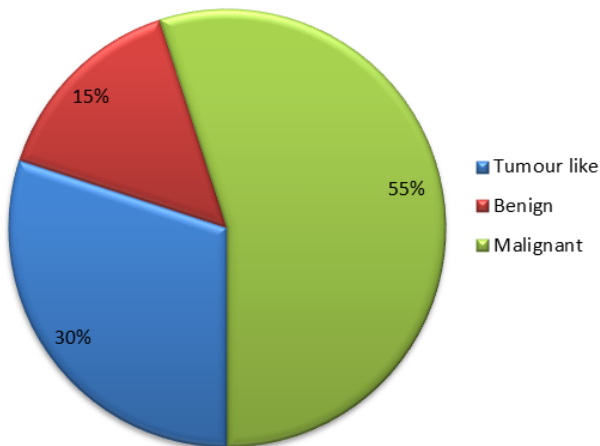


Fig. 1: Pie diagram Showing the lesion wise distribution of tumours tumour like lesions of eye its adnexa (n=80).

Maximum number of cases are of malignant tumours 44(55%) followed by tumour like lesions 24 (30%) benign tumour 12 (15%).

Table 1 shows that maximum number of cases were seen in the eyelid 43 (53.75%), followed by intraocular 17(21.25%), conjunctival cornea 16 (20%) minimum number i.e. 04 (05%) cases of orbit. No case of lacrimal gland its drainage system was found.

Table 2 Shows that males are more affected than female in tumour like benign lesions. While females are more affected than males in malignant tumours. Overall males are affected more than females in tumours tumour like lesions. Male to Female ratio is 1:09.

Table 3 shows that tumour like lesions are more frequently observed in 1<sup>st</sup> - 2<sup>nd</sup> decade benign lesions were common in 2<sup>nd</sup> decade (3 cases, 25%) followed by 5<sup>th</sup>,6<sup>th</sup> , 7<sup>th</sup>decade (2 cases each, 16.6%).

Malignant lesions were common in 1<sup>st</sup> decade (13 cases, 29.5%) followed by 4<sup>th</sup>, 5<sup>th</sup>decade (7 cases each, 15.9%).

Our study shows the maximum number of malignant cases occur in the 1<sup>st</sup> decade followed by 4<sup>th</sup> decade.

Study shows that, the common clinical presentation of patients in tumours tumour like lesions were the swelling over eyelid in 41 patients (51.25%) followed by swelling over conjunctiva cornea 16 patients (20%) ,diminution of vision in 24 patients (30%) proptosis in 14 patients (17.5%). Patients with malignant tumours show commonest presentation with proptosis diminution of vision in 30 patients (37.50%).

Retinoblastoma clinically presented with white pupillary reflex, proptosis diminution of vision. The patients of benign tumours of eye its adnexa clinically presented with swelling over eyelid 6 patients (7.5%), diminution of vision in 2 patients (2.5%), swelling over conjunctiva cornea 5 patients (6.25%) proptosis in 1 patient (1.25%). The patients of tumour like lesions clinically presented with swelling over eyelid 22 patients (27.5%), swelling over conjunctiva cornea in 1 patient (1.25%), proptosis in 3 patients (3.75%) diminution of vision in 2 patients.

Tumor Like Lesion: Inflammatory Pseudotumor

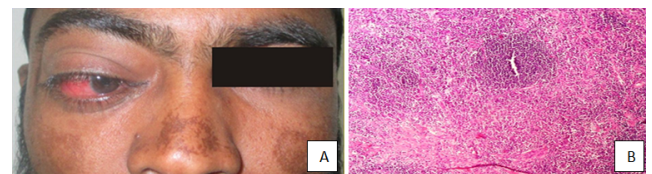


Fig. 2: A. Patient photograph showing diffuse swelling & redness of right eye. B: Photomicrograph showing extensive lymphocytic infiltrate forming germinal center like areas along with infiltration by polymorphs & eosinophils. [H & E 400X]

**Table 1:** Showing site wise distribution lesions (n=80).

Type of lesion	Eyelid	Conjunctiva Cornea	Intraocular	Orbit	Total
Tumours like	21	01	-	2	24
Benign	06	05	-	1	12
Malignant	16	10	17	01	44
Total	43(53.75%)	16(20%)	17(21.25%)	04(05%)	80 (100%)

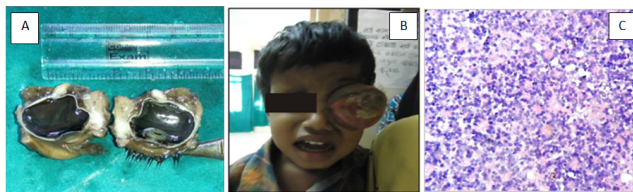
**Table 2:** Showing the sex wise distribution lesions (n=80).

Type of lesion	Male	Female	Total (Percentage)
Tumour like lesion	13	11	24 (30%)
Benign tumour	08	04	12 (15%)
Malignant tumour	20	24	44 (55%)
Total	41	39	80 (100%)

**Table 3:** Showing age wise distribution of lesions.

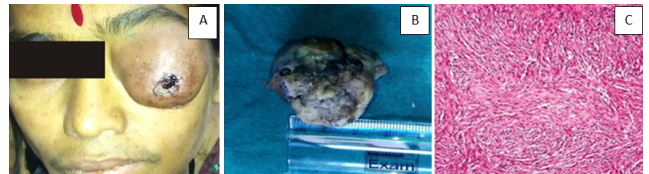
Age group (Years)	Tumour like		Benign		Malignant	
	No.	%	No.	%	No.	%
01-10	08	33.33%	01	8.3	13	29.5
11-20	08	33.33%	03	25.00	00	00
21-30	04	16.66%	01	8.3	04	9.09
31-40	00	00%	01	8.3	07	15.9
41-50	03	12.50%	02	16.6	06	13.6
51-60	00	00	02	16.6	07	15.9
61-70	01	4%	00	00	05	11.3
71-80	00	00	02	16.6	02	4.5
Total	24	100%	12	100	44	100

**Malignant Tumor: Retinoblastoma**



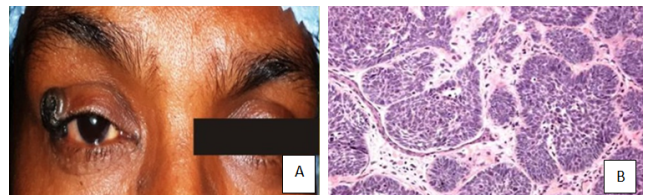
**Fig. 3:** A: Patient photograph showing 3 years old male child with gungating growth & proptosis in the left eye. B: Gross photograph of cut section of the eyeball with growth. C: Photomicrograph of section tumor mass showing round to oval cells with hyperchromatic nuclei & scanty cytoplasm forming rosettes. [H& E400X]

**Malignant Tumor: Malignant fibrous histiocytoma**



**Fig. 4:** A: Patient photograph showing growth in the left eye destroying the eyeball. B: Gross photograph of eyeball showing nodular greywhite tumour mass. C: Photomicrograph of section of tumour mass showing plump spindle cells with pleomorphic nuclei arranged in fascicles & storiform pattern [H & E 400X]

**Malignant Tumor:**



**Fig. 5:** A: Patient photograph showing pearly grey-black nodule over upper eyelid. B: Photomicrograph of section of nodule showing islands of basaloid cells with peripheral palisading & haphazard arrangement in the center [H & E 400X]

#### 4. Discussion

The present study of tumours tumour like lesions in eye its adnexa was done in Department of Pathology, Govt Medical College, Aurangabad (M S) India. We encountered 80 cases from June 2013 to October 2015.

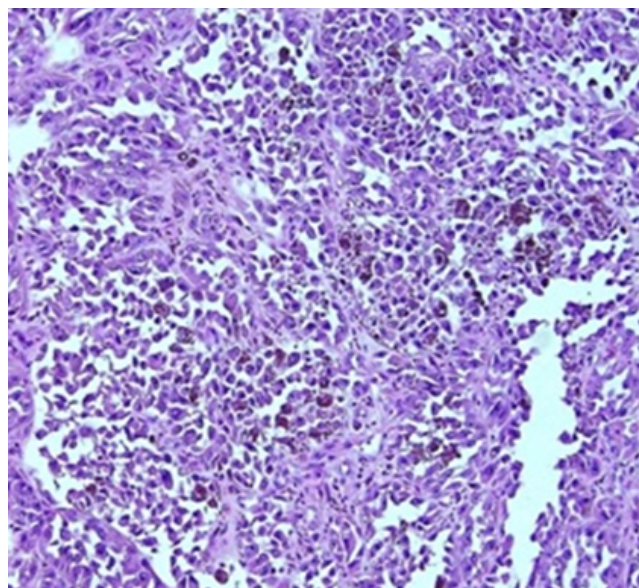
Of these 80 cases, malignant tumours are 44(55%) followed by tumour like lesions 24 (30%) benign tumour



**Table 4:** Shows comparison between types of lesions.

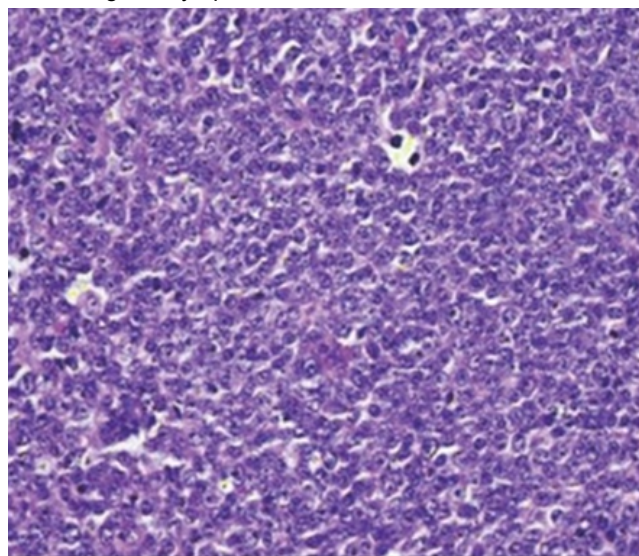
Type of Lesions	Reddy CS et al <sup>2</sup>	Halon A. et al <sup>3</sup>	Coroi M. et al <sup>4</sup>	Present study (2015)
Tumour like	24(26%)	336(16.54%)	114(24.20%)	24(30%)
Benign	45(50%)	1262(62.2%)	102(21.6%)	12(15%)
Malignant	20(22%)	433(21.3%)	255(54.2%)	44(55%)
Total	89(100%)	2031(100%)	471(100%)	80(100%)

**Malignant Melanoma**



**Fig. 6: A:** Photomicrograph showing sheets & groups of pleomorphic cells with melanin pigment & abundant cytoplasm also seen large pleomorphic & hyperchromatic nuclei [H & E 400X]

**Non-Hodgkins Lymphoma**



**Fig. 7:** Photomicrograph showing monomorphic population of round to oval cells with scanty cytoplasm and varying degree of plasma cellular differentiation [H & E 400X]

12 (15%), including 41 males (51%) 39 females (49%).

Our study is comparable with of the study of Coroi M. et al (2010).<sup>4</sup> While other two studies of Reddy CS. et al<sup>2</sup> and Halon A. et al<sup>3</sup> show variable range of lesions.

In our study male is more affected than female (1:09). This is comparable with studies of Reddy C.S et al,<sup>2</sup> Halon A. et al<sup>3</sup> Coroi M. et al.<sup>4</sup>

We found 13.7% cases of dermoid cyst. This is comparable to studies of Reddy C. et al,<sup>2</sup> Chauhan S. et al<sup>5</sup> Bastola P. et al<sup>6</sup> i.e. 14.60%, 12%, 12% respectively.

We noted 10% cases of epidermal cyst which is similar with studies of Domingo R. et al,<sup>7</sup> Chauhan S. et al<sup>5</sup> Bastola P. et al<sup>6</sup> i.e. 7.47%, 7.47% 10% respectively.

We found 2.5% cases of sebaceous cyst where Coroi M. et al<sup>4</sup> noted 6.3% cases which is nearer to our study.

We found 2.5% cases of inflammatory pseudotumour, while studies of Roh KK. et al,<sup>8</sup> Shaikh I. et al<sup>9</sup> Domingo R. et al<sup>7</sup> shows similar findings i.e. 2.8%, 2.31% 2.38% respectively.

Intradermal naevus was found in 1 patient (1.25%) variable incidence reported by other studies, because of less sample size studied.

Squamous cell papilloma was found in 1 patient (1.25%), Similar incidence of 2.8%, 2.77%, 2% 2% reported by Roh KK. et al,<sup>8</sup> Shaikh I. et al<sup>9</sup> Chauhan S. et al<sup>5</sup> Bastola P. et al (2013)<sup>6</sup> respectively.

Haemangioma was found in 4 patients (05%), which is nearer to incidence of 2%, 2.24%, 2.94% reported by Roh KK. et al<sup>2</sup>, Reddy C. et al<sup>2</sup> Domingo R. et al<sup>7</sup> respectively.

Lipoma was found in 1 patient (1.25%), while similar incidence of 2%, 0.9%, 1% 1% reported by Roh KK. et al,<sup>8</sup> Shaikh IY. et al,<sup>9</sup> Chauhan S. et al<sup>5</sup> Bastola P. et al<sup>6</sup> respectively.

So intradermal naevus is more common followed by squamous papillom, haemangioma lipoma in our study.

Pterygium was found in 4 patients (25%), while variable incidence of 10% reported by Elshazly L. et al.<sup>10</sup>

Basal cell carcinoma was found in 7 patients (8.75%). Similar incidence of 6 cases (10.2%) reported by Kumar R et al.<sup>11</sup>

Squamous cell carcinoma was found in 13 patients (16.25%). Similar incidence of 29 cases (13.42%) reported by Shaikh I. et al.<sup>9</sup>

Sebaceous carcinoma was found in 4 patients (05%). Similar incidence of 4.4%, 3.86%, 5% and 5% noted by Roh KK. et al,<sup>8</sup> Domingo R. et al,<sup>7</sup> Chauhan S. et al<sup>13</sup> Bastola P et al<sup>6</sup> respectively.

**Table 5:** Shows sex wise distribution of different lesions

Studies	Reddy C.S. et al <sup>2</sup>		Halon A.et al <sup>3</sup>		Coroi M. et al <sup>4</sup>		Present study (2015)	
	Male	Female	Male	Female	Male	Female	Male (n) and %	Female (n) and %
Tumour like	14 (15%)	10 (11.2%)	186 (9.1%)	150 (7.3%)	60 (12.7%)	54 (11.4%)	13 (16.2%)	11 (13.7%)
Benign	30 (33.7%)	15 (16.85%)	630 (31.0%)	632 (31.1%)	67 (14.2%)	35 (7.43%)	08 (10%)	04 (5%)
Malignant	8 (8.98%)	12 (13.4%)	200 (9.8%)	233 (11.4%)	132 (28.0%)	123 (26.1%)	20 (25%)	24 (30%)
Total	46 (51.6%)	43 (48.31%)	1016 (50.02%)	1015 (47.9%)	259 (54.9%)	212 (45.1%)	41 (51.2%)	39 (48.7%)
Ratio M:F	1:0.9		1:0.9		1:0.9		1:0.9	

**Table 6:** Malignant tumours of eye its adnexa.

Authors	BCC (n) and %	SCC(n) and %	Sebaceous Carcinoma(n) and %	Malignant Melanoma (n) and %	Retinoblastoma (n) and %	NHL(n) and %	Total
Roh KK. et al (1988) <sup>8</sup>	7 (2.8%)	2 (0.8%)	11 (4.4%)	19 (7.6%)	40 (16%)	-	250
Kumar R et al <sup>11</sup>	6 (10.2%)	39 (66.66%)	6 (10.2%)	3 (5.1%)	4 (6.77%)	-	59
Shaikh I. et al <sup>9</sup>	6 (2.77%)	29 (13.42%)	21 (9.72%)	8 (3.70%)	15 (6.94%)	8 (3.70%)	216
Domingo R. et al <sup>7</sup>	60 (3.86%)	76 (4.90%)	60 (3.86%)	38 (2.4%)	340 (21.9%)	59 (3.8%)	1551
Chauhan S. et al <sup>5</sup>	4 (4%)	6(6%)	5 (5%)	2 (2%)	27 (27%)	3 (3%)	100
Bastola P. et al <sup>6</sup>	4 (4%)	6(6%)	5 (5%)	2 (2%)	27 (27%)	3 (3%)	100
Present study (2015)	7 (8.75%)	13(16.25%)	4 (05%)	4 (05%)	13 (16.25%)	1 (1.25%)	80

Malignant melanoma was found in 4 patients (05%), similar incidence of 3 cases (5.1%) 8 cases (3.7%) reported by Kumar R et al,<sup>11</sup> Shaikh I et al.<sup>9</sup>

Retinoblastoma was found in 13 patients (16.25%), similar incidence of 40 cases (16%) reported by Roh KK et al.<sup>8</sup>

We found that retinoblastoma is most common malignant tumour followed by Squamous cell carcinoma, sebaceous carcinoma basal cell carcinoma.

The conjunctival corneal lesions were seen in 16 (20%) cases. While similar incidence of 20.37%, 22% 16% reported by Shaikh I. et al,<sup>9</sup> Chauhan S. et al<sup>5</sup> respectively 16% reported by Domingo R. et al.<sup>7</sup>

In our study intraocular tumours were having an incidence of 21.25%, which correlates with the study of Shaikh I. et al<sup>9</sup> Domingo R. et al<sup>7</sup> who noted incidence of 24.53% 25% respectively.

The orbital lesions comprise of 5% of all eye its adnexal tumours. The same finding of 3% reported by Reddy SC et al<sup>2</sup> 8% reported by Chauhan S. et al.<sup>5</sup> While variable incidence by Shaikh I. et al<sup>9</sup> Domingo R. et al<sup>7</sup> has reported 17.1% 24.07% incidence of primary orbital tumours.

Present study shows age incidence in 2 years to 75 years of age. Maximum number of cases of malignant tumours

was observed in first decade of life, because retinoblastoma occurs commonly in first decade of life. Similar findings had been reported by Reddy C.S. et al,<sup>2</sup> Das SP<sup>12</sup> Duke-Elder S.<sup>13</sup>

In the present study 41 cases (51.25%) were seen in males 39 cases (48.75%) in females which shows equal male to female ratio i.e. 1:0.9. Reddy C S. et al<sup>2</sup> Halon A. et al<sup>3</sup> Coroi M. et al<sup>4</sup> showing male female ratio 1:0.9, which is similar to present study.

#### 4.1. Tumours and tumour like lesions of eyelid:

In the present study, the tumours tumour like lesions of eyelid comprises of 43 cases (53.75%). Similar incidence is recorded by Reddy C.S. et al<sup>2</sup> Chauhan S. et al<sup>5</sup> who reported the incidence of (51%) (57%) respectively.

Out of 43 cases, tumour like lesions were 21 (26.25%) cases, benign tumours were 6 cases (7.55%) the malignant tumours were common having 16 cases (20%). Reddy C S. et al<sup>2</sup> studied 89 cases found 8(8.9%) of benign, 5 (5.6%) caese of malignant 32 (35.9%) cases of non neoplastic tumour like lesions in which tumour like lesions is more common than malignant benign lesions. Chauhan S. et al<sup>5</sup> observed that benign lesions were more common than

malignant lesions.

We found 25.58% cases of dermoid cyst, same is observed by Reddy C S.et al,<sup>2</sup> Bastola P.et al<sup>6</sup> who also found dermoid cyst in range i.e. 28.8% 21%, Roh KK.et al<sup>8</sup> shows variable finding i.e. 10(13.69%).

Similarly we found 18.6% cases of epidermal cyst which is comparable with studies of Bastola P.et al<sup>6</sup> who found 14%. Roh KK.et al<sup>8</sup> Reddy CS.et al<sup>2</sup> shows variable finding i.e. 2(3.8%) 4(8.8%) respectively.

We noted 4.6% cases of sebaceous cyst, similarly Coroi M. et al<sup>4</sup> who found 6.3% cases

Intradermal naevus was found in 1 patient (2.3%) of all lesions of eyelid. Variable incidence reported by above given studies.

Squamous cell papilloma was found in 1 patient (2.3%) of all lesions of eyelid. Similar incidence of 2.3% reported by Ramya BS. et al.<sup>14</sup>

Haemangioma was found in 4 patients (9.3%) of all lesions of eyelid. This is variable with the studies incidence of 3.8%, 4.4%, 18.6% 1.3% reported by Roh KK. et al,<sup>8</sup> Reddy CS.et al,<sup>2</sup>Ramya BS. et al<sup>14</sup> Domingo R. et al<sup>7</sup> respectively.

A case of haemangioma was reported in 2<sup>nd</sup> to 8<sup>th</sup> decade of life, similarly Aurora Boldi,<sup>15</sup> showing incidence of haemangioma in 1<sup>st</sup> decade to 6<sup>th</sup> decade of life. Among the eyelid benign tumours age incidence was more in 6<sup>th</sup> 8<sup>th</sup> decade of life.

Now the Basal cell carcinoma was found in 7 patients (16.27%), Similar incidence of 772 cases (15.49%) reported by Drepez et al.<sup>16</sup>

Squamous Cell Carcinoma was found in 3 patients (6.97%), Similar incidence of 10 cases (6.45%) 29 cases (6.97%) reported by Kumar R.et al<sup>11</sup> Domingo et al<sup>7</sup> respectively.

Sebaceous carcinoma was found in 4 patients (9.30%), Similar incidence of 5 (8.7%), 15(9.67%), 4(9.30%) 5(8.7%) reported by Chauhan S.et al<sup>5</sup>, Kumar R.et al,<sup>11</sup> Domingo R. et al,<sup>7</sup> Bastola P. et al<sup>6</sup> respectively.

It is noted that the commonest malignant tumour of eyelid is basal cell carcinoma, accounting for 75% Reddy C et al,<sup>2</sup> 21% Halon et al,<sup>3</sup> 69%Font et al,<sup>17</sup> 86% Deprez et al<sup>16</sup> (43.75%) in the present study.

The basal cell carcinoma to squamous cell carcinoma ratio in present study is 2.3:1. Similarly observed by Reddy C.S., et al<sup>2</sup>, Halon et al<sup>3</sup>, Font et al,<sup>17</sup> Deprez et al.<sup>16</sup>

The incidence of sebaceous carcinoma is (25%) which is variable finding of 14% of Font et al (1978).<sup>17</sup>

#### 4.2. Tumours and tumours like lesions of conjunctival cornea

16 cases of conjunctival corneal tumours tumour like lesions were found, comprising 20% of all eye tumours. Similar incidence of 20.37% 22.7% of eye tumours as reported by Shaikh I.et al,<sup>9</sup> Chauhan s.et al<sup>5</sup> Domingo et al<sup>7</sup> got 16%.

Out of 16 cases there was 01(1.25%) case of tumour like lesions, benign tumours were 05(6.25%) the malignant tumours were 10 (12.5%). Reddy C.et al<sup>2</sup> studied 45 cases of eyelid lesion found 2 (2.24%) of benign, 2(2.24%) cases of malignant 24(26.9%) cases of non neoplastic tumour like lesions in which tumour like lesions is more common than malignant benign lesions. Where as in our study malignant lesions more common than benign tumour like lesions. Chauhan S.et al<sup>5</sup> observed that benign lesions were more common than malignant lesions.

In malignant tumours age incidence ranged from 3<sup>rd</sup> decade to 7<sup>th</sup> decade. Sundarraj P. et al<sup>16</sup> reported an age incidence ranging from 4<sup>th</sup> to 8<sup>th</sup> decade. Male to female ratio reported by Das<sup>12</sup> is 2.3:1, while Sundarraj P. et al<sup>18</sup> reported 1.1:2 showing higher incidence in male, while in the present study the male to female ratio is 1:1.6.

Conjunctival cyst was found in 1 patient (6.25%) of all lesions of conjunctiva. Similarly reported by Roh KK.et al<sup>8</sup>, Chauhan s.et al<sup>5</sup> Bastola p.et al<sup>6</sup> .i.e. 2(4.6%), 1(4.5%) 1(4.5%) respectively.

In the present study age incidence of conjunctival cyst is in 1<sup>st</sup> decade, same is seen with Reese<sup>19</sup> Das,<sup>12</sup> with male predominance, similar to that of Sunderraj P. et al,<sup>18</sup> and Ash.<sup>20</sup>

Lipoma was found in 1 patient (6.25%) of all lesions of conjunctiva. Similar incidence of reported by Roh KK.et al<sup>8</sup> Ramya BS.et al<sup>14</sup> Shaikh I et al<sup>9</sup> i.e. 5(6.9%), 4(4.65%) 2(4.5%) respectively.

Pterygium was found in 4 patients (25%) of all lesions with variable incidence of 10% reported by Elshazly L.et al.<sup>10</sup>

Squamous cell carcinoma was malignant tumour found in 10 patients (62.5%) of all lesions of conjunctiva, Similarly 29 cases (65.90%) reported by Shaikh I et al<sup>9</sup> 31(52.54%) reported by Kumar R.et al.<sup>11</sup>

Squamous cell carcinoma is the single most common entity found in malignant tumours of conjunctiva cornea comprising 100% of conjunctival corneal malignancies. A similar incidence has been reported by Kumar R.et al,<sup>11</sup> Das<sup>12</sup> Sunderraj P. et al.<sup>18</sup>

The age incidence ranged from 3<sup>rd</sup> to 7<sup>th</sup> decade with an average age of 45 years, in the present study, similarly 44.3 years reported by Das.<sup>12</sup>

Male to female ratio reported by Ash Wilder<sup>20</sup> was 5.2:1 Das<sup>12</sup> reported male to female ratio being 17:1 but in the present study it is 0.2:1.

All patients presented with a small painless nodular swelling over conjunctiva, similarly it is reported by Reese,<sup>19</sup> Duke-Elder<sup>13</sup> Nath K and Gogi.<sup>21</sup>

In the present study 5 tumours were situated over the limbus it is the most frequently encountered site of carcinoma due to transition of epithelium as reported by Reese,<sup>19</sup> Duke-Elder<sup>13</sup> Nath K and Gogi.<sup>21</sup>

**Table 7:** Shows malignant lesions among total eyelid lesions.

Authors	Basal Cell Carcinoma	Squamous Cell Carcinoma	Sebaceous Carcinoma
Roh KK et al <sup>8</sup>	7(13.5%)	2(3.8%)	11(21.2%)
Reddy C, et al <sup>2</sup>	3(6.66%)	1(2.22%)	-
Drepez et al <sup>16</sup>	772(15.49%)	67(1.34%)	29(0.58%)
Chauhan S. et al <sup>5</sup>	4(7.01%)	1(1.7%)	5(8.7%)
Kumar R. et al <sup>11</sup>	9(5.80%)	10(6.45%)	15(9.67%)
Ramya BS. et al <sup>14</sup>	11(12.79%)	9(10.49%)	17(19.76%)
Domingo et al <sup>7</sup>	52(9.81%)	29(6.97%)	4(9.30%)
Bastola P et al <sup>6</sup>	4(7.01%)	1(1.7%)	5(8.7%)
Present study (2016)	7(16.27%)	3(6.97%)	4(9.30%)

**Table 8:** Shows malignant lesions among malignant eyelid lesions

Author	Basal Cell Carcinoma	Squamous cell carcinoma	Sebaceous carcinoma	Total Malignant lesions (n) and %
Reddy C, et al <sup>2</sup>	3 (75%)	1 (25%)	-	4 (8.88%)
Halon et al <sup>3</sup>	314 (21%)	-	-	433 (21%)
Font et al <sup>17</sup>	410 (69%)	28 (5%)	82 (14%)	594 (40%)
Deprez et al <sup>16</sup>	772 (86%)	67 (7%)	29 (3%)	894 (18%)
Present study (2015)	07 (43.75%)	03 (18%)	04 (25%)	16 (37.20%)

In the present study the intraocular extension was seen in a single case same is noted by Nath K and Gogi<sup>21</sup> Yanoff and Zimmerman.<sup>22</sup>

No tumour like lesions of lacrimal gl its drainage system was found in the present study, same has been reported by Das<sup>12</sup> Ryan Font.<sup>23</sup>

#### 4.3. Intraocular tumours and tumour like lesions

17 cases of intraocular lesions comprising of 21.25% of all eye its adnexal tumours, similar to the incidence of 24.53% 25% reported by shaikh I et al<sup>9</sup> Domingo R. et al<sup>7</sup> respectively.

Among all lesions of intraocular, the malignant tumours were 17(21.25%), Roh KK. et al<sup>8</sup> noted 49 cases found (19.6%) cases which is similar to our finding. Chauhan S. et al<sup>5</sup> observed 8(8%).

In the present study age ranges from 1 to 70 years, similar to age incidence reported by Das.<sup>12</sup> Males were more affected than females showing male to female ratio 1.4:1 which is similar to 1.5:1 reported by Das.<sup>12</sup>

In the present study retinoblastoma is the commonest malignant intraocular tumour having incidence of 76.47% of all intraocular tumours. Roh KK et al<sup>8</sup> reported 81% of retinoblastoma which is nearer to our study. Nath K and Gogi<sup>21</sup> reported 97.06% in his study, which did not match with our study.

The retinoblastoma comprises 23.5% of all eye adnexa tumours, which is nearer to 25% as reported by Belagavi.<sup>24</sup> Out of 17 intraocular tumours, 13 cases (76.47%) were of retinoblastoma, which indicate that it was the most common intra ocular tumour in the present study.

In the present study the age of youngest patient was 10 months eldest was 5 year. Maximum cases of retinoblastoma were observed in 2-3 4-5 years of age group in the present study. These findings are comparable with Dhir et al.<sup>26</sup>

Average age 3.3 years as observed in the present study is similar to 3.3 year reported by Belagavi,<sup>24</sup> 3.5 reported by Das.<sup>12</sup>

The present study showed male to female ratio 1.6:1. It is similar to that of Shrikande SS,<sup>27</sup> Dhir and Jain.<sup>26</sup>

In the present study proptosis was seen in 60.6%, same is noted by Dhir and Jain.<sup>26</sup> White pupillary reflex 65.6% was seen, which is similar to Howard et al,<sup>28</sup> impaired vision in 40%.

In the present study the right eye involvement was seen in 53.84% which is higher than the findings of other authors. Left eye involvement was seen in 38.46% of cases which is nearer to 35% as observed by Das<sup>12</sup> bilateral involvement was seen in 7.6% cases, same is noted by Munier F L et al.<sup>29</sup>

In our study we found 23.52% cases of malignant melanoma. This is comparable to studies of Shaikh I et al,<sup>9</sup> Chauhan S et al<sup>5</sup> who also found 15% and 15.38% respectively. Where as Domingo R et al<sup>7</sup> who also found 9.6% cases which is less than our finding.

In the present study the incidence ranges from 3<sup>rd</sup> to 7<sup>th</sup> decade. The average age of patients was 48 years as recorded by Duke-Elder.<sup>30</sup> Yanoff Zimmerman<sup>22</sup> recorded the average patient's age 56.3 years with a range from 27-84 years.

**Table 9:** Showing the comparison of age distribution of retinoblastoma in different studies.

Age in years	Devesa SS <sup>25</sup>	Dhir et al <sup>26</sup>	Present study(2015)
0-1	18	01	01
1-2	22	05	-
2-3	10	09	06
3-4	06	11	-
4-5	03	12	06
5-6	01	04	-
6-7	-	05	-
7-10	01	-	-

**Table 10:** Showing the comparison of site distribution in retinoblastoma

Authors	Right eye	Left eye	Bilateral
Das <sup>12</sup>	37.85%	35%	27.15%
Munier F L et al <sup>29</sup>	40.5%	52.2%	7.3%
Present study (2015)	53.84%	38.46%	7.6%

#### 4.4. Tumours and tumourlikelesions of orbit

In our study 4 cases (05%) of orbital tumours and tumour like lesions were found. Out of which 2 (2.5%) cases, we found benign malignant cases 1(1.25%) for each. As compared with Chauhan S. et al (2009)<sup>5</sup> who shows similar finding.

The age incidence ranges from 11 to 50 years maximum lesions were seen in the first four decades of life. This is similar with Yanoff Zimmerman.<sup>20</sup> Higher numbers of cases were found in males, similarly Das<sup>12</sup> Nath and Gogi<sup>21</sup> reported male predominance.

We found 50% cases of inflammatory pseudotumour. This is comparable to studies of Nath K. et al<sup>21</sup>, Roh KK. et al<sup>8</sup>, Shaikh I. et al<sup>9</sup> who also found variable percentage of cases of Inflammatory pseudotumour.

It constitutes 10-50% of all orbital lesions seen in 2<sup>nd</sup> 4<sup>th</sup> decade of life, presented with exophthalmos pain. Similar findings were reported by Narla L.D et al.<sup>31</sup>

In present study fibroma is benign tumour constituting 1.25% of all eye lesions appears in 10 year old child, similar finding was reported by Mortada A. et al.<sup>32</sup>

Our study shows that NHL was found in 1 patient (25%), similar incidence of 21.6%, 25.4% reported by Shaikh I. et al<sup>9</sup> Domingo R. et al<sup>7</sup> respectively.

In the present study the case was found in 4<sup>th</sup> decade of life with rapid unilateral proptosis. Showing female predominance, similar findings were observed by Essadi I et al.<sup>33</sup>

#### 5. Conclusions

The histopathological examination is absolutely mandatory for definitive diagnosis and management. The early diagnosis proper treatment of these tumours may predict favorable prognosis.

In general, early diagnosis prompt surgical intervention followed by radiotherapy chemotherapy can result in either

cure or good survival rates in ocular malignancies.

As the eye is the delicate important vital organ in the body, the special attention should be given in any form of functional or symptomatic abnormality with expert opinion which will preserve eye and its adnexa. Most of the patients came from rural area which are illiterate take home remedies, which may result in complications loss of eyesight.

#### 6. Source of funding

None.

#### 7. Conflict of interest

None.

#### References

- Vartak S, Neelakantan A. Urmi Chakravarty-Vartak Lesions of the Eyeball Ocular Adnexa - Our Experience Over A Period of 18 Months. *Ann Pathol Laborat Med.* 2019;6(7).
- Reddy SC, Das PK. Tumours tumour-like lesions of the eye: a clinicopathological study from Hospital University Sains Malaysia. *The Malaysian journal of pathology. Malays J Pathol.* 1996;18:113-120.
- Hałoń A, Błaziejewska M, Sabri H, Rabczyński J. Tumors tumor-like lesions of eyelids collected at Department of Pathological Anatomy. *Wroclaw Med Univ.* 2004;107(7-9):475-478.
- Coroi MC, G REM, Coroi T, Bonta M. Eyelid tumors: histopathological clinical study performed in County Hospital of Oradea between. *Roman J Morphol Embryol.* 2010;51(1):111-115.
- Chauhan SC, Shah SJ, Patel AB, Rathod HK, Surve SD, Nasit JG. A histopathological study of ophthalmic lesions at a teaching hospital. *Nat'l. J Med Res.* 2012;2(2):133-136.
- Bastola P, Koirala S, Pokhrel G, Ghimire P, Adhikari RK. A Clinico-Histopathological Study of Orbital and Ocular Lesions; a Multicenter Study. *J Chitwan Med Coll.* 2013;3(2):40-44.
- Domingo R, Manganip L, Castro R. Tumors of the eye and ocular adnexa at the Philippine Eye Research Institute: a 10-year review. *Clin Ophthalmol.* 2015;9:1239.
- Roh KK, Lee JH, Youn DH. Clinical analysis of tumors of the eye its adnexa. *Korean Journal of Ophthalmology.* 1988;2(1):27-31.



9. Shaikh IY, Shah FR, Ghi MB, Shah CK, Shah NR. Ophthalmic neoplastic lesions-A retrospective study of 4 years. *Orbit*. 2012;37:17.
10. Elshazly LM. A clinicopathologic study of excised conjunctival lesions. *Middle East Afr J Ophthalmol*. 2011;18:48.
11. Kumar R, Adhikari RK, Sharma MK, Pokharel DR, Gautam N. Pattern of ocular malignant tumors in Bhairahwa, Nepal. *Int J Ophthalmol Vis Sci*. 2009;7:1.
12. Das SP. Some observations on retinoblastoma. *Indian J Ophthalmol*. 1964;12(3):128.
13. Duke-Elder S, Macfaul PA. Diseases of the lacrimal passages. *Syst Ophthalmol*. 1974;13:675-724.
14. Ramya BS, Biligi DS, Chinmayee JT, Raghupathi AR. Tumours of the Eyelid- A Histopathological Study of 86 Cases in a Tertiary Hospital. *Int J Scientific Res Publications*. 2014;4(11).
15. Aurora AL, Blodi FC. Lesions of the eyelids: a clinicopathological study. *Surv Ophthalmol*. 1970;15(2):94-104.
16. Deprez M, Uffer S. Clinicopathological Features of Eyelid Skin Tumors. A Retrospective Study of 5504 Cases and Review of Literature. *Am J Dermatopathol*. 2009;31(3):256-262.
17. Font PL. Epithelial tumors of the lacrimal glands: An analysis of 265 cases. *Ocular Adnexal Tumors*. 1978;p. 787-805.
18. Sunderraj P. Malignant tumours of the eye and adnexa. *Indian J Ophthalmol*. 1991;39:6.
19. Reese AB. Tumours of the Eye; 1963.
20. Ash JE, Wilder HC. Epithelial Tumors of the Limbus\*. *Am J Ophthalmol*. 1942;25(8):926-932.
21. Nath K, Gogi R. Primary orbital tumours. *Indian J Ophthalmol*. 1977;25:10.
22. Yanoff M, Zimmerman LE. Histogenesis of malignant melanomas of the uvea.II. Relationship of uveal nevi to malignant melanomas. *Cancer*. 1967;20(4):493-507.
23. Ryan SJ, Font RL. Primary Epithelial Neoplasms of the Lacrimal Sac. *Am J Ophthalmol*. 1973;76:73-88.
24. Belagavi CS, Goravalingappa JP. Retinoblastoma: a clinicopathological study of 34 cases. *Indian Pediatr*. 1978;15:649.
25. Devesa SS. The Incidence of Retinoblastoma. *Am J Ophthalmol*. 1975;80:263-265.
26. Dhir SP, Jain IS, Dar GR, Gupta HD. Survival of retinoblastoma cases in North India. *Indian J Ophthalmol*. 1981;29:447.
27. Shirkande SS. Retinoblastoma in Indians. *Indian J Cancer*. 1966;3:57-67.
28. Howard GM, Ellsworth RM. Differential Diagnosis of Retinoblastoma\*. Elsevier BV; 1965. Available from: [https://dx.doi.org/10.1016/0002-9394\(65\)92248-8](https://dx.doi.org/10.1016/0002-9394(65)92248-8). doi:10.1016/0002-9394(65)92248-8.
29. Munier FL, Murphree AL, Arabian L, Flodman P, Spence MA, et al.. Putative non-Mendelian transmission of retinoblastoma in males: a phenotypic segregation analysis of 150 pedigrees. Springer Science and Business Media LLC; 1994. Available from: <https://dx.doi.org/10.1007/bf00211012>. doi:10.1007/bf00211012.
30. Duke-Elder, Ss. Degenerative pigmentary changes. *System of Ophthalmol*. 1977;3:569-585.
31. Narla LD, Newman B, Spottswood SS, Narla S, Kolli R. Inflammatory Pseudotumor. *Radio Graphics*. 2003;23(3):719-729.
32. Mortada A. Fibroma of the orbit. *Br J Ophthalmol*. 1971;55:350.
33. Essadi I, Tazi EM, Allam W, Sbitti Y, Ichou M, Erriani H. Primary non Hodgkin's lymphoma of the orbit: A case report. *Med Case Stud*. 2011;2(2):19-21.

### Author biography

**Somnath J Nandkar** Ex. Pg Resident

**Bharat R Sonwane** Associate Professor

**Cite this article:** Nandkar SJ, Sonwane BR. **A study of tumours and tumour like lesions in the Eye and its Adnexa: Our experience of 80 cases with review of literature.** *IP Int J Ocul Oncol Oculoplasty* 2020;6(1):1-9.