



Case Report

Rehabilitation of ocular defect with hollow ocular prosthesis

Vishvnathe Udayshankar^{1,*}, E Mahesh Gowda¹, Vijaya Kumar R¹, Vaibhav Jain¹

¹Dept. of Dental Surgery & Oral Health Sciences, Armed Forces Medical College, Pune, Maharashtra, India



ARTICLE INFO

Article history:

Received 12-11-2019

Accepted 05-12-2019

Available online 26-12-2019

Keywords:

Ocular defect

Hollow ocular prosthesis

Digital iris

Anterior segment

ABSTRACT

The loss of an eye creates huge psychological impact on individual's social and professional life. When surgical procedures like enucleation and evisceration removes the soft tissue contents of defective eye, abnormally large defect is created. The prosthetic rehabilitation of such large defect is always a challenge, which demands exactly matching, closely fitting, equally sized ocular prosthesis to replace lost tissue volume. This article attempts to present an innovative technique to fabricate an aesthetically superior hollow ocular prosthesis exactly matching with the natural eye of the patient.

Key Messages: Although there are various methods to fabricate hollow ocular prosthesis, utilizing silicon putty index and modelling wax. Anterior Segment Camera for iris selection is a simple and innovative technique which provides superior aesthetic and better comfort.

© 2019 Published by Innovative Publication. This is an open access article under the CC BY-NC-ND license (<https://creativecommons.org/licenses/by/4.0/>)

1. Introduction

The loss or absence of an eye may be due to trauma, infection, malignancy or congenital defects. The surgical procedures for removal of an eye can be broadly classified as evisceration, enucleation and exenteration. Such cases are usually managed with an artificial ocular prosthesis when all surgical options have been exhausted.^{1,2}

Ocular prostheses are either readymade (stock) or custom made. The custom -made ocular prosthesis provides better fit, close adaptation to tissue bed, optimum esthetics and less discomfort to patient. A solid ocular prosthesis would cause sagging of lower fornix due to its weight and asymmetrical alignment. Moreover, exact shade matching of sclera and iris is difficult to achieve aesthetic requirements.^{3–5}

This article suggests a new technique for selection of iris, sclera and fabrication of a hollow ocular prosthesis for rehabilitation of large ocular defects.

2. Treatment Procedure

The assessment of patient who had reported to division of prosthodontics revealed a post-surgery large residual ocular defect, complete drooping of upper eyelid, no palpebral opening, no ocular movements and missing visceral content of the affected eye [Figure 1]. A custom-made ocular impression tray was fabricated and impression was made using light body addition poly-vinyl-siloxane elastomeric impression material (Zhermack elite HD+). A stone cast was poured with gypsum material (Type-III Kalabhai R) by a split cast technique. The cast was initially poured with three indentation grooves and allowed to set. Final pour was made to obtain a split cast. Molten inlay wax was poured into the prepared split cast and casts were re-approximated to obtain ocular wax pattern [Figure 2].

An Anterior Segment Camera (HAAG Streit) was used to obtain a digital image of unaffected eye with the help of an ophthalmologist [Figure 3]. This camera provides quantitative information and qualitative imaging of the cornea, anterior chamber, iris and lens. A high-resolution digital image of iris was obtained and printed to the appropriate size on a high quality photographic paper. The cut out of this printed image was mounted onto iris

* Corresponding author.

E-mail address: vish.uday@gmail.com (V. Udayshankar).

button and secured firmly on iris disc with cyanoacrylate adhesive [Figure 4]. The iris button was mounted accurately onto the wax pattern, ensuring the correct gaze position during movement and at rest. Try in of wax pattern, investment and dewaxing was carried out. Two-millimetre thickness of poly-vinyl-siloxane putty was adapted in the slog portion of both the counterparts of flasks [Figure 5 a]. A Vernier calliper was used to ensure uniform thickness of silicon putty. The remaining space was filled with molten modelling wax (MAARCTM India) and flasks were approximated [Figure 5b]. The flasks were separated and borders of the putty were exposed by removing excess wax. The wax pattern and the putty indices were retrieved and a suitable shade (N1) of scleral white polymer (NAES India) was selected matching with unaffected eye. This was adapted on slog part of flasks where the silicon putty was adapted. The solidified modelling wax pattern was placed in between scleral polymer and flasks were approximated and bench cured for 30 minutes. The scleral polymer was processed as per manufacturer recommended protocol [Figure 6].

After curing cycle, flasks were separated carefully and prosthesis was retrieved. To make the prosthesis hollow, two holes were prepared on intaglio surface of the prosthesis on either side using straight fissure stainless steel bur and prosthesis was immersed into hot water to allow the modelling wax to soften and escape through these holes. Remaining residual wax was removed by flushing hot water from one of the escape holes using syringe [Figure 7]. The holes were then sealed with the scleral polymer.

The prosthesis was grossly finished and artificial veins and pigments were incorporated to mimic the blood vessels. The monomer-polymer syrup was prepared and applied on the entire surface of prosthesis to seal the characterized artificial veins. The prosthesis was then finished, polished and inserted to patient's ocular defect [Figure 8].

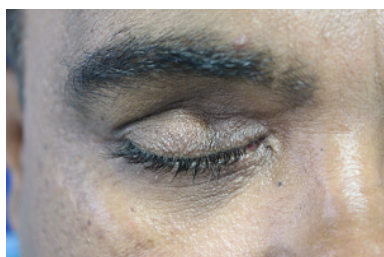

Fig. 1:

3. Discussion

An acceptable ocular prosthesis will improve the esthetics, self-confidence and social upliftment of the patient. Most authors advocates for the harmony between artificial eye prosthesis and natural eye to gain maximum aesthetic



Fig. 2:

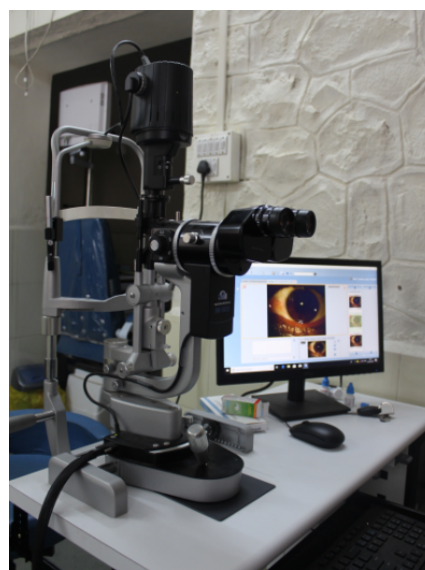


Fig. 3:

benefits. The color of the iris is the most successful parameter to satisfy patient's aesthetic demands from an ocular prosthesis.⁶ Many methods have been recommended for fabrication of artificial eye prosthesis in the literature. Stock eye prostheses are commercially available and also supported by Laney which is usually advocated when time and cost is a consideration.⁷ However, a large and expensive inventory of readymade prostheses is required to adequately select iris and sclera that resembles patient's unaffected eye. The required clinical and laboratory time is significantly less than the time required to make a custom ocular prosthesis, but the result is rarely the same⁸ with mismatch between



Fig. 4:

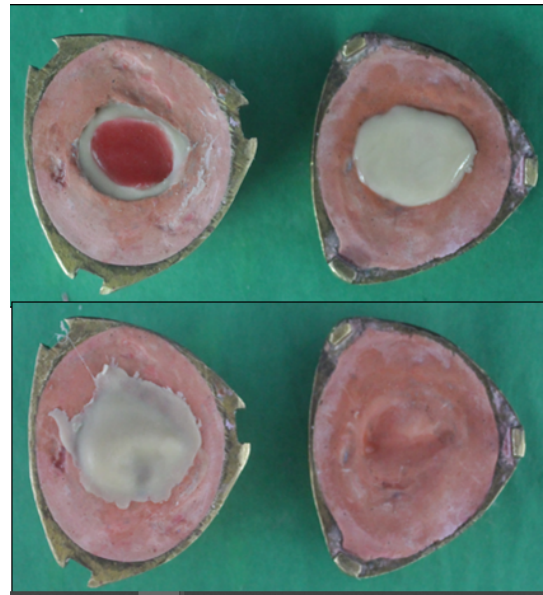


Fig. 6:

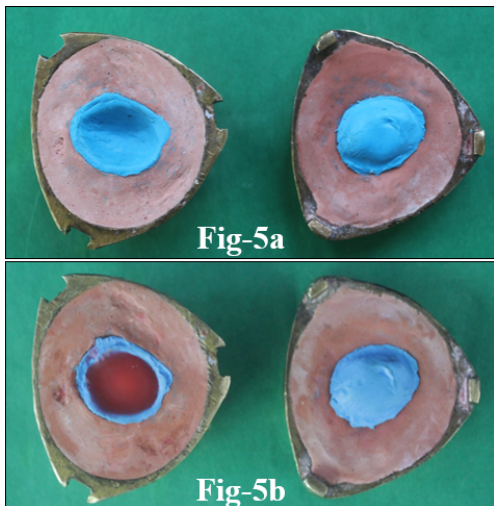


Fig. 5:

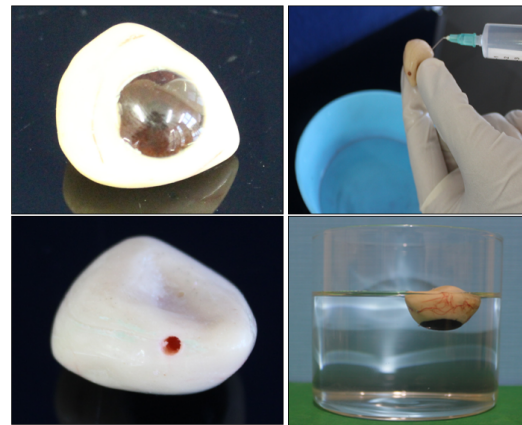


Fig. 7:

artificial and natural iris color.⁹ The other frequently used methods are black iris disk, paper iris disk and iris painting. But the procedure requires a combination of art and color skills.¹⁰

Making a digital image of the iris of unaffected natural eye is an innovative method. Artopoulou et al used a digital camera to obtain the image of iris. This technique is considered reliable but requires precise image adjustment by special computer software.^{11,12}

The anterior segment camera provides a diffuse, background illumination, shadow free, high resolution image of the iris with natural colors. The advantage is exact reproduction of iris. This image can be stored and used in case a new prosthesis is required to be made and also can be

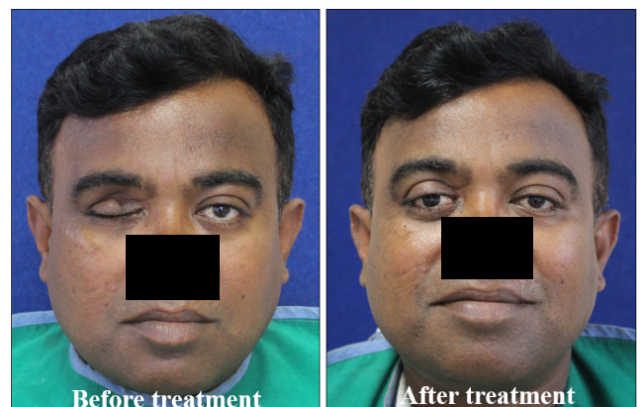

Fig. 8:

stored as a digital iris image library for use on other patients.

The technique also advocates for fabrication of a hollow ocular prosthesis using addition poly-vinyl silicone putty and modelling wax to develop a cavity within the prosthesis. Literature mentions various techniques in fabrication of hollow ocular prosthesis. Brito ER and Kavlekar AA used Styrofoam and Polymethyl methacrylate with lost wax technique.^{13,14} Warrell utilized mixture of sugar and egg white (caster sugar) in ratio of 1:5 to make the prosthesis hollow.¹⁵ However, none of these techniques allows uniform thickness of the prosthesis.

The technique utilizing silicon putty index and lost wax is a simple, innovative, feasible and cost-effective approach to overcome problems associated with the use of conventional bulky solid ocular prosthesis. Advantages of this technique includes maintenance of precise thickness of prosthesis, allows characterization of prosthesis post-fabrication and reduces weight by making it hollow without leaving any residues. It is also efficient in preventing lower lid distortion and/or asymmetrical alignment of palpebral fissure caused by conventional solid ocular prosthesis. In addition, being hollow, it also enhances comfort and mobility. The uniform thickness of the prosthesis, minimize the weight to a greater degree and ensure the desired strength of the definitive prosthesis.^{16,17}

4. Conclusion

The technique described here is rational and simple for fabrication of a light weight ocular prosthesis to rehabilitate large residual ocular defects. This also prevents lower lid distortion and/or asymmetrical alignment of the palpebral fissure associated with conventional solid ocular prosthesis.

5. Source of funding

None.

6. Conflict of interest

None.

References

1. Kale E, Mese A, Izgi AD. A technique for fabrication of an interim ocular prosthesis. *J Prosthet Dent.* 2008;17:654–661.
2. Perman KI, Baylis HI. Evisceration, enucleation, and exenteration. *Otolaryngol Clin North Am.* 1988;21:171–182.
3. Goel BS, Kumar D. Evaluation of ocular prosthesis. *J All India Ophthalmol Soc.* 1969;17(6):266–269.
4. Dakkak ME. Problem solving technique in ocular prosthetic reconstruction. *Saudi Dent J.* 1990;2(1):7–10.
5. Smith RM. Relining an ocular prosthesis: A case report. *J Prosthet Dent.* 1995;4(3):160–163.
6. Reis CR, Dias BR, Carvalho MCJ. Evaluation of iris color stability in ocular prosthesis. *Braz Dent J.* 2008;19(4):370–374.
7. Laney WR. Maxillofacial prosthetics ; 1979., p. 279–306.
8. Cain JR. Custom ocular prosthetics. *J Prosthet Dent.* 1982;48(6):690–694.
9. Taicher S, Steinberg MH, Tubiana I. Modified stock-eye ocular prosthesis. *J Prosthet Dent.* 1985;54:95–97.
10. Taylor DT. Clinical maxillofacial prosthetics, 1st edn. Chicago: Quintessence publishing Co., Inc ; 2000..
11. Artopoulou I, Montgomery CP, Wesley IP, Lemon CJ. Digital imaging in the fabrication of ocular prostheses. *J Prosthet Dent.* 2006;95:227–230.
12. Cevik P, Dilber E, Eraslan O. Different techniques in fabrication of ocular prosthesis. *J Craniofac Surg.* 2012;23(6):1779–1781.
13. Edias RB, Rezende JR, Carvalho JC. Light-weight ocular prosthesis. *Braz Dent J.* 1994;5:105–108.
14. Kavlekar AA, Aras MA, Chitre V. A light weight ocular prosthesis fabricated by a simplified technique: an eye in a day. *Int J Contemp Med Res.* 2016;3:1591–1593.
15. Worrell E. Hollow prosthetic eyes. *Ophthal Plast Reconstr Surg.* 2014;20:1–3.
16. Maskey B, Mathema SRB, Shrestha K, Bhochhibhoya AA. A simplified approach to fabricate a hollow ocular prosthesis. *J Prosthodontics.* 2018;p. 1–4.
17. Aggarwal H, Kumar P, Singh RD. A simplified method to fabricate a pneumatic ocular prosthesis for large ocular defects. *J Indian Prosthodont Soc.* 2014;14:106–109.

Author biography

Vishvnaathe Udayshankar Resident

E Mahesh Gowda Professor

Vijaya Kumar R Reader

Vaibhav Jain Resident

Cite this article: Udayshankar V, Gowda EM, Kumar R V, Jain V. Rehabilitation of ocular defect with hollow ocular prosthesis. *Int J Ocul Oncol Oculoplasty* 2019;5(4):267-270.