



Original Research Article

Autologous in situ blood coagulum as bioadhesive in preventing the recurrence of pterygium

K S Roopa^{1,*}, Shaik Gohar Firdous¹, Dodla Manaswini Lakshmi¹, R Sudha¹¹Dept. of Ophthalmology, Narayana Medical College and Hospitals, Nellore, Andhra Pradesh, India

ARTICLE INFO

Article history:

Received 15-11-2019

Accepted 05-12-2019

Available online 26-12-2019

Keywords:

Pterygium

Conjunctival Autograft

Bioadhesive

In situ blood coagulum

ABSTRACT

Aim: To evaluate the outcomes of pterygium excision with conjunctival autograft using autologous in situ blood coagulum.**Materials and Methods:** This is a prospective study of 50 eyes of 50 patients after taking informed consent, operated between May 2017 and October 2018 in the Department of Ophthalmology, Narayana Medical Hospital, Nellore. The study included 21 males and 29 females. Following pterygium excision, 1 mm oversized donor conjunctival graft was taken and placed over bare sclera, maintaining limbus to limbus polarity. The surgeon waited for 5-7 minutes to allow time for hemostasis and stabilization of graft.**Results:** Complications observed were graft edema in 4 cases (8%), graft retraction in 1 case (2%), subgraft haemorrhage in 2 cases (4%). Commonly encountered complications were subconjunctival haemorrhage, chemosis, congestion, discomfort, corneal scarring, corneal epithelial defects, and inadequate sized grafts. Recurrence or dehiscence were not noted.**Conclusion:** This study of using autologous blood coagulum for pterygium fixation showed this method to be more effective, less time consuming than suturing grafts, and more economical and free from the risk of contagious diseases compared to fibrin glue. The occurrence of very minimal complications and the swift resolution of any encountered complications makes this a superior approach.© 2019 Published by Innovative Publication. This is an open access article under the CC BY-NC-ND license (<https://creativecommons.org/licenses/by/4.0/>)

1. Introduction

Pterygium is a triangle shaped degenerative and hyperplastic process occurring medially and laterally in the interpalpebral aperture in which the bulbar conjunctiva encroaches onto the cornea.¹ Its prevalence rates vary widely from 2-29%,² and are higher in tropics than at temperate latitudes.^{3,4}

Pterygium is graded based on its extension over the cornea:

Grade I- Head upto limbus.

Grade II- Head between limbus and point midway between limbus and papillary margin.

Grade III- Head between a point midway between limbus and papillary margin and papillary margin.

Grade IV- Head crossing the papillary margin.

* Corresponding author.

E-mail address: dr.roopa.k.s@gmail.com (K. S. Roopa).

Many pterygia remain asymptomatic. Surgery is indicated when ocular irritation, discomfort, watering, foreign body sensation, photophobia, recurrent inflammation, reduced visual acuity due to obstruction of visual acuity or astigmatism (hypermetropic +0.75 to +1.5), cosmetic disfigurement, and/or diplopia due to restriction of ocular movements develop. Difficulty in contact lens fitting and performing corneal refractive surgeries are other indications for surgery.⁵

Most methods for small primary pterygium involve simple excision. For larger and recurrent pterygia, goal of treatment is to prevent recurrence. Recurrence rates of older techniques were high; 50% recur in 4 months and nearly all recurred in 1 year.⁶ Currently, most widely used techniques are conjunctival autografting and mitomycin C application.⁷ Human amniotic membrane grafts have also been shown to be effective.⁸ Fibrin based glues for conjunctival autografting have been used to minimize

operating time and post operative discomfort associated with sutures, and reduced the amount of suturing required.⁹

Although fibrin glue improved patient comfort and showed low recurrence rates compared to suturing, the risk of transmitted disease from pooled and single donor blood donors is a major drawback to its application.^{10,11} Hence, the novel approach of using the patient's own serum as bio-adhesive was chosen and outcomes were evaluated in our study.

The aim of the study is to evaluate the outcomes of pterygium excision with conjunctival autograft using autologous in situ blood coagulum.

2. Materials and Methods

Prospective study of 50 eyes of 50 patients operated between May 2017 and October 2018 in the Department of Ophthalmology, Narayana Medical Hospital, Nellore.

2.1. Inclusion criteria

Patients of all ages and both sexes with primary nasal pterygium were included in the study.

2.2. Exclusion criteria

Eyes with active infection or inflammation
 Temporal pterygium
 Recurrent pterygium
 History of previous ocular surgeries or trauma
 Pseudopterygium
 HIV/Hepatitis
 Bleeding disorders

Written and informed consent were taken from all patient. Pre-operative ocular examination was done, including refraction with best corrected visual acuity, slit lamp biomicroscopy, IOP measurement, and fundus examination.

2.3. Surgical techniques

All patients were operated by single surgeon under peribulbar anaesthesia. Under aseptic precautions, eye speculum was placed. Neck of the pterygium was lifted and peeled off along with head in a sweeping fashion. Body of pterygium was then separated from sclera beneath and excised, avoiding insertion of medial rectus muscle. Remnants of conjunctival tissue on cornea was scraped off using crescent blade in order to make the surface smooth. Size of bare sclera was measured using castorovjejo callipers. No cautery was used throughout the procedure and excess bleeding was avoided by using cotton bud as tamponade. Corneal care was taken using viscoelastic substances. Donor conjunctival graft was taken from superior conjunctival area. About 1 mm oversized graft was obtained, avoiding button holes and Tenon's capsule.

G raft was placed over bare sclera, maintaining limbus to limbus polarity, and the surgeon paused for 5-7 minutes to allow time for hemostasis and stabilization of graft. Graft was secured well and did not require suturing. The overall time taken for surgery was about 18 ± 2 minutes. Eye was then patched for the next 24 hours. Patch was removed the next day (first post-operative day) and assessed for symptoms like watering, pain, and foreign body sensation, and position of graft and any complications. E/drops Gatifloxacin 6 times/day and E/drops Prednisolone 6 times/day were prescribed, and tapered over the next 6 weeks. E/d Carboxymethylcellulose 1% 4 times/day for 6 weeks was used as lubricant. Patient was followed up later on 7th POD, 45th POD, and after six months. In each visit, patient was assessed for subgraft haemorrhage, graft edema, graft retraction, graft dislodgement, and recurrence. Distant visual acuity was recorded on the 45th POD.

3. Results

A total of 50 eyes of 50 patients underwent pterygium excision and conjunctival autograft with age between 20-60 years. The study included 21 males and 29 females (Table 1). Pterygia of Grade I-III were included in the study (Table 3). Most common indication of surgery is foreign body sensation (23), followed by cosmetic disfigurement (20), and visual impairment (7) (Table 3).

Complications observed were graft edema in 4 cases (8%), graft retraction in 1 case (2%), subgraft haemorrhage in 2 cases (4%) (Table 4), and no recurrence or dehiscence was noted. Other commonly encountered complications were subconjunctival haemorrhage, chemosis, congestion, discomfort, corneal scarring, corneal epithelial defects, and inadequate sized grafts. Excessive postoperative bleeding and gaping of the edges of the graft were not seen. Donor-site complications or transplant necrosis were not seen. These were not included in the results of the study because they are shared complications to conventional pterygium excision and may also be due to surgeon's error.

Table 1: Sex distribution of cases

	Number of cases
Males	21
Females	29

Table 2: Grading of pterygium included in the study

	Grade I	Grade II	Grade III	Grade IV	Total
Males	1	12	8	0	21
Females	3	16	10	0	29

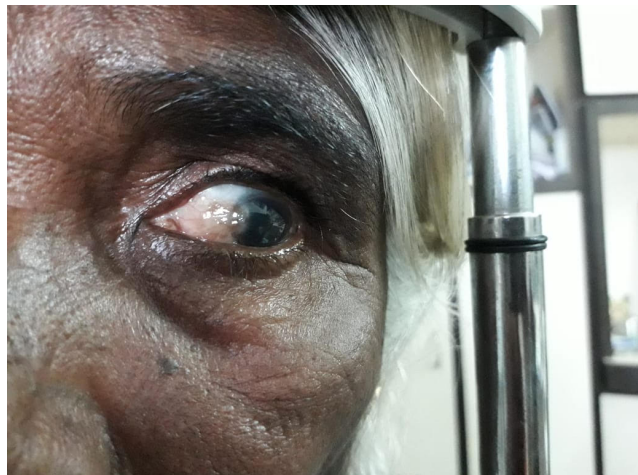

Fig. 1: Pre-op photograph of Grade II pterygium in a female patient

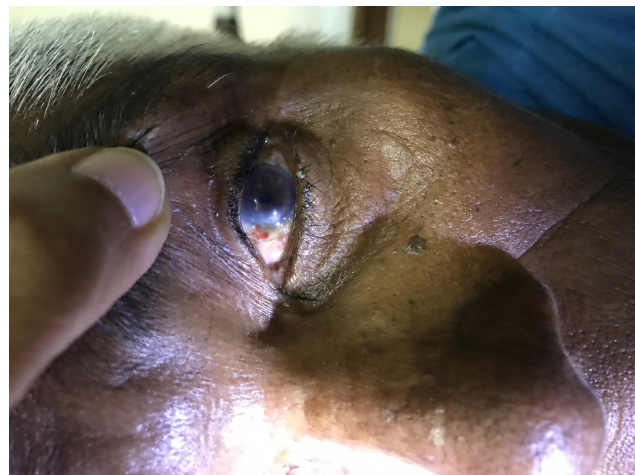

Fig. 4: 45th POD of the same patient showing resolved haemorrhage

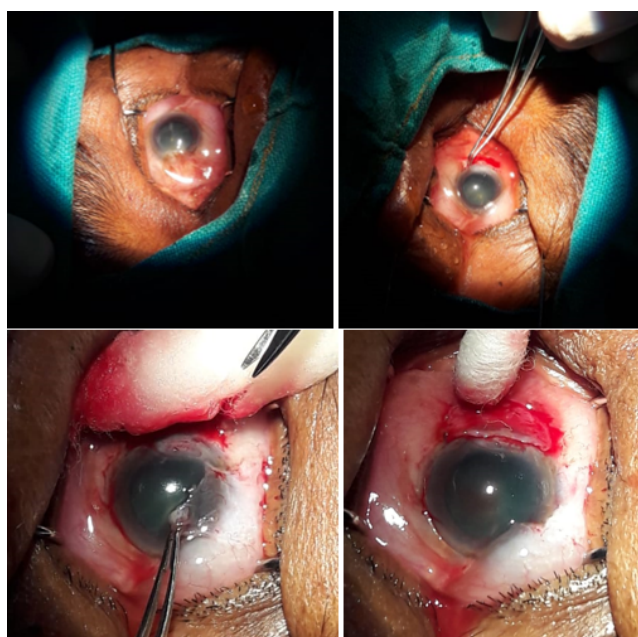


Fig. 2: Intra- op photographs of the same patient.

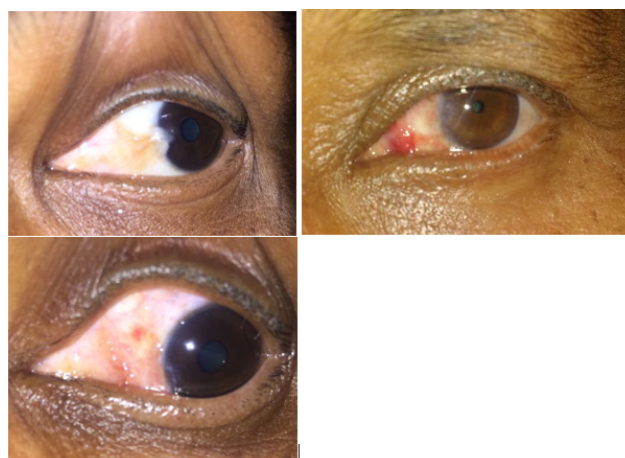


Fig. 5: Pre-operative, 7th POD, and 45th POD photograph of a female patient with Grade I pterygium.

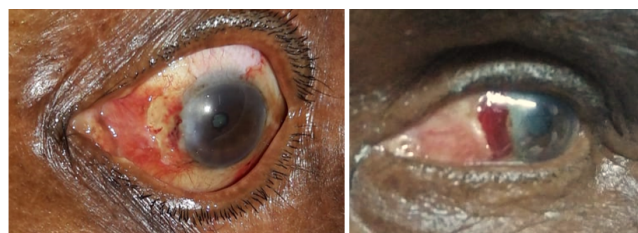


Fig. 3: First post-operative day and 7th POD of the same patient showing subgraft haemorrhage

Table 3: Indications for surgery

	Male	Female
Foreign body sensation	11	12
Cosmetic disfigurement	8	12
Visual impairment	2	5

Table 4: Complications observed during the study

	Male	Female	Total
Graft Edema	2 (4%)	2 (4%)	4 (8%)
Subgraft Haemorrhage	1 (2%)	1 (2%)	2 (4%)
Graft Retraction	-	1 (2%)	1 (2%)

Table 5: Improvement in visual acuity preoperatively vs. postoperatively (45th POD)

Lines of Snellen Acuity Changed	Number of cases	Percentage of cases (%)
-1	2	4
0	28	56
+1	11	22
+2	9	18

The majority of cases (56%) did not have improvement in distant visual acuity on 45th POD, most probably owing to the earlier grades of pterygia operated, which do not cross the pupillary border. 22% of cases showed a one-line improvement on Snellen's chart and 18% showed two lines of improvement, owing to relative relief from the previous astigmatism. Two cases showed a one-line reduction in Snellen's visual acuity, which may be attributed to excessive corneal scarring.

4. Discussion

The major hurdles of pterygium surgery in modern days are prevention of recurrences and complications, along with facilitation of speedy recovery post-operatively. Current surgical methods used to prevent recurrence are conjunctival autograft, limbal conjunctival autograft, conjunctival rotation autograft, amniotic membrane graft, lamellar keratoplasty and use of fibrin glue.¹² All the above techniques use sutures/fibrin glue and, therefore, are vulnerable to complications and dissatisfaction from the patient's side.

Suture related complications include infection, prolonged operating time, post operative discomfort, suture abscess, button holes, pyogenic granuloma, which usually requires a second surgery for removal, and chronic inflammation.^{13,14} Residual foreign body sensation of the operated eye is a drawback. Although fibrin glue avoids suture related complications, it carries risk of transmitting prion disease from the donor.^{10,11} Fibrin glue has been shown to be superior to sutures in securing a conjunctival autograft in terms of patient's comfort and lower recurrence rates.

Use of patient's own blood for fixation of a conjunctival autograft is a novel approach which prevents the above complications. None of the patients in our study showed recurrence. Studies reported by Kulthe et al¹⁵ and Sharma et al¹⁶ is comparable with our study. In Kulthe et al's study, 79 eyes were operated in a sutureless and glue-free surgical technique, there were no recurrences by the end of 6 months. Sharma et al operated on 50 eyes with primary pterygium using blood as a sealant and encountered no recurrences. Both studies support our study and statement that gluefree and sutureless approach is highly effective in preventing recurrences and cost effective by reducing the additional

surgical supplies and assistance needed.

In Mitra et al.'s study, 19 patients underwent graft fixation with autologous blood, and showed no losses or recurrences, similar to our study.¹⁷ Nadarajah et al, in a comparative study of autologous blood and fibrin glue usage in pterygium surgery, reported 2(3.4%) recurrences occurred in the fibrin adhesive method and 5(10.6%) recurrences occurred in the autologous blood method. However, this was not statistically significant¹⁸ in their study and, hence, did not rule out autologous blood as sealant in being effective in preventing recurrent pterygia.

Graft edema was noted in 4 patients on first POD, owing to excessive surgical manipulation, inclusion of Tenon's capsule in the graft, or poor graft orientation. This was, however, completely resolved at the 1 week follow up. Sub graft haemorrhage was noted in 2 patients on 7th POD which may be due to inadequate hemostasis of episcleral or conjunctival vessels, and gradually resolved by 4 weeks. One patient had graft retraction on the 7th POD which may be as a result of inadequate size of the graft, excess Tenon's tissue, or poor quality of graft, which resolved without any consequences. Although graft retraction was encountered, recurrence was not seen at 6 months postoperative time.

In Kumar et al's comparative study, postoperative discomfort was more in the suture group than the autologous blood group.¹⁹ Pterygium excision, being a relatively simple surgery, requires absolute complication-free outcomes and high patient satisfaction. Sutures, however effective they are in securing the grafts, fail in achieving this goal. Our study aims not only to prove that sutureless technique prevents long term complications, but also becomes the patients' approval.

Fibrin glue is an effective approach to attach the conjunctival autografts and prevent recurrences. However, the cost and availability of fibrin glue is a hindrance. Also, the risk of transmission of diseases poses a threat. No other major complications were noted in our study.

5. Conclusion

This study of using autologous blood coagulum for pterygium fixation showed this method to be more effective than suturing grafts and more economical and free from the risk of contagious diseases compared to fibrin glue. Moreover it is less time consuming with minimal complications and has excellent postoperative outcome, making it superior to other procedures.

6. Source of funding

None.

7. Conflict of interest

None.

References

1. Duke-Elders. St Louis – Textbook of Ophthalmology Mosby; 1954 ;.
2. Leonard P, Donald JL, T. Current Concepts and Techniques in Pterygium Management. *Curr Opin Ophthalmol.* 2007;18:308–313.
3. Gazzard G, Saw S, Farook M, Koh D, Widjaja D, Chia S. Pterygium in Indonesia: Prevalence, Severity and Risk Factors. *Br J Ophthalmol.* 2002;86:1341–1346.
4. Luthra R, Nemeasure B, Wu S, Xie S, Leske M. Frequency and Risk Factors for Pterygium in Barbados Eye Study. *Arch Ophthalmol.* 2001;119:1827–1832.
5. Smolin, Thofts. The Cornea – Scientific Foundations and Clinical Practice; Pterygium and its Surgery 999-1017 ;. .
6. Hirst LW, Sebban A, Chant D. Pterygium recurrence time. *Ophthalmol.* 1994;101:755–758.
7. Chen PP, Ariyasu RG, Kaza V. A randomized trial comparing mitomycin C and conjunctival autograft after excision of primary pterygium. *Am J Ophthalmol.* 1995;120:151–160.
8. Ma DH, See LC, Liau SB, Tsai RJ. Amniotic membrane graft for primary pterygium: comparison with conjunctival autograft and topical mitomycin C treatment. *Br J Ophthalmol.* 2000;84:973–978.
9. Uy HS, Reyes JMG, Flores JDG, Lim-Bon-Siong R, Comparison of fibrin glue and sutures for attaching conjunctival autografts after pterygium excision. *Ophthalmol.* 2005;112:667–671.
10. Everts PA, Knape JT, Weibrich G, Schonberger JP, Hoffman J, et al. Platelet-rich plasma and platelet gel; a review. *J Extra Corpor Technol.* 2006;38:174–187.
11. Alston P, Winge S, Karlsson G. Large-scale preparation of thrombin from human plasma. *Thromb Res.* 2008;122:560–567.
12. Ang LP, Chua JL, Tan DT. Current concepts and techniques in pterygium treatment. *Curropin Ophthalmol.* 2007;18:308–313.
13. Allan BD, Short P, Crawford GJ, Barrett GD, Constable IJ. Pterygium excision with conjunctival autografting: an effective and safe technique. *Br J Ophthalmol.* 1993;77:698–701.
14. Tan D. Conjunctival grafting for ocular surface disease. *Curr Opin Ophthalmol.* 1999;10:277–281.
15. Kulthe SB, Bhosale AP, Patil PU, Pandve HT. Is the Surgical Technique of a Sutureless and Glue-free Conjunctivo-limbal autograft after pterygium excision complications free? ;. Available from: <http://www.mjdrdyu.org/text.asp?2015/8/3/308/157069..>
16. Sharma A, Raj H, Gupta A, Raina AV. Sutureless and glue-free versus sutures for limbal conjunctival autografting in primary pterygium surgery: A prospective comparative study. *J Clin Diagn Res.* 2015;9:6–9.
17. Mitra S. Autoblood as Tissue Adhesive for Conjunctival Autograft Fixation in Pterygium Surgery; Poster Presented at the Annual Meeting of the American Academy of Ophthalmology; 22-23 October 2011 ;. .
18. Nadarajah G, Ratnalingam V, Isa HM. Autologous Blood Versus Fibrin Glue in Pterygium Excision With Conjunctival Autograft Surgery. *Cornea.* 2017;36(4):452–456.
19. Kumar S, Singh R. Pterygium excision and conjunctival autograft: A comparative study of techniques. *Oman J Ophthalmol.* 2018;11(2):124–128.

Author biography

K S Roopa Post Graduate

Shaik Gohar Firdous Post Graduate

Dodla Manaswini Lakshmi Post Graduate

R Sudha Professor

Cite this article: Roopa KS, Firdous SG, Lakshmi DM, Sudha R. Autologous in situ blood coagulum as bioadhesive in preventing the recurrence of pterygium. *Int J Ocul Oncol Oculoplasty* 2019;5(4):238-242.