



## Original Research Article

## Demography, clinical presentation and management of congenital blepharoptosis: A prospective interventional cohort study at a regional institute of ophthalmology in western India

Garima Agrawal<sup>1,\*</sup>

<sup>1</sup>Dept. of Oculoplastics and Ocular Oncology, M & J Western Regional Institute of Ophthalmology, BJ Medical College, Medicity, Ahmedabad, Gujarat, India



## ARTICLE INFO

## Article history:

Received 24-11-2019

Accepted 29-11-2019

Available online 26-12-2019

## Keywords:

Congenital blepharoptosis

Demography

Clinical presentation

Management

## ABSTRACT

**Introduction:** Congenital blepharoptosis is a common presentation to our out patient department. Congenital blepharoptosis may be myogenic, neurogenic, associated with misdirection of nerves. The study was designed to document the demography, clinical presentation and management of congenital blepharoptosis patients seen at our western regional institute of ophthalmology during the given study period.

**Aim:** The study was designed to document the demography, clinical presentation and management of congenital blepharoptosis patients seen at our western regional institute of ophthalmology during the given study period.

**Materials and Methods:** The study was carried out at our western regional institute of ophthalmology. The study was a prospective interventional study in an institutional cohort. The study period was one year from August 2018 to August 2019. Thirty five consecutive patients of congenital blepharoptosis seen at our western regional institute of ophthalmology were enrolled for the study. A thorough history and clinical examination was done. The type of blepharoptosis was identified and patients managed as per protocol.

**Results:** Myogenic ptosis due to a dystrophic levator muscle included 23 cases (65.71%) followed by Marcus gunn jaw winking synkinesis in six (17.14%) cases. Congenital myasthenia was documented in three (8.51%) cases. Third nerve palsy was seen in two (5.71%) cases and blepharophimosis syndrome in one case (2.86%).

**Discussion:** The results presented are similar to other studies. We report a predominant involvement of the right eye unilaterally (48.58%) as compared to the left eye unilaterally (25.71%). This finding is in sharp contrast to that reported from other studies. More studies would be required to determine the exact cause of this predominance.

We also noted a higher incidence of congenital myasthenia gravis in our patients as compared to other studies.

This enigmatic clinical entity is presented from our unique perspective. The study adds to and complements the world literature on the subject.

**Conclusion:** The study highlights the demographics, clinical profile and management of congenital blepharoptosis patients seen at a centre of excellence in western India.

© 2019 Published by Innovative Publication. This is an open access article under the CC BY-NC-ND license (<https://creativecommons.org/licenses/by/4.0/>)

### 1. Introduction

A child at birth whose eyes do not open completely or wink when the child feeds may be quite a distressing thing for the

parents of the child.

Congenital blepharoptosis is a common presentation to our out patient department. Congenital blepharoptosis may be myogenic, neurogenic, associated with misdirection of nerves. Simple congenital blepharoptosis is primarily myogenic associated with a dystrophic levator palpebrae

\* Corresponding author.

E-mail address: [garima.g.agrawal@gmail.com](mailto:garima.g.agrawal@gmail.com) (G. Agrawal).

superioris muscle which does not contract properly nor relax completely. Marcus gunn jaw winking phenomenon is another common presentation. Blepharoptosis is associated with jaw movements.<sup>1</sup>

Congenital blepharoptosis presents a unique clinical challenge to the ophthalmologist. The blepharoptosis may affect the vision of the child if accompanied by refractive errors, strabismus. Amblyopia may develop due to significant uncorrected refractive errors, strabismus or occlusion of the visual axis in that order of frequency. Notwithstanding the effect on vision, aesthetic concerns of a ptotic eyelid are also profound especially for the school going child or young adults looking for a life partner.

Childhood ptosis may in some cases be the indicator of an underlying systemic disorder as myasthenia gravis which needs to be managed.

A study into the demographics, clinical presentation and management of these cases of congenital blepharoptosis was the need of the hour to provide insights into the appropriate management and current practice protocols.

We designed a study to document the demography, clinical presentation and management of congenital blepharoptosis patients seen at our regional institute of ophthalmology. The study is a prospective interventional, demographic and outcome study in an institutional cohort. It highlights the spectrum of this clinical disorder in western India. The research provides an insight into the presentation and management of congenital blepharoptosis from our unique perspective.

## 2. Aim

The study was designed to document the demography, clinical presentation and management of congenital blepharoptosis patients seen at our western regional institute of ophthalmology during the given study period.

## 3. Materials and Methods

The study was carried out at our western regional institute of ophthalmology. The study was a prospective interventional study in an institutional cohort. The study period was one year from August 2018 to August 2019. Ethical clearance was taken from the institutional review board.

Thirty five consecutive patients of congenital blepharoptosis seen at our western regional institute of ophthalmology were enrolled for the study. A thorough history was taken either from the parents in case of children or at times from the patient herself in case of adults presenting with congenital ptosis. The history included prenatal history, type of delivery, milestones, any other systemic complaints. A history of eye winking while the child was feeding was elicited to rule out Marcus gunn jaw winking synkinesis. A family history of similar complaints was taken as in blepharophimosis syndrome the condition runs in families.

A thorough examination of blepharoptosis was done in all patients. This included margin reflex distance in both eyes, levator function in both eyes, bell's phenomenon, margin crease distance, extraocular movements. Phenylephrine test with 2.5% phenylephrine was done in cases of mild ptosis.

Marcus gunn jaw winking synkinesis was documented by observing the lids while asking the patient to move the jaws from side to side and also opening the mouth. A positive test was reported if winking of the eyelid was documented during the said procedure.

Tests to rule out myasthenia gravis were carried out. This included ice pack test, cogan's twitch sign and fatigue sign.

A detailed anterior and posterior segment evaluation was carried out. A dilated retinoscopy and best corrected visual acuity were documented.

The diagnostic condition leading to blepharoptosis was established.

The cases were segregated into surgical and non surgical arms. A decision on surgery was taken depending on risk of occlusion amblyopia or deferred to preschool years for children presenting early. In case of young adults presenting with blepharoptosis the surgical decision was taken as per protocol.

Informed consent was taken before the surgery. The sequelae of lid lag and lagophthalmos were explained to the parents/ patient. An awareness of nonforseeable complications was created. General anesthesia was used in the paediatric age group from zero to sixteen years. Thereafter the surgery was done under regional / local anesthesia for ages seventeen and above.

The Beard classification was used for arriving at the surgical protocol. The surgery for myogenic congenital blephroptosis included frontalis sling surgery using silicone sling for cases of severe ptosis with poor levator function. In cases of any moderate to severe ptosis with good to fair levator function levator resection surgery by the anterior approach was done. Conjunctivo mullerectomy was reserved for patients with mild ptosis with good levator function.

Patients with Marcus gunn jaw winking phenomenon were treated with levator extirpation with frontalis sling surgery using the silicone sling. Blepharophimosis was treated with fro talis sling surgery with epicanthus correction.

The patients were followed for one day, ten days, four weeks and six weeks.

Levator aponeurosis reattachment/ repair was done in cases of aponeurotic ptosis.

Myaesthesia gravis was treated by anticholinesterases.

Traumatic and mechanical cases of congenital blepharoptosis were not included in our study.

#### 4. Results

Thirty five consecutive patients of congenital blepharoptosis were documented. Tables one to four show the documented data.

Table 1 shows the types of congenital blepharoptosis seen. Myogenic ptosis due to a dystrophic levator muscle included 23 cases (65.71%) followed by Marcus gunn jaw winking synkinesis in six (17.14%) cases. Congenital myasthenia was documented in three (8.51%) cases. Third nerve palsy was seen in two (5.71%) cases and blepharophimosis syndrome in one case (2.86%).

Table 2 shows the patient demographics. Four children (11.42%) were three years of age. Seven children (20%) were more than three years up to five years of age. Fourteen cases (40%) presented between ages more than five years to sixteen years. Nine cases were seen between the ages more than sixteen years upto twenty five years (25.72%). Only one case of primarily congenital ptosis presented very late at forty five years of age (2.86%).

Twenty male patients (57.14%) and fifteen female cases (42.86%) were documented. Only right eye was involved in seventeen eyes (48.58%). Only left eye was involved in nine cases (25.71%). A same number of nine patients had a bilateral presentation.

Table 3 shows the clinical presentation of congenital blepharoptosis. Severe blepharoptosis with poor levator function was seen in thirty two cases (91.43%). Moderate ptosis with fair levator function was seen in two cases (6.71%). Mild ptosis with good levator function was documented in one case (2.86%).

Bells phenomenon was good in thirty one cases (88.57%), fair in three (8.51%) and poor in one case (2.86%). Ocular movements were full in twenty five cases (71.43%), double elevator palsy was seen in seven (20%) cases, third nerve palsy in two (5.71%) cases. One patient with congenital myasthenia had paresis of the extraocular muscles.

Marcus gunn jaw winking synkinesis was seen in six (17.14%) cases and blepharophimosis in one case (2.86%).

Amblyopia due to significant refractive error was seen in five cases (14.29%), strabismus in three cases (8.57%) and amblyopia due to occlusion of the visual axis was seen in one patient (2.86%).

Table 4 shows the management of congenital blepharoptosis. Frontalis sling was the most common procedure done at twenty cases (57.14%). This was followed by levator extirpation with sling surgery in six cases (17.14%) of Marcus gunn jaw winking synkinesis. Frontalis sling surgery with epicanthus correction was carried out in one case of blepharophimosis syndrome. Levator resection by the anterior approach was done in two cases (5.71%) and conjunctival mullerectomy in one case (2.86%).

Additional strabismus surgery was carried out in five cases of double elevator palsy including an inferior rectus recession.

The three cases of congenital myasthenia (8.57%) were managed by a medical reference and starting oral anticholinesterases (pyridostigmine as per dose).

Two cases of third nerve palsy (5.71%) were subjected to a neurological reference for thorough neurological workup and further management on their side.

Table 5 shows the outcome of the various surgical procedures performed for blepharoptosis. The outcome was classified as good, fair and poor as per Brincat B and Wilshaw H, UK study.<sup>2</sup> A good outcome was defined as single operation, good cosmesis, no complications with both surgeon and parents satisfied with the results. A fair outcome was defined as single operation but fair cosmesis, +/- complications, either surgeon or parents dissatisfied with the result. A poor outcome was defined as more than one operation with poor cosmesis, complications occurred, both parents and surgeon dissatisfied with the results.<sup>2</sup>

Fifteen out of twenty cases of frontalis sling surgery had a good outcome. Two cases had a fair result and three cases with poor outcomes had to be subjected to a repeat sling. The one case of conjunctivo-mullerectomy showed good results. One case of levator resection surgery showed good results while the second case with poor outcome had to be reoperated with a frontalis sling surgical procedure.

Five cases of levator extirpation with sling surgery for Marcus gunn synkinesis showed good results with a fair result in a single case. The one case of blepharophimosis syndrome could be operated with good results.

Table 6 shows the complications of blepharoptosis surgery. Thirty cases were operated by various procedures for the correction of blepharoptosis. The most common complication documented was nocturnal lagophthalmos seen in five cases (16.67%). Undercorrection of the ptosis requiring re-surgery was seen in four (13.33%) of cases. Other occasional complications included a single case of stitch granuloma and a single case of eyelid contour abnormality which was within cosmetically acceptable limits.

Figures 1, 2 and 3 are a graphical representation of the types of blepharoptosis seen, age of presentation of the patients and the causes of amblyopia in blepharoptosis patients respectively.

Figures 4, 5, 6, 7, 8, 9, 10, 11, 12, 13 and 14 showcase some of the congenital blepharoptosis patients seen in our oculoplastics and ocular oncology clinics.

#### 5. Discussion

Our study is a demographic and clinical study of congenital blepharoptosis patients seen in an institutional cohort in western India.

**Table 1:** Types of congenital blepharoptosis seen

Type of Ptosis	Number (percentage)
Myogenic (Dystrophic levator )	23 (65.71)
Blepharophimosis syndrome	1 (2.86)
Marcus Gunn Jaw Winking Synkinesis	6 (17.14)
Congenital Third nerve palsy	2( 5.71)
Childhood myasthenia	3 (8.57)

**Table 2:** Patient demographics

Age	Number (Percentage)
< 3 years	4 (11.42)
>3 years to </=5years	7 (20)
>5 years to</=16 years	14 (40)
>16 years to </=25years	9 (25.72)
>25years	1 (2.86)
Gender	
Male	20 (57.14)
Female	15 (42.86)
Laterality	
OD only	17 (48.58)
OS only	9 (25.71)
Bilateral	9 (25.71)

**Table 3:** Clinical presentation of congenital blepharoptosis

Clinical presentation	Number (percentage)
Blepharoptosis Mild Moderate Severe	1 (2.86 ) 2 ( 5.71) 32 ( 91.43)
Levator function Good Fair Poor	1 (2.86) 2 ( 5.71) 32 (91.43)
Bell's phenomenon Good Fair Poor	31 (88.57) 3 ( 8.57) 1 (2.86)
Ocular movements Full Double Elevator palsy Third nerve palsy Other extraocular muscle paresis	25 ( 71.43) 7 (20) 2 ( 5.71) 1 (2.86)
Marcus gunn jaw winking synkinesis	6 (17.14)
Myaesthesia	3 (8.57)
Blepharophimosis	1(2.86)
Amblyopia Significant Refractive Error Strabismus Occlusion	5 ( 14.29) 3 (8.57) 1 (2.86)

**Table 4:** Management of bongenital blepharoptosis

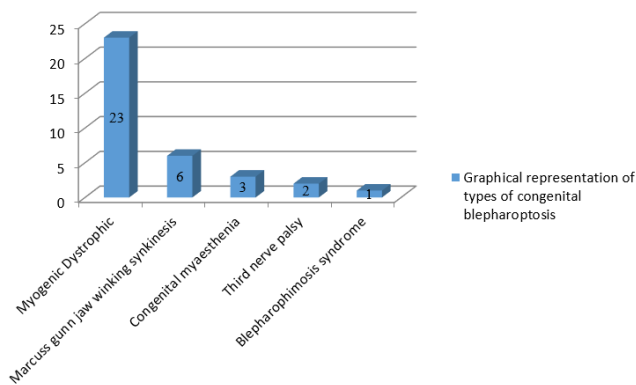
Management	Number (percentage)
Conjunctivo-mullerectomy	1 ( 2.86)
Levator resection	2 (5.71)
Frontalis Sling	20 ( 57.14)
Levator extirpation with frontalis sling	6 ( 17.14)
Frontalis sling with epicanthus correction	1 (2.86)
Additional Strabismus correction	5 ( 14.29)
Anticholinesterases with medical reference	3 (8.57)
Observation with neurological reference	2(5.71)

**Table 5:** Outcome of surgical management of congenital blepharoptosis

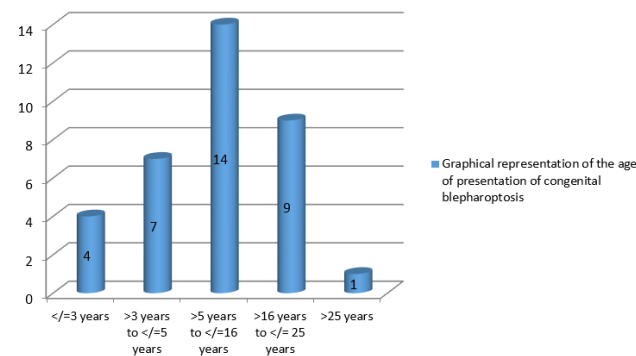
Management Procedure(Total number of Cases)	Outcome Good Fair Poor
Conjunctivo-mullerectomy(1)	1 - -
Levator resection(2)	1 - 1
Frontalis Sling(20)	15 2 3
Levator extirpation with frontalis sling(6)	5 1 -
Frontalis sling with epicanthus correction(1)	1 - -

**Table 6:** Complications of blepharoptosis surgery

Complication	Number (percentage)
Nocturnal Lagophthalmos	5 (16.67)
Undercorrection	4 (13.33)
Overcorrection	-
Stitch granuloma	1 (3.33)
Exposure of sling	-
Superficial punctate corneal erosions	-
Infection	-
Eyelid contour abnormality	1 (3.33)



**Fig. 1:** Graphical representation of types of congenital blepharoptosis seen

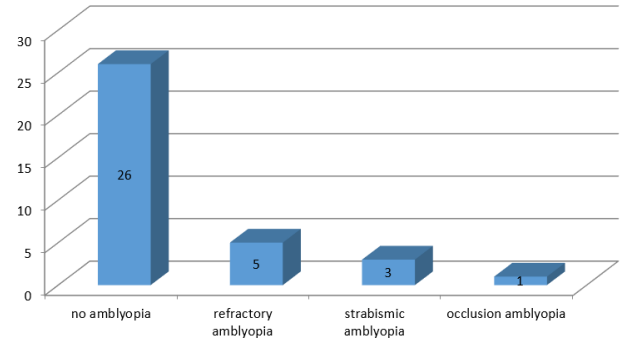


**Fig. 2:** Graphical representation of the age of presentation of congenital blepharoptosis

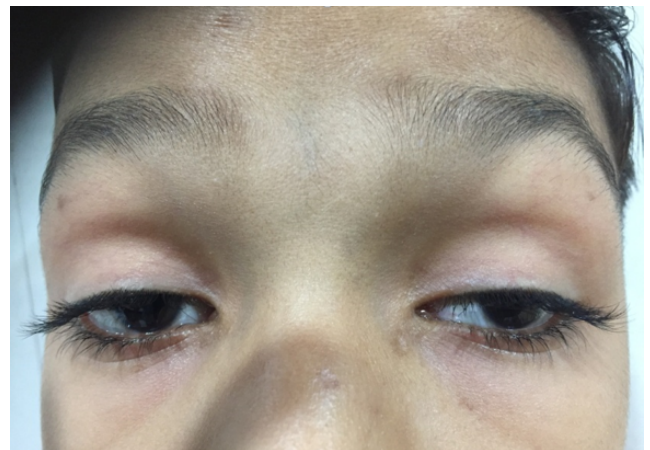We came across three large studies of congenital blepharoptosis one from the United Kingdom, one from the United States and another one from Cairo(Egypt).<sup>2-4</sup>

The findings of these studies are similar to the results of our study as presented above.

Brincat B et al (United Kingdom study) reported paediatric blepharoptosis in 186 eyes of 155 children. 124 had myogenic ptosis, 22 neurogenic and 8 mechanical blepharoptosis. Left eye was involved in 45.81% of cases and 20% patients had a bilateral involvement. The age range



**Fig. 3:** Causes of amblyopia in blepharoptosis patients

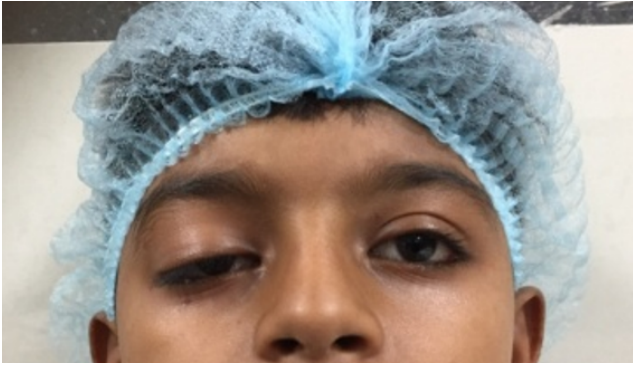

**Fig. 4:** A child with marcus gunn jaw winking phenomenon

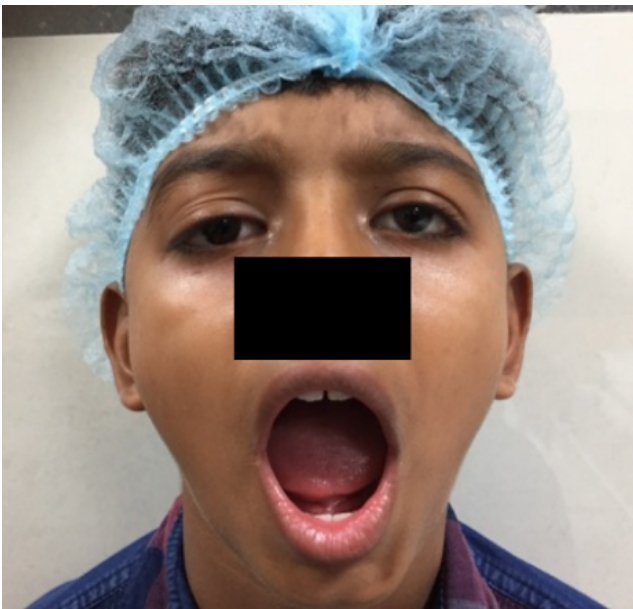was from birth to 186 months.<sup>2</sup>

Griepentrog et al (United States study) reported congenital levator dystrophy in 75,7% of cases, Marcus gunn jaw winking synkinesis in 3.8%, blepharophimosis in 2.8%, congenital third nerve palsy in 2.8% and childhood myaethenia gravis in 1.9%. They also reported a predominance of cases involving the left eye.<sup>3</sup>

Essawy RE, Elsada MA (Cairo, Egypt study) reported 408 eyes of 336 children with blepharoptosis. Mean age at presentation was 3.2 years (range 0.25 to 10 years). Blepharoptosis was unilateral in 64.7% of cases, 74% of



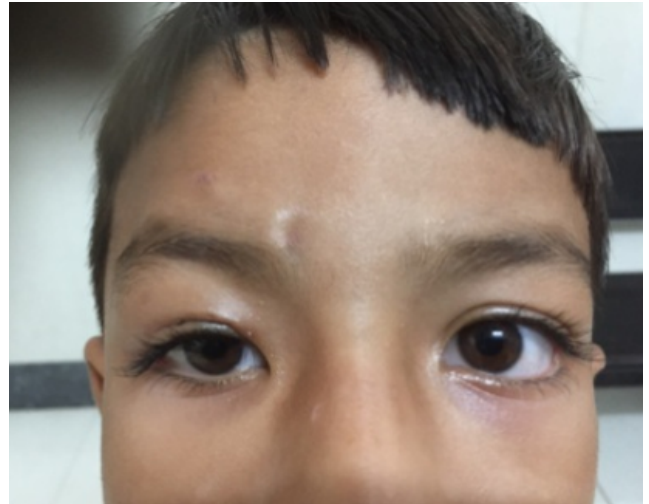**Fig. 5:** A child with marcus gunn jaw winking phenomenon. Note the lifting of the eyelid with jaw opening



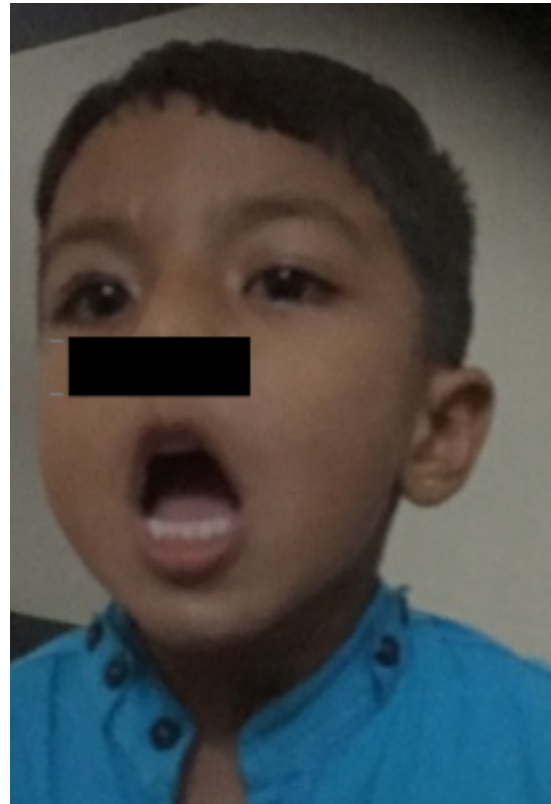**Fig. 6:** A child with marcus gunn jaw winking phenomenon. Note the lifting of the eyelid with jaw opening

which affected the left eye. As per the etiology it was congenital dystrophic in 68.9% of cases. Blepharophimosis was seen in 16.7% of cases, Marcus Gunn jaw winking phenomenon in 7.1%, third nerve palsy in 2.9% of cases, double elevator palsy in 2.5% and childhood myasthenia in 1.2% of the study group. The distribution of the surgical procedures was 58% cases of frontalis sling surgery, 295 cases of levator muscle resection and 13% cases of Whitnall sling surgery were documented. Amblyopia was reported in a considerable number due to associated refractive error (13.2%), strabismus (6.8%) and occlusion amblyopia (10%).<sup>4</sup>

We report a predominant involvement of the right eye unilaterally (48.58%) as compared to the left eye unilaterally (25.71%). This finding is in sharp contrast to that reported from the above studies. More studies would be

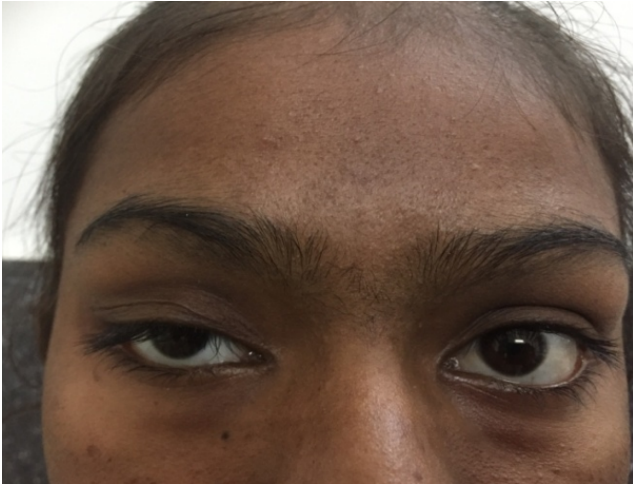

**Fig. 7:** Same child after corrective surgery

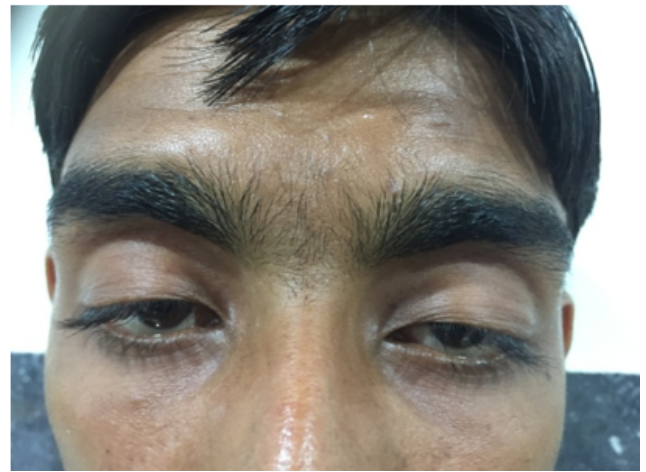

**Fig. 8:** Note the correction of the jaw wink on mouth opening

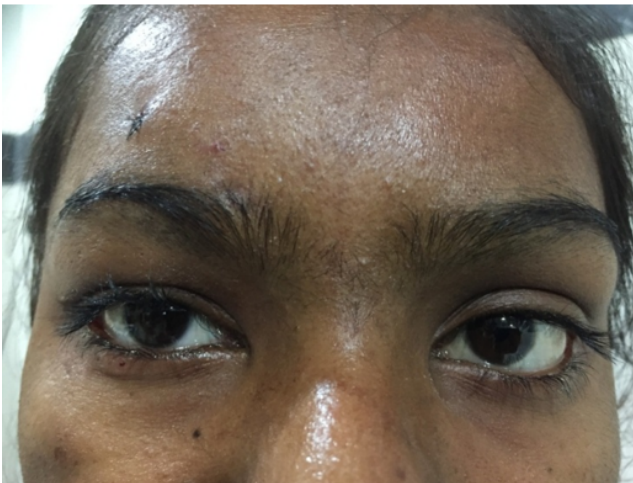



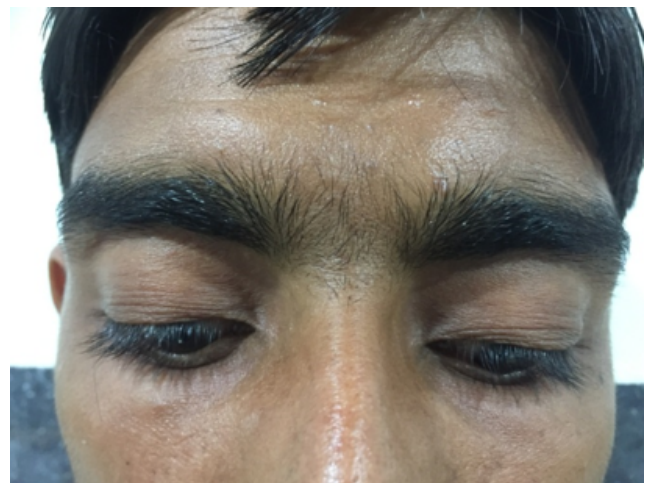**Fig. 9:** A seventeen year old girl with congenital bilateral ptosis (OD)



**Fig. 12:** Bilateral severe congenital ptosis in an adult male



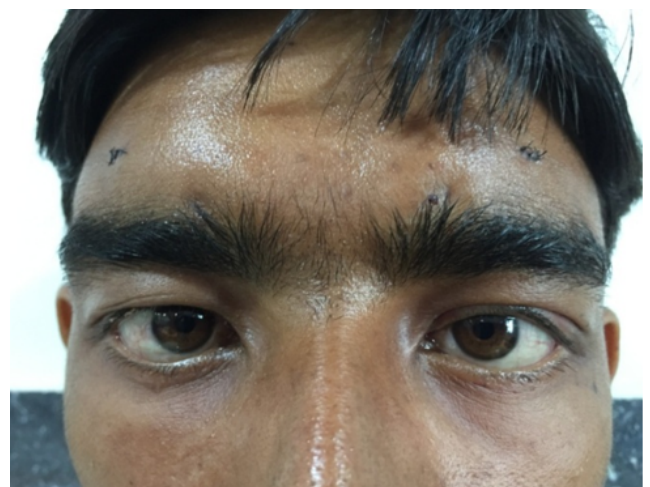**Fig. 10:** Same patient after correction of ptosis. Note the symmetrical palpebral fissures



**Fig. 13:** Lid lag on downgaze: sign characteristic of congenital ptosis



**Fig. 11:** Blepharophimosis syndrome in father and son



**Fig. 14:** Ptosis corrected after bilateral frontalis sling surgery

required to determine the exact cause of this predominance.

We also noted a higher incidence of congenital myasthenia gravis in our patients as compared to the above studies.

Wong VA reported on 28 patients with myogenic ptosis. They recommended the use of silicone slings in patients with severe ptosis and levator function less than 8 mm.<sup>5</sup>

Whitehouse GM et al reported amblyopia in 13.8% of cases and documented frontalis sling surgery as a useful procedure in severe ptosis with poor levator function.<sup>6</sup>

The other studies cited in the references also showcase congenital /paediatric blepharoptosis patients seen across the globe over the years.<sup>7–10</sup>

The last five studies cited highlight amblyopia an strabismus in congenital blepharoptosis patients.<sup>11–15</sup> The results presented are similar to those seen in our study.

## 6. Conclusion

The study highlights the demographics, clinical profile and management of congenital blepharoptosis patients seen at a centre of excellence in western India.

We report a predominant involvement of the right eye unilaterally (48.58%) as compared to the left eye unilaterally (25.71%). This finding is in sharp contrast to that reported from other studies. More studies would be required to determine the exact cause of this predominance.

We also noted a higher incidence of congenital myasthenia gravis in our patients as compared to other studies.

This enigmatic clinical entity is presented from our unique perspective. The study adds to and complements the world literature on the subject.

## 7. Acknowledgement

I acknowledge the immense support of the Director, Head of department Ocular Oncology and Oculoplastics, the staff and patients of M&J western regional Institute of Ophthalmology. I also acknowledge the immense help received from the scholars whose articles are cited and included in references of this manuscript. I am grateful to authors/editors/publishers of all those articles, journals and books from where the literature for this article has been reviewed and discussed.

## 8. Ethical clearance

Taken

## 9. Informed consent

Taken

## 10. Source of funding

None

## 11. Conflict of interest

None

## References

1. Tyers AG, Collins JRO. Ptosis in Colour Atlas of Ophthalmic Plastic Surgery Butterworth Heinemann. 2nd ed ; 2001,.
2. Brincat B, Willshaw H. Paediatric Blepharoptosis: A 10 year review. *Eye*. 2009;23:1554–1559.
3. Griepentrog GJ, Diehl NN, Mohny BG. Incidence and demographics of childhood ptosis. *Ophthalmol*. 2011;118:1180–1183.
4. Essawy RE, Elsada MA. Clinical and demographic characteristics of ptosis in children: a national tertiary hospital study. *Eur J Ophthalmol*. 2013;23(3):356–360.
5. Wong VA, Beckingsale PS, Oley CA, Sullivan TJ. Management of myogenic ptosis. *Ophthalmol*. 2002;109:1023–1031.
6. Whitehouse GM, Grigg JR, Martin FJ. Congenital ptosis :results of surgical management. *Aust NZ J Ophthalmol*. 1995;23:309–314.
7. Kemp EG, James CR, Collin JR. Brow suspension in the management of ptosis: an analysis of over 100 cases. *Trans Ophthalmol Soc UK*. 1986;105:84–87.
8. Ahmadi AJ, Sires BS. Ptosis in infants and children. *Int Ophthalmol Clin*. 2002;42:15–29.
9. McMullan TF, Robinson DO, Tyers AG. Towards an understanding of congenital ptosis. *Orbit*. 2006;25:179–184.
10. Bowyer JD, Sullivan TJ. Management of Marcus gunn jaw winking synkinesis. *Ophthal Plast Reconstr Surg*. 2004;20:92–98.
11. Dray JP, Leibovitch L. Congenital ptosis and amblyopia: a retrospective study of 130 cases. *J Paedr Ophthalmol*. 2002;39(4):222–225.
12. Anderson L, Baumgartner SA. Amblyopia in Ptosis. *Arch Ophthalmol*. 1980;98:1068–1069.
13. Anderson L, Baumgartner SA. Strabismus in Ptosis. *Arch Ophthalmol*. 1980;98:1062–1067.
14. Beneish R, Williams F, Polomeno RC, Little JM, Ramsey B. Unilateral congenital ptosis and amblyopia. *Can J Ophthalmol*. 1983;18:127–130.
15. Hornbliss A, Kass ZG, Zuffer AJ. Amblyopia in congenital ptosis. *Ophthalmic Surg*. 1995;26:334–337.

## Author biography

**Garima Agrawal** Associate Professor in Ophthalmology

**Cite this article:** Agrawal G. Demography, clinical presentation and management of congenital blepharoptosis: A prospective interventional cohort study at a regional institute of ophthalmology in western India. *Int J Ocul Oncol Oculoplasty* 2019;5(4):186-193.