



Original Research Article

Demography, clinical presentation and management of thyroid orbitopathy: A prospective interventional cohort study at a regional institute of ophthalmology in Western India

Garima Agrawal^{1,*}¹Dept. of Oculoplastics and Ocular Oncology, M & J Western Region Institute of Ophthalmology, Ahmedabad, Gujarat, India

ARTICLE INFO

Article history:

Received 20-11-2019

Accepted 29-11-2019

Available online 26-12-2019

Keywords:

Thyroid Orbitopathy
Demographics
Clinical presentation
Management
Western India

ABSTRACT

Introduction: Thyroid orbitopathy or Graves' orbitopathy has been known since almost two centuries with the ocular changes associated with thyroid disease being first published by Graves in 1835. Thyroid orbitopathy is an autoimmune disorder. It is a life-long disease with systemic and ocular manifestations. Early diagnosis and appropriate management of this disorder are essential. The European group on graves orbitopathy has put forward new updated guidelines for the management of this disorder. We designed a study to document the demographics, clinical presentation and management of Thyroid orbitopathy patients at our institute as per the new guidelines.

Aim: The current study aims to showcase the demography, clinical presentation and management of thyroid orbitopathy at a centre of excellence in western India.

Materials and Methods: The study design was a prospective interventional study in an institutional cohort. The study was carried out over a period two years from August 2017 to October 2019. Thirty five consecutive cases of Thyroid orbitopathy presenting to the oculoplastics and ocular oncology clinic of our western regional institute of ophthalmology were studied. They were subjected to a thorough history taking, clinical examination. The thyroid ophthalmopathy was classified as mild, moderate to severe, sight threatening. Active or inactive orbitopathy was documented. The patients were managed as per the recent updated globally accepted guidelines for the management of thyroid orbitopathy.

Observation and Results: Thyroid associated ophthalmopathy was found in all age groups. The age range was twelve years to seventy years. The maximum incidence was in the age group of thirty five to fifty five years (68.57%). It was more common in females (female: male ratio was 4:3). The most common clinical presentation was eyelid retraction(91.43%) followed by exophthalmos (77.14%). The patients had the whole spectra of the ophthalmopathy from mild (65.72%), moderate-to-severe (25.71%) to sight threatening ophthalmopathy (8.57%) though the latter cases were few. The disease activity was both active (31.43%) and quiescent (68.57%) with the latter dominating the scenario. The patients had the risk factors of active and passive smoke (45.71%) as well as thyroid dysfunction (97.14%). The patients were successfully managed as per the recent proposed updated guidelines of management of the disorder both medically as well as surgically.

Conclusion: The study adds the demographic and clinical profile of thyroid orbitopathy patients seen at a centre of excellence, tertiary care centre in western India. The disease has been studied from our unique perspective and managed as per the globally accepted current guidelines.

© 2019 Published by Innovative Publication. This is an open access article under the CC BY-NC-ND license (<https://creativecommons.org/licenses/by/4.0/>)

1. Introduction

Thyroid orbitopathy or Graves' orbitopathy has been known since almost two centuries with the ocular changes associated with thyroid disease being first published by

Graves in 1835.¹

It is the most common cause of unilateral or bilateral proptosis in adults. Graves orbitopathy usually occurs in association with hyperthyroidism however in a few cases normal thyroid function or even hypothyroidism/

autoimmune thyroiditis may be seen in some patients with typical features of Graves orbitopathy.¹

Thyroid associated Orbitopathy (Graves orbitopathy) can be an extremely disabling disease with effects on visual function and psychosocial wellbeing of the patient. The disease involves both humoral and cellular components of the immune mechanism with the extraocular muscles and orbital fat(connective tissue) being the target structures.¹ It presents clinically as lid retraction, exophthalmos, extraocular muscle involvement, optic neuropathy and inflammation.¹

These patients require timely diagnosis, careful evaluation and lifelong care. Management includes documenting and treating thyroid dysfunction. Thyroid ophthalmopathy is managed via supportive treatment, immunosuppression and surgery.¹

The 2016 European Thyroid Association /European Group on Grave's Orbitopathy (EUGOGO) recently put forward guidelines for the management of Graves Orbitopathy.² A patient focused approach to the disease has been put forward encompassing the effect of the disease on the quality of life and psychosocial well being of the patient.

They recommended a thorough assessment of the activity and severity of Graves orbitopathy and its effect on the quality of life of the patient. Control of thyroid dysfunction, stopping smoking and supportive measures as lubricants, dark glasses were recommended for all patients. Mild disease could be subjected to masterly observation. A new recommendation is the use of antioxidant selenium as a six month course as it has been seen to improve the mild manifestations of the disease and prevent its progression to more severe forms.²

Moderate-severe and active graves orbitopathy is recommended treatment with intravenous glucocorticoids as the first line of management.³⁻⁵ Oral route for glucocorticoids has been used for long though steroid side effects have been a cause of concern. The recent studies suggest that glucocorticoids by the intravenous route have less side effects as compared to oral steroids and at the same time are more efficacious.³⁻⁵ Hence the recent recommendations.^{6,7}

The second line of management would be another course of the same or oral glucocorticoids alone or in combination with radiotherapy or cyclosporine, rituximab as per analysis, team decision and individualization. Rehabilitative surgery would be reserved for patients managed conservatively and where the disease has been rendered inactive by immunosuppressive agents.²

In the light of the newer and emerging changing scenario in the management of Thyroid orbitopathy (Graves orbitopathy), we designed a study to document the demography, clinical presentation including activity and severity along with the management of Thyroid orbitopathy as per the new guidelines at our regional institute of ophthalmology in western India.

2. Aim

The study aims at documenting the demography, clinical presentation including activity and severity along with the management of Thyroid Orbitopathy as per the new guidelines at our regional institute of ophthalmology in western India.

3. Materials and Methods

The study design was a prospective interventional study in an institutional cohort. Ethical clearance was taken from the institutional ethics committee. The study was carried out over a period two years from August 2017 to October 2019. Thirty five consecutive cases (direct and referral) of Thyroid Orbitopathy seen at the oculoplastics and ocular oncology clinic of our western regional institute of ophthalmology were studied. Informed consent was taken from all the patients for study enrolment.

History of the onset, duration and course of the ophthalmic symptoms was elicited as pain, grittiness, diminution of vision. History of the thyroid dysfunction and treatments taken (if any) was documented. A personal history of smoking, diabetes, hypertension, family history of graves orbitopathy and any other systemic or ocular disease were elicited.

Clinical examination included best corrected visual acuity, slit lamp examination, fundus examination, intraocular pressure recording. Ocular movements and evaluation for presence of strabismus was done. Force duction test was used to diagnose restrictive myopathy. A positive test was seen in restrictive strabismus due to thyroid myopathy. Colour vision, visual field charting, afferent pupillary defect and swelling or pallor of the optic nerve head on fundoscopy were used as an adjunct to diagnose dysthyroid optic neuropathy.

Exophthalmometry readings were obtained using a Hertel's exophthalmometer.

A GO-QOL (Grave's Orbitopathy – quality of life) questionnaire as put forth by the EUGOGO was used to assess the quality of life of the patients. The GO-QOL questionnaire has two subscales visual functioning and appearance. Each subscale contains eight items. Each item is scored as 3-severely limited/affected, 2-a little, 1-not at all.¹

The severity of the Graves orbitopathy (GO) was classified as mild, moderate-severe and sight threatening (very severe) as per the EUGOGO guidelines.² Mild disease was defined as patients whose features of GO have only a minor impact on daily life insufficient to justify immunosuppressives or surgery. They usually have one or more of the following: minor lid retraction (<2mm), mild soft tissue involvement, exophthalmos<3mm above normal for race, gender, no or intermittent diplopia and corneal exposure responsive to lubricants.²

Moderate-to-Severe GO was defined as patients without sight threatening GO whose eye disease has sufficient impact on daily life to justify the risks of immunosuppression (if active) or surgical intervention (if inactive). They usually have two or more of the following: lid retraction \geq 2mm, moderate or severe soft tissue involvement, or exophthalmos \geq 3mm above normal for race and gender, constant or inconstant diplopia.²

Sight threatening GO (very severe) was defined as patients with DON (dysthyroid optic neuropathy) and/or corneal breakdown.²

Clinical activity score was used to classify the disease as active or quiescent. The score has one point for each of seven manifestations that include: 1) Spontaneous retrobulbar pain 2) Pain on attempted upward or downward gaze 3) Eyelid redness 4) Conjunctival redness 5) Swelling of caruncle/plica 6) Swelling of eyelids 7) Swelling of conjunctiva (chemosis). A score of $<$ 3 would define the disease as inactive and a score of \geq 3 was used to signify active disease.²

Thyroid dysfunction was documented by serum free T3, serum free T4 and serum thyroid stimulating hormone assays. A fasting blood sugar was done to rule out associated diabetes mellitus.

Imaging studies included ultrasonography B scan and computerized tomography scan of the both orbits. Thyroid orbitopathy was documented as an extraocular muscle thickening (sparing the tendons). Computed tomographic scan additionally documents exophthalmos, increased orbital soft / connective, crowding of orbital apex. The latter is an additional tell tale sign of dysthyroid optic neuropathy.

Thyroid dysfunction was treated as per protocol with anti thyroid agents, thyroidectomy and radiiodine.

All patients with thyroid orbitopathy were reassured and counselled regarding the nature of the disease. All patients were urged to stop smoking (both active and passive). Head elevation at night time and cold compresses were advised to reduce eyelid and orbital swelling. Ocular lubrication with non preserved lubricants was given for ocular surface dryness/ disorder. Dark glasses too helped in the latter condition. Antioxidant therapy with selenium (100 micrgram twice daily) was prescribed for six months.

Sight threatening optic neuropathy was treated with intravenous pulse glucocorticoid therapy as the first line of management. Very high doses of intravenous glucocorticoids were used. This included 0.5 to 1 gram of methylprednisolone on three consecutive days/alternate days for a week to be repeated the next week if needed. Orbital decompression surgery was done if there was no improvement in two weeks.

Sight threatening keratopathy was managed as per the protocol for treatment of keratopathy.

Patients with moderate to-severe and active ophthalmopathy were treated with intravenous steroids.

Intravenous steroids were given as a pulse therapy i.e. 6 weekly infusions of 0.5 grams methylprednisolone followed by 6 weekly infusions of 0.25 grams amounting to a cumulative dose of 4.5 gram of methylprednisolone. The cumulative intravenous dose was not allowed to exceed 8 grams.

The second line of treatment in patients with active Graves ophthalmopathy unresponsive to intravenous steroids or in those patients with intolerable side effects of iv steroids includes oral glucocorticoids alone or in combination with orbital radiotherapy in a dose of 20Gy per orbit in 10 fractions over 2 weeks. Cyclosporine in an initial dose of 5 mg/kg body weight per day combined with oral glucocorticoids in a starting dose of 100 mg per day followed by tapering for three months.

Rehabilitative or cosmetic surgery was done when the disease had been inactive for a minimum of six months. The order of the surgery was orbital surgical procedures followed by squint correction followed by eyelid surgery.

4. Observations and Results

Tables 1, 2, 3, 4, 5 and 6 document the observations of our study. The age range was twelve years to seventy years. The maximum incidence was seen in the age group of thirty five to fifty five years (68.57%). It was more common in females (female: male ratio was 4:3).

The most common clinical presentation was eyelid retraction (91.43%) followed by exophthalmos (77.14%). The patients had the whole spectra of the ophthalmopathy from mild (65.72%), moderate-to-severe (25.71%) to sight threatening ophthalmopathy (8.57%) though the latter cases were few. The disease activity was both active (31.43%) and quiescent (68.57%) with the latter dominating the scenario. The patients had the risk factors of active and passive smoke (45.71%) as well as thyroid dysfunction (97.14%). As many as 48.57% patients reported that thyroid orbitopathy affected their daily visual activities and/or were unhappy with their appearance.

The patients were successfully managed as per the recent proposed updated guidelines of management of the disorder both medically as well as surgically. Patient counselling, ocular lubrication, ocular protective glasses, refraining from smoking and control of thyroid dysfunction were the cornerstones of the management in all patients. Steroids were the most effective in suppressing the immune response of thyroid orbitopathy with intravenous glucocorticoids being used in almost a quarter of our patients (25.71%). This included three patients with dysthyroid optic neuropathy and six patients with moderate-to-severe and active disease with optimal results. In addition oral glucocorticoids were also given in eight patients as an alternative/ second line therapy.

Surgical procedures done included an urgent bilateral lateral orbital wall decompression in a patient with sight

threatening keratopathy and dysthyroid optic neuropathy with suboptimal response to intravenous glucocorticoid therapy after two weeks. Three patients in the quiescent stage underwent a corrective strabismus surgery. Lid lengthening was done in five patients with quiescent orbitopathy to improve appearance and conserve the ocular surface. This included muller muscle/ levator weakening with or without a spacer donor sclera graft.

Tables 1, 2, 3, 4, 5 and 6 representation of the age distribution, gender distribution, severity assessment and the common clinical manifestations of thyroid orbitopathy patients seen in our study.

Figures showcase some of the patients of thyroid orbitopathy seen at our institute during the course of the study.

Table 1: Patient demographics

Variable	Number(percentage)
Age(years)	
</=15	1 (2.86)
>15 to </=25	3 (8.57)
>25 to </=35	4 (11.42)
>35 to </=45	11 (31.42)
>45 to </=55	13 (37.14)
>55 to </=65	2(5.71)
>65	1 (2.86)
Gender	
Female	20(57.14)
Male	15 (42.86)

Table 2: Risk factors and quality of life of thyroid orbitopathy patients

Risk Factor	Number (percentage)
Smoking status	
Active Smokers	9 (25.71)
Passive Smokers (exposure to domestic smoke)	
Non smokers	19 (54.29)
Thyroid dysfunction	
Hyperthyroidism	32 (91.43)
Hypothyroidism	2 (5.71)
Euthyroid	1 (2.86)
Diabetes	9 (25.71)
Positive family history of Thyroid Orbitopathy	7 (20)
Hypertension	13 (37.14)
Quality of life	
Visual function and/or appearance	
Affected	17 (48.57)
Not affected	18 (51.43)

5. Discussion

The current study showcases the demography, clinical presentation and management of Thyroid orbitopathy

Table 3: Severity and activity of thyroid orbitopathy

Severity	Number(percentage)
Mild	23 (65.72)
Moderate-Severe	9 (25.71)
Sight threatening(Very Severe)	3 (8.57)
Activity	Number(percentage)
Active	11(31.43)
Quiescent	4 (68.57)

Table 4: Major clinical manifestations of thyroid orbitopathy

Clinical Manifestation	Number(percentage)
Eyelid Retraction	32 (91.43)
Exophthalmos	27 (77.14)
Soft tissue involvement	21 (60)
Extraocular Myopathy	11 (31.43)
Dysthyroid Optic Neuropathy	3 (8.57)

Table 5: Treatment of thyroid dysfunction

Treatment	Number(percentage)
Anti-thyroid drugs	32 (91.43)
Radioactive Iodine	1 (2.86)
Thyroidectomy	5 (14.29)
Thyroxine	2 (5.71)

Table 6: Treatment of thyroid orbitopathy.

Treatment	Number (percentage)
Supportive treatment	35 (100)
Selenium	35 (100)
Ocular Lubricants	35 (100)
Glucocorticoids	
Intravenous	9 (25.71)
Oral	8 (22.86)
Cyclosporine	1(2.86)
Orbital radiotherapy	1(2.86)
Surgery	
Orbital decompression	1(2.86)
Squint	3 (8.57)
Lid Surgery	5 (14.29)

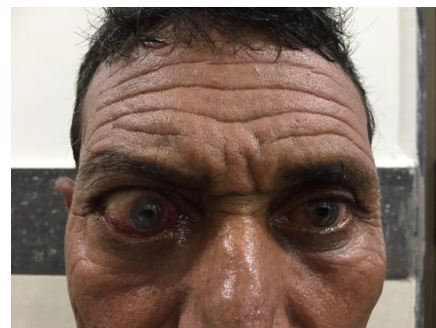

Fig. 1: : A 57 year old male ,smoker patient with asymmetrical dysthyroid ophthalmopathy: Note the exophthalmos, lid retraction and conjunctival congestion more pronounced in the right (OD) eye. Active, sight threatening Graves ophthalmopathy

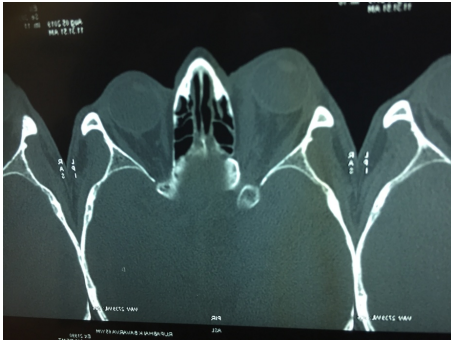

Fig. 2: Axial computed tomography scan of the same patient with Thyroid Orbitopathy: Note the right eye proptosis, extra ocularmuscle thickening with sparing of the tendons

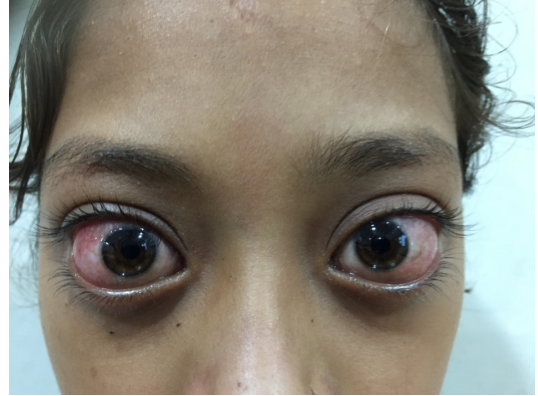

Fig. 5: A 12 year old girl with dysthyroid ophthalmopathy: Note the bilateral eyelid retraction (both upper and lower eyelids) and bulbar conjunctival congestion. The patient has mild and active disease.

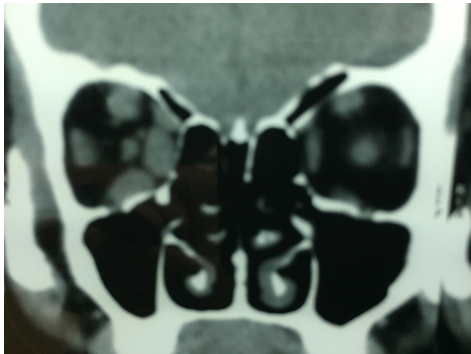


Fig. 3: Coronal view of computed tomography scan of the above patient with Thyroid Orbitopathy: Note the extraocular muscle thickening more pronounced in the right (OD) eye. Also note the more pronounced thickening of the inferior and medial rectus as compared to the superior and lateral rectus(OD)

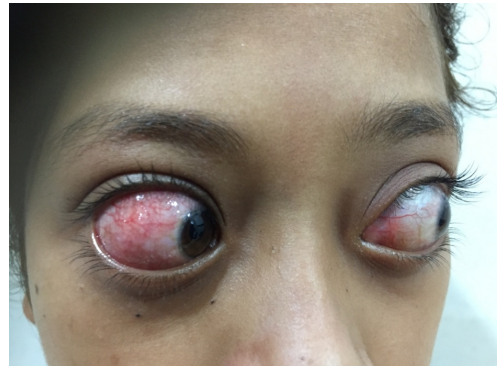


Fig. 6: The same patient with photograph in the left lateral gaze showing bulbar conjunctival congestion more pronounced at the insertion of the recti

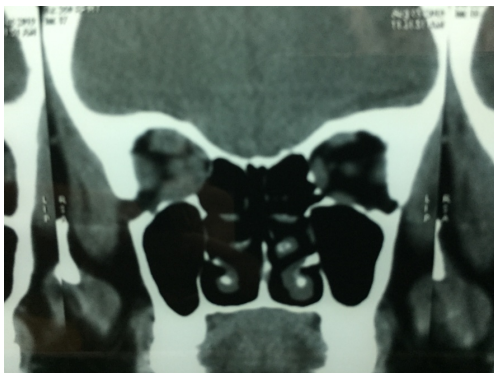

Fig. 4: Coronal computed tomography scan of the same patient at the orbital apex. Note the apical crowding in the right eye due to extraocular muscle thickening with fat plane obliteration. The patient had decreased vision in the right eye due to optic nerve compression.

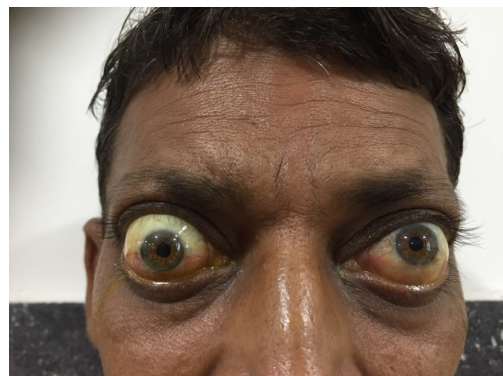

Fig. 7: A 45 year old male with Thyroid Orbitopathy: Note the bilateral eyelid retraction (both upper and lower eyelids), bilateral exophthalmos, mild conjunctival congestion and strabismus. The patient has moderate-to-severe, quiescent disease.

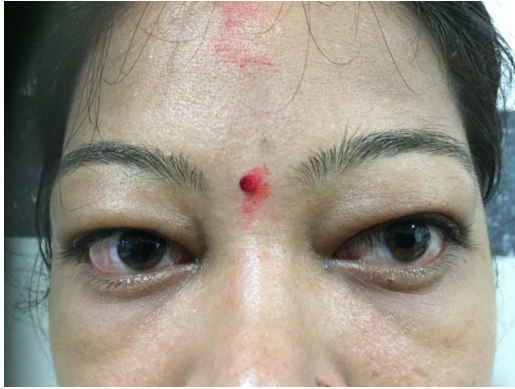

Fig. 8: A 38 year old lady with Thyroid Orbitopathy: Note the bilateral lid edema and conjunctival congestion: Mild and active thyroid ophthalmopathy

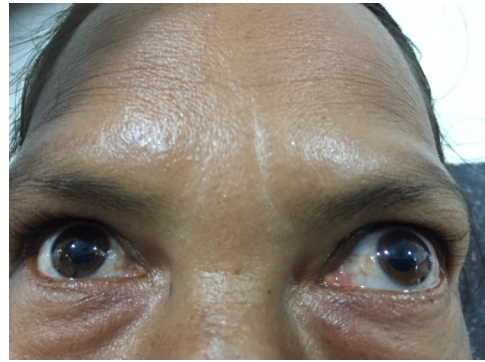


Fig. 11: The same patient showing restricted elevation due to the fibrous inferior rectus

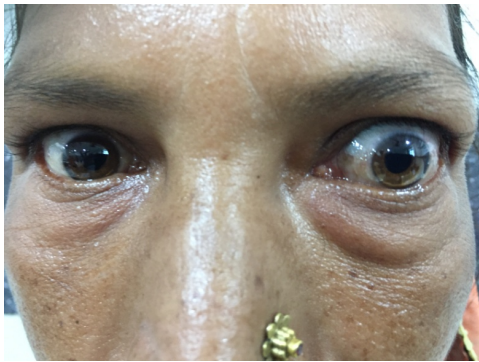


Fig. 9: A 63 year old lady with Thyroid Orbitopathy. Note the bilateral eyelid retraction, bilateral eyelid swelling, proptosis and strabismus more pronounced in the left (OS) eye. She had complaint of ocular pain. Moderate-to-severe active thyroid ophthalmopathy.

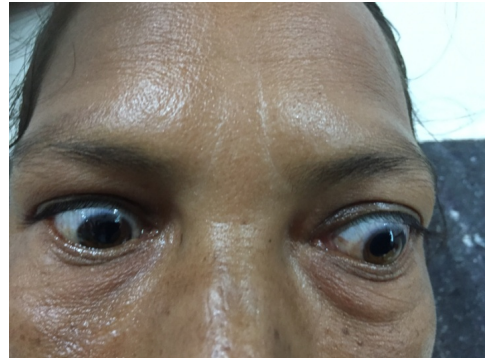


Fig. 12: The same patient showing restricted eye movements in levodepression due to fibrous superior rectus

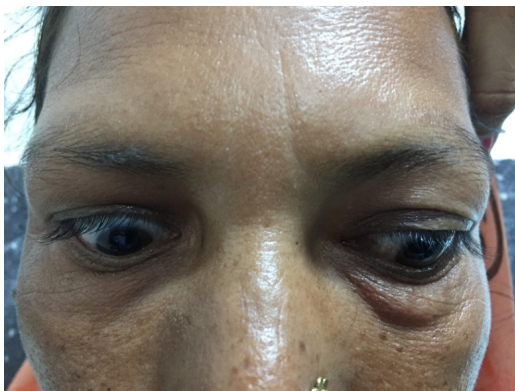


Fig. 10: The same patient with bilateral lid lag on downgaze. Lid retraction and lid lag are characteristic signs of Thyroid Orbitopathy

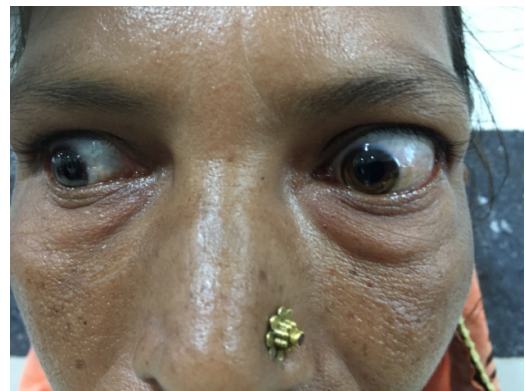

Fig. 13: The above patient with restricted eye movement on dextrodepression due to fibrous superior rectus

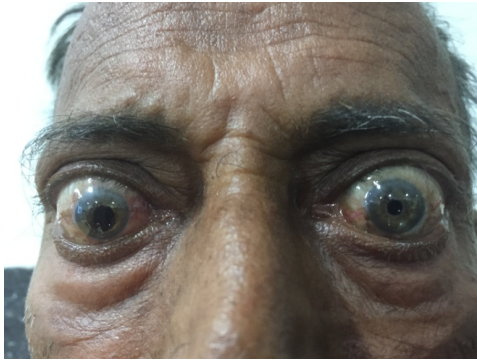


Fig. 14: A 70 year old male smoker with thyroid ophthalmopathy: Note the bilateral exophthalmos, bilateral eyelid retraction, lid swelling, conjunctival congestion, strabismus, relative afferent papillary defect in the right eye due to dysthyroid optic neuropathy: Moderate-to severe and active thyroid ophthalmopathy

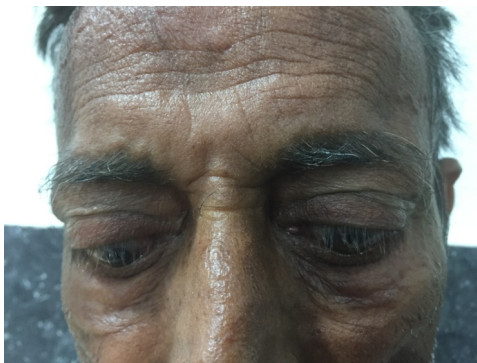

Fig. 15: The same patient showing lid lag on downgaze

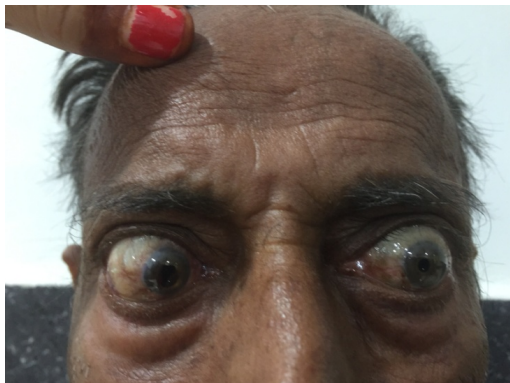

Fig. 16: Restrictive myopathy in the above patient with very few ocular movements preserved. The patient's head has been stabilized as the patient reflexly moves his head when asked to see in a particular direction due to restriction of ocular movements in that direction

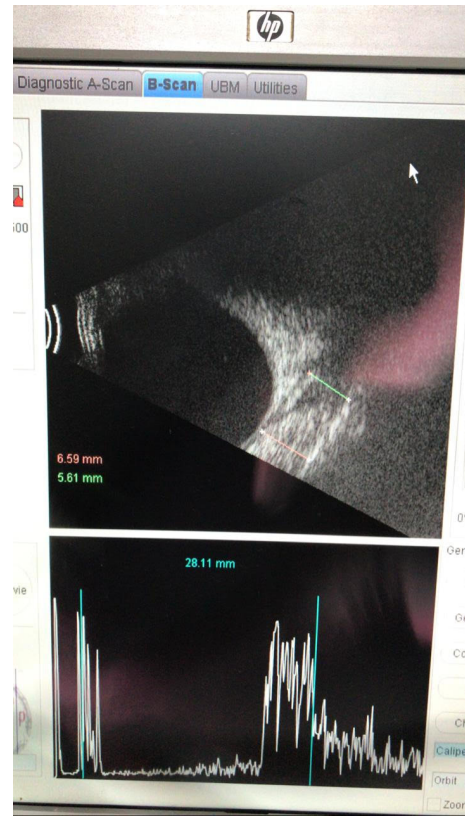


Fig. 17: Ultrasonography b scan of the above patient showing a markedly thick inferior rectus belly with tendon sparing

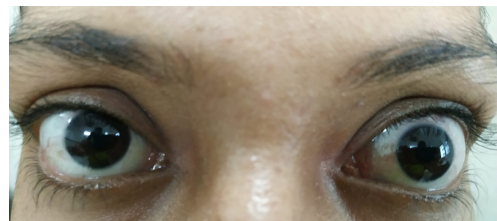

Fig. 18: A 25 year old girl with hyperthyroidism and thyroid ophthalmopathy: note the bilateral eyelid retraction with left eye mild exophthalmos: Mild, quiescent thyroid ophthalmopathy.

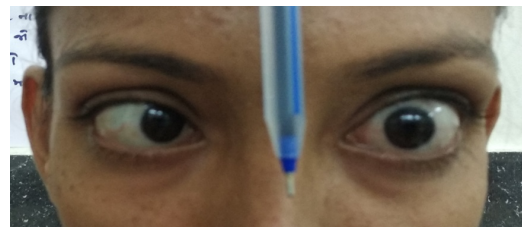

Fig. 19: The same girl with defective convergence

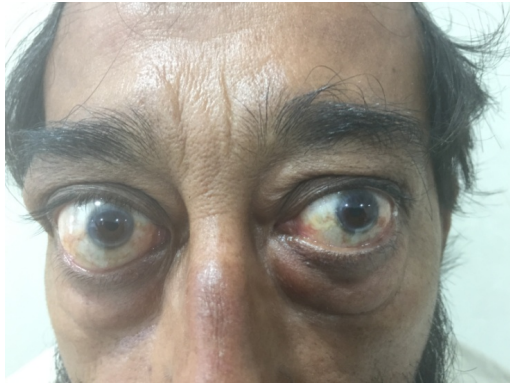

Fig. 20: A 57 year old male smoker with moderate-to-severe and active thyroid orbitopathy. Note the bilateral eyelid swelling, conjunctival redness, eyelid retraction, exophthalmos. The patients had spontaneous retrobulbar pain

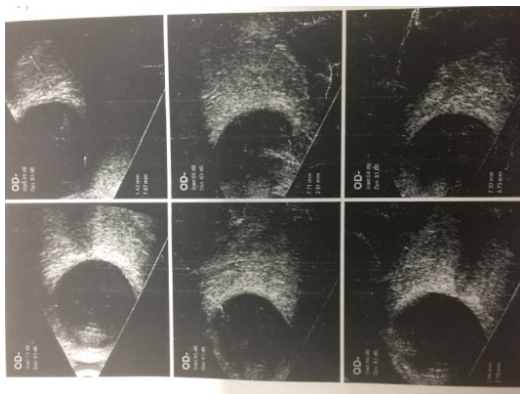


Fig. 21: Extraocular muscle thickening (OD) of the above patient on B scan ultrasonography

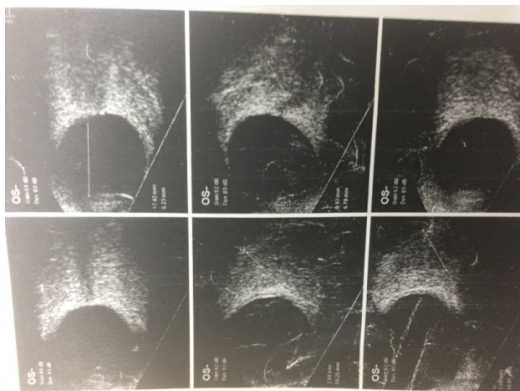


Fig. 22: Extraocular muscle thickening of the same patient on B scan ultrasonography(OS).

patients at a regional Institute of ophthalmology in western India.

Thyroid orbitopathy showed a wide age distribution. The age range was twelve years to seventy years. The maximum incidence was seen in the age group of thirty five to fifty five years (68.57 %). It was more common in females (female : male ratio was 4:3).

The most common clinical presentation was eyelid retraction (91.43%) followed by exophthalmos (77.14%). The patients had the whole spectra of the ophthalmopathy from mild (65.72%), moderate-to-severe(25.71%)to sight threatening ophthalmopathy (8.57%) though the latter cases were few. The disease activity was both active(31.43%) and quiescent (68.57%)with the latter dominating the scenario. The patients had the risk factors of active and passive smoke (45.71%) as well as thyroid dysfunction (97.14%).

The patients were successfully managed as per the recent proposed updated guidelines of management of the disorder both medically as well as surgically. The results as documented above are similar to recent studies conducted across the globe some of which are noted below.

Reddy SVB et al reported the prevalence of Grave's ophthalmopathy in patients with Graves disease.⁸ The study was done at a referral centre in North India. They diagnosed Graves ophthalmopathy in 65 out of 235 patients of Graves disease. Prevalence was similar in males (28%) and females(27%). Graves ophthalmopathy was mild in 83% of cases, moderate-severe in 15% and sight threatening in 2% of cases. The disease was clinically active in only two (3%) of cases. The presenting clinical features were eyelid retraction (83%), exophthalmos(75%), myopathy of the extraocular muscles(5%) and optic nerve dysfunction in 2% cases. The risk factors identified were smoking and raised thyrotropin receptor antibody level.⁸

Ackuaku-Dogbe EM, Akpalu J, Abaidoo B reported the epidemiology and clinical features of Thyroid-associated orbitopathy in Accra (Middle East Africa).⁹ They reported 194 patients with thyroid disorder. 117(60.3%) patients had Thyroid orbitopathy. Mean age of the patients was 45.22 years. The male:female ratio was 1:4. The most common symptoms were bulging eyes (65%) and puffy eyelids (33%). The most common signs were eyelid retraction (82.9%) and proptosis (68.38%). Mild Thyroid Orbitopathy was reported in 64.96% of cases and severe in 6.84% cases. The study concluded that the findings are similar to that in other parts of the world but the ophthalmic presentation was milder than in Caucasians.⁹

A previous study from our institute documented patients with thyroid orbitopathy.¹⁰ The study provided insights into the mammoth task of the management of this complex disorder in our part of the earth.

Other researchers from across the globe as Bartley GB, Jankauskeine J and Marcocci C have also documented the epidemiology, demography, clinical characteristics, treat-

ment of thyroid orbitopathy in their original studies.^{11–16} Their research complements the available literature of this grave thyroid orbitopathy. The studies have results similar to our study though subtle regional differences in demography and clinical presentations exist.

6. Conclusion

We present the demography, clinical manifestations and management of thirty five consecutive cases of thyroid orbitopathy seen at a regional institute of ophthalmology in western India. Our study complements the available world literature on thyroid orbitopathy and presents thyroid orbitopathy from the unique perspective of western India. Notwithstanding the diverse manifestations of the disease and its equally diverse treatment strategies, the study corroborates the current management strategies of this complex disorder.

7. Acknowledgement

I acknowledge the immense support of the Director, Head of department Ocular Oncology and Oculoplastics, the staff and patients of M&J western regional Institute of Ophthalmology. I also acknowledge the immense help received from the scholars whose articles are cited and included in references of this manuscript as well as the authors/editors/publishers of all those articles, journals and books from where the literature for this article has been reviewed and discussed.

8. Ethical clearance

Taken

9. Informed consent

Taken

10. Conflict of interest

None

11. Source of funding

None

References

1. Rootman J. Graves' Orbitopathy. In: and others, editor. Diseases of the Orbit. A Multidisciplinary Approach. 1st ed. J B Lippincott Company ; 1988., p. 241–280.
2. Bartalena L, Baldesci L. European Thyroid Association /European Group on Graves Orbitopathy Guidelines for the Management of Graves Orbitopathy. *Eur Thyroid J*. 2016;5:9–26.
3. Luigi TM, Laura. Graves Ophthalmopathy. *N Engl J Med*. 2009;360:994–1001.
4. Bartalena L, Baldeschi L, Dickinson A. Consensus statement of the European Group on Graves Orbitopathy (EUGOGO) on management of Graves orbitopathy. *Eur J Endocrinol*. 2008;158:273–285.
5. Bartalena L, Baldeschi L, Dickinson A. Consensus statement of the European Group on Graves Orbitopathy (EUGOGO) on management of Graves orbitopathy. *Thyroid*. 2008;18:333–346.
6. Garima A, Mehta DC. Current and Future trends in the Management of Thyroid Orbitopathy. *J Ind Med Ass*. 2016;114(4):24–27.
7. Garima A, Mehta DC. Current trends in the Management of Thyroid Orbitopathy. *Guj Med J*. 2012;7(2):72–76.
8. Reddy S, Jain A, Yadav SB. Prevalence of Graves ophthalmopathy in patients with Graves disease presenting to a referral centre in North India. *Indian J Med Res*. 2014;139:99–104.
9. Acquaku-Dogbe EM, Akpalu J, Abaidoo B. Epidemiology and Clinical Features of Thyroid-associated. *Orbitopathy in Accra Middle East Afr J Ophthalmol*. 2017;24(4):183–189.
10. Clinical Presentation and Management of 100 Consecutive cases of Thyroid Orbitopathy seen in the out patient department of a regional institute of ophthalmology. *Int J Cur Res Rev*. 2015;7(12):60–63. Agrawal Garima.
11. Bartley GB, Fatourehchi V, Kadrmas EF, Jacobsen SJ, Ilstrup DM, et al. Clinical features of Graves' ophthalmopathy in an incidence cohort. *Am J Ophthalmol*. 1996;121(3):284–290.
12. Bartley GB. The epidemiologic characteristics and clinical course of ophthalmopathy associated with autoimmune thyroid disease in Olmsted County. *Trans Am Ophthalmol Soc*. 1994;92:477–588.
13. Bartley GB, Fatourehchi V, Kadrmas EF, Jacobsen SJ, Ilstrup DM, et al. Chronology of Graves' ophthalmopathy in an incidence cohort. *Am J Ophthalmol*. 1996;121(4):426–434.
14. Jankauskiene J, Imbrasiene D. Investigations of ocular changes, extraocular muscle thickness, and eye movements in Graves' ophthalmopathy. *Jhn Medicina (Kaunas)*. 2006;42(11):900–903.
15. Bartley GB, Fatourehchi V, Kadrmas EF, Jacobsen SJ, Ilstrup DM, et al. The treatment of Graves' ophthalmopathy in an incidence cohort. *Am J Ophthalmol*. 1996;121(2):200–206.
16. Marocchi C, Bartalena L, Bogazzi F, Panicucci M, Pinchera A. Studies on the occurrence of ophthalmopathy in Graves' disease. *Acta Endocrinol (Copenh)*. 1989;120(4):473–475.

Author biography

Garima Agrawal Associate Professor in Ophthalmology

Cite this article: Agrawal G. Demography, clinical presentation and management of thyroid orbitopathy: A prospective interventional cohort study at a regional institute of ophthalmology in Western India. *Int J Ocul Oncol Oculoplasty* 2019;5(4):157-165.